



## Case Report

# A child of African origin with tinea capitis and multiple kerions

Rameshwari Thakur<sup>1</sup>, Avneet Singh Kalsi<sup>2,\*</sup>

<sup>1</sup>Dept. of Microbiology, Muzaffarnagar Medical College, Muzaffarnagar, Uttar Pradesh, India

<sup>2</sup>Dept. of Dermatology, Muzaffarnagar Medical College, Muzaffarnagar, Uttar Pradesh, India



### ARTICLE INFO

#### Article history:

Received 29-10-2019

Accepted 15-11-2019

Available online 20-12-2019

#### Keywords:

Tinea capitis

Kerions

*Trichophyton violaceum*.

### ABSTRACT

Dermatophytes are aerobic fungi which invade and infect the keratinized layers of skin, hair, and nails. The infection so caused is known as dermatophytosis, and it spreads by direct contact with other people (anthropophilic organisms), animals (zoophilic organisms), and soil (geophilic organisms), as well as indirectly from fomites. Tinea capitis is a fungal infection of the scalp along with eyebrows and eyelashes. Kerion is a severe inflammatory form of tinea capitis with delayed hypersensitivity reaction against dermatophytes. Here we report a case of a HIV positive, child of African origin with tinea capitis and multiple kerions.

© 2019 Published by Innovative Publication. This is an open access article under the CC BY-NC-ND license (<https://creativecommons.org/licenses/by/4.0/>)

## 1. Introduction

Dermatophytes are the filamentous fungi, though prevalent all over the world, but are more common in countries with hot and humid climate. The infection caused by them is also known as tinea or ringworm, as the infection spreads centrifugally. Dermatophytic infections are more common among people with diabetes, HIV/AIDS, leukemia or any other condition causing immunosuppression. People who chronically use topical or systemic corticosteroids are more likely to develop infection. According to the latest classification, dermatophytes are classified into seven genera, namely, *Trichophyton*, *Epidermophyton*, *Nannizzia*, *Paraphyton*, *Lophophyton*, *Microsporum*, *Arthroderma*. *Ctenomyces* and *Guaromyces* are also added in the list.<sup>1</sup>

Tinea capitis (TC) is a common dermatophytic infection of the scalp that can also involve the eyebrows and eyelashes. TC especially due to *Trichophyton violaceum* is common in children of African descent in Sub-Saharan Africa. It can be caused by any dermatophyte, except *Epidermophyton floccosum* and *Trichophyton concentricum*. The most commonly implicated dermatophytes are

of *Trichophyton* and *Microsporum* genera.


## 2. Case Report

A 12-year-old child from Southern Africa, who was born HIV positive, presented to the dermatology clinic with the history of itching, scaling, patches of baldness and multiple boggy swellings over the scalp (Figure 1 a,b). There were multiple kerions over the scalp and the child also had papules and vesicles around the ear, called Id's reaction (Figure 1 b and Figure 2). Id's reaction is a fungus-free papular eruption, often follicular, resembling pityriasis or tinea lesions on the ear and forehead.

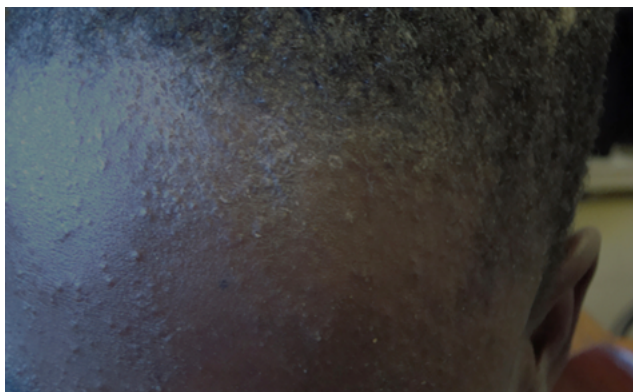The first author preferred to collect samples herself at the microbiology laboratory. The method preferred depended upon the clinical condition of the patient. The child was requested to report to the laboratory after hair wash with plain shampoo. Loose and damaged hairs were collected with the help of the wet gauze piece by gently rubbing it over the scalp. This method allows collection of affected hair. The second sample was collected with the help of sterile scalpel blade in a sterile petri dish. Scalp scrapings along with few hairs were inoculated in DERM agar. Also, 10% KOH mount was prepared for hair and scalp scrapings.

\* Corresponding author.

E-mail address: [avneet.singh.kalsi@gmail.com](mailto:avneet.singh.kalsi@gmail.com) (A. S. Kalsi).



**Fig. 1:** (a) Child with tinea capitis and multiple lesions. Areas of baldness due to scarring. (b) Identity reaction showing papules & vesicles around the ear.

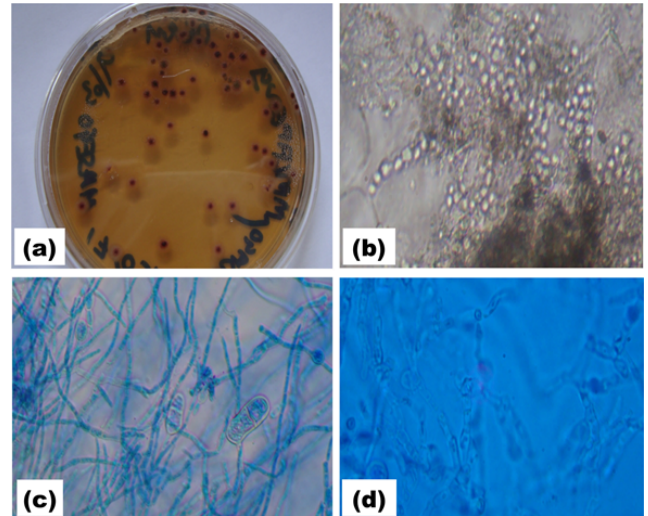


**Fig. 2:** Id's reaction (dermatophytid reaction). Multiple papulovesicular lesions on forehead.

Endothrix invasion of hair was seen. It looks like a bag of marbles (Figure 3b). The plates were incubated at 25°C and multiple violet waxy colonies were seen after two weeks (Figure 3 a).

Lacto Phenol Cotton Blue (LPCB) mount under high power showed arthroconidia and intercalary and terminal chlamydospores. Few oval micro-conidia and two-celled macro-conidia were observed (Figure 3 c and 3d).

The child was prescribed higher doses of oral griseofulvin 20 mg/kg/day, which adequately penetrates the shaft of the hair to eliminate the infection. Adjunct therapy was also given in the form of Selenium sulfide shampoo 2.5% twice weekly. Flucloxacillin was also given for initial 5 days. The child was also instructed not to share combs, towels, and other hair products. Cohabitants of child were also examined and started ketoconazole shampoo to reduce the risk of transmission from asymptomatic carriers. After two weeks of treatment with griseofulvin, patient developed vesiculo-papular rashes on forehead and right pinna. After 8 weeks of treatment, few colonies grew in the culture. The treatment was extended for four weeks with an increased dose of griseofulvin, 25 mg/kg/day, after which mycological cure was achieved.



**Fig. 3:** (a) Multiple waxy violet colonies on Derm agar after two weeks of incubation at 25° C (b) Endothrix (40X) infected hair packed with large spores resembling sack full of nuts and branched chains of fungal hyphae (c) Lacto Phenol Cotton Blue (LPCB) mount with rare two-celled macroconidia (d) LPCB mount showing terminal and intercalary chlamydospores.

### 3. Discussion

Tinea capitis is a common infection of the scalp hair caused by dermatophytic fungi and occurring predominantly in children.<sup>2</sup> It is manifested by hair loss, which might be related with signs of inflammation. Hence, clinical signs may either be subtle, with just gentle scaling of the scalp, or clear such as broken hairs, patches of obvious alopecia, pustules, and enormous inflammatory swellings (kerion).<sup>3</sup> Tender occipital lymphadenopathy may also occur in inflammatory tinea capitis forms.<sup>3</sup> It is the most common dermatophytic infection in children under 12 years of age, with predominance in those of sub-Saharan African descent.<sup>4</sup> Poor cleanliness, playing in sand, swarmed living conditions, and low financial status have been related with the advancement of tinea.<sup>5</sup> Specifically, kerion is for the most part connected with contamination by zoophilic dermatophytes.<sup>6</sup> Tinea capitis is effectively spread from the infected and often asymptomatic carriers, making family epidemics more common. Spores of *Trichophyton spp.* have been found from many sources such as combs, hats, and pillows.<sup>7</sup> Post-pubertal sebum has fungistatic properties due to fatty acids.<sup>8</sup>

Here our patient though 12-year-old looks much younger than his actual age, because he had mother-to-child transmission of HIV. HIV prevalence in children  $\leq$  14 years of age has been estimated to be 2%.<sup>9</sup> *T. violaceum* has been shown to be the main causative dermatophyte of tinea capitis in Kenya, Ethiopia, or Botswana.<sup>10-12</sup> Onychomycosis is one of the early manifestations of HIV infection with a prevalence of 15-40%.<sup>13</sup>

All systemic antifungals are basically much more effective in the presence of endothrix infection (e.g. *Trichophyton spp.*) than in subjects with ectothrix disease (e.g. *M. canis*). This illustrates the importance of culturing to identify the pathogen. In most of the African countries, tinea capitis is the commonest clinical form and next in frequency is tinea corporis. But, in Botswana onychomycosis of fingernails due to *T. violaceum* was found to be the commonest clinical form.<sup>14</sup> Despite the success of the national ART programme, Botswana, a country of approximately 2 million people, still has high incidence of new HIV infections in certain populations and HIV prevalence among the highest in the world, with an estimated adult HIV prevalence of 25% in 2014.<sup>9,15</sup>

#### 4. Conclusion

Tinea capitis affects the scalp and hair shafts, causing small patches of itchy, scaly skin. It can be associated with multiple kerions which is an inflammatory type of tinea capitis, which makes treatment more difficult. TC can be caused by the dermatophytes in the genera *Trichophyton* and *Microsporum* that invades the hair shaft. TC especially due to *Trichophyton violaceum* is common in children of African descent in Sub-Saharan Africa. It can also be associated with Id's reaction, also known as dermatophytid reaction, on pinna or forehead, which goes away once the dermatophyte infection has been cured, but it can be treated symptomatically with lubricants, topical steroids (rarely, oral steroids), and when needed, oral antihistamines. It is predominantly seen in pre-pubertal children, more often boys than girls. HIV positive patients requires higher doses of griseofulvin for longer duration in order to achieve clinical as well as mycological cure.

#### 5. Source of Funding

None.

#### 6. Conflict of Interest

None.

#### References

1. de Hoog GS, Dukik K, Monad M, Packeu A, Stubbe D, et al. Toward a novel multilocus phylogenetic taxonomy of the dermatophytes. *Mycopathologia*. 2017;182(1-2):5–31.
2. Elewski BE. Tinea capitis: a current perspective. *J Am Acad Dermatol*. 2000;42(1):1–20. Pt 1.
3. Moriarty B, Hay R, Morris-Jones R. The diagnosis and management of tinea. *BMJ*. 2012;345:e4380.
4. Patel GA, Schwartz RA. Tinea capitis: still an unsolved problem? *Mycoses*. 2011;54:183–188.
5. Pires CA, Cruz NF, Lobato AM, Sousa PO, Carneiro FR, et al. Clinical, epidemiological, and therapeutic profile of dermatophytosis. *An Bras Dermatol*. 2014;89(2):259–264.
6. Larralde M, Gomar B, Boggio P, Abad ME, Pagotto B. Neonatal kerion Celsi: report of three cases. *Pediatr Dermatol*. 2010;27(4):361–364.
7. Mirmirani P, Tucker LY. Epidemiologic trends in pediatric tinea capitis: a population-based study from Kaiser Permanente Northern California. *J Am Acad Dermatol*. 2013;69(6):916–921.
8. Shy R. Tinea corporis and tinea capitis. *Pediatr Rev*. 2007;28(5):164–174.
9. UNAIDS. Botswana HIV estimates ; 2018,. Available from: <http://www.unaids.org/en/regionscountries/countries/botswana>.
10. Chepchirchir A, Bii C, Ndinya-Achola JO. Dermatophyte infections in primary school children in Kibera slums of Nairobi. *East Afr Med J*. 2009;86(2):59–68.
11. Ali J, Yifru S, Woldeamanuel Y. Prevalence of tinea capitis and the causative agent among school children in Gondar, North West Ethiopia. *Ethiop Med J*. 2009;47(4):261–269.
12. Thakur R. Tinea capitis in Botswana. *Clin Cosmet Investig Dermatol*. 2013;6:37–41.
13. Surjushe A, Kamath R, Oberai C, Saple D, Thakre M, et al. A clinical and mycological study of onychomycosis in HIV infection. *Indian J Dermatol Venereol Leprol*. 2007;73(6):397–401.
14. Thakur R. Spectrum of dermatophyte infections in Botswana. *Clin Cosmet Investig Dermatol*. 2015;8:127–133.
15. Karim SA. Is the UNAIDS target sufficient for HIV control in Botswana? *Lancet HIV*. 2016;3(5):e195–e196.

#### Author biography

Rameshwari Thakur Professor

Avneet Singh Kalsi Research Scholar

**Cite this article:** Thakur R, Kalsi AS. A child of African origin with tinea capitis and multiple kerions. *Indian J Clin Exp Dermatol* 2019;5(4):346–348.