



## Case Report

# A rare case report of Goltz syndrome and review of literature

Nidhi Gupta<sup>1</sup>, Debabrata Bandyopadhyay<sup>2</sup>, Shashank Bhargava<sup>1,\*</sup>

<sup>1</sup>RD Gardi Medical College, Ujjain, Madhya Pradesh, India

<sup>2</sup>Medical College Kolkata, Kolkata, West Bengal, India



### ARTICLE INFO

#### Article history:

Received 21-11-2019

Accepted 26-11-2019

Available online 20-12-2019

#### Keywords:

Goltz syndrome

Focal dermal hypoplasia.

### ABSTRACT

Goltz syndrome is X linked dominant disorder of mesodermal and ectodermal tissue, occurring mostly in females. It is usually lethal in males, although alive males have been reported probably due to sporadic mutations or mosaicism. We hereby report a case of an 18 day old baby girl who presented with multiple atrophic hypopigmented lesions in blaschkoid pattern along with limb defects. Histopathological examination revealed atrophy of the dermis and was consistent with the diagnosis of Goltz syndrome. The case is being reported for its rarity.

© 2019 Published by Innovative Publication. This is an open access article under the CC BY-NC-ND license (<https://creativecommons.org/licenses/by/4.0/>)

## 1. Introduction

Goltz syndrome (focal dermal hypoplasia) is an X-linked dominant disorder of mesodermal and ectodermal tissue, more commonly seen in females.<sup>1</sup> It is usually lethal in the other gender, although reports of alive males have been seen probably due to sporadic mutations or mosaicism.<sup>2,3</sup> It has been also described as atrophoderma linearis maculosa et papillomatosis congenitalis by Leibermann.<sup>4</sup> *PORCN* gene on chromosome Xp11.23 loci has been identified as the causative defect,<sup>5-7</sup> encoding an *O*-acyltransferase enzyme in Wnt signalling which ultimately is involved in ectodermal – mesodermal development. Heterozygous deletions of *PORCN* gene is mostly documented, although nonsense, missense and splice site mutations have also been implicated.<sup>5,7-9</sup> There have been very few cases reported from Eastern part of India.

## 2. Case Report

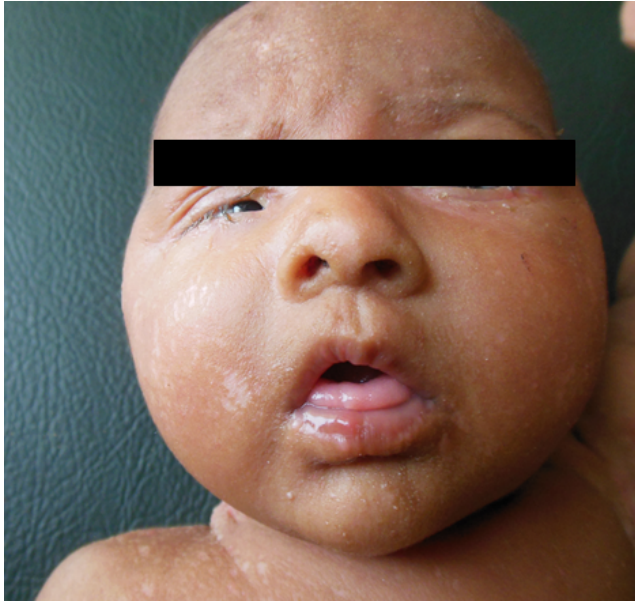An 18-day-old baby girl, term, born of consanguineous parentage, presented with hypopigmented and pinkish macules, papules and plaques on the, face, arm, trunk and lower extremities since birth. (Figures 1 and 2) Small

pinkish red elevated lesions were distributed over lower limbs. She had abnormalities of limbs right from birth, it was noticeable that the right side was smaller. There was no history of unusual drug intake by mother and perinatal history was uneventful. None of the family members of the child had similar symptoms.

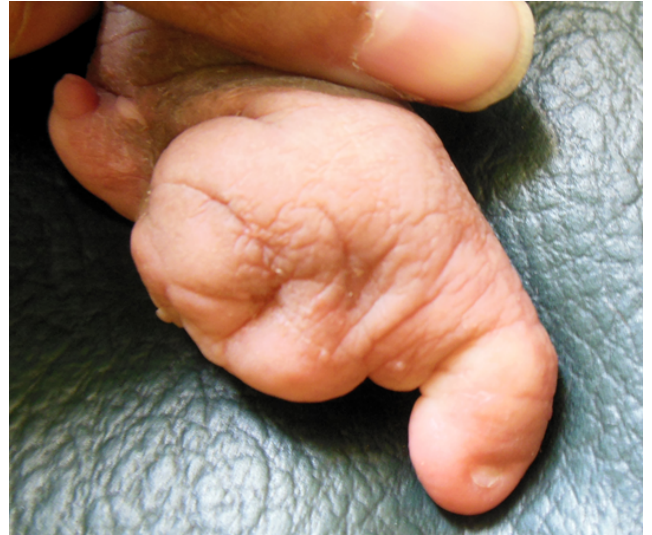General examination revealed megalopinna and a pointed chin with notched alaenasi. On cutaneous examination we found multiple atrophic hypopigmented lesions arranged linearly or in group along lines of Blaschko on the arm extending to trunk, thighs, gluteal region, genitalia and over both upper and lower limbs. (Figure 3) On lower limbs, reddish, atrophic and hypopigmented lesions with interspersed hyperpigmented hyperkeratotic lesions were noted along with soft papular lesions. Syndactyly of 2<sup>nd</sup> and 3<sup>rd</sup> digits of both hands with single digit right toe were noted. (Figure 4) Ophthalmic examination revealed right sided microcornea and micropthalmia, systemic examination revealed no abnormality. Routine blood counts and serum biochemistry were non-contributory. X-ray showed hypoplastic right clavicle with fusion of T4-T5 vertebrae. (Figure 5) Histopathological examination showed atrophy of the dermis which is marked in the initial presentation of the disorder. (Figure 6)

\* Corresponding author.

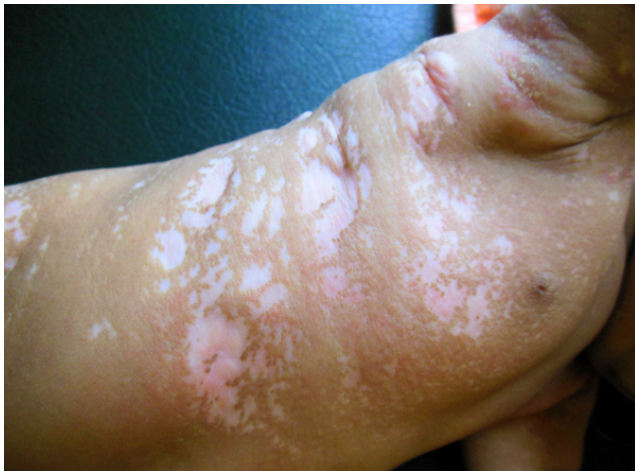E-mail address: [shashank2811@gmail.com](mailto:shashank2811@gmail.com) (S. Bhargava).



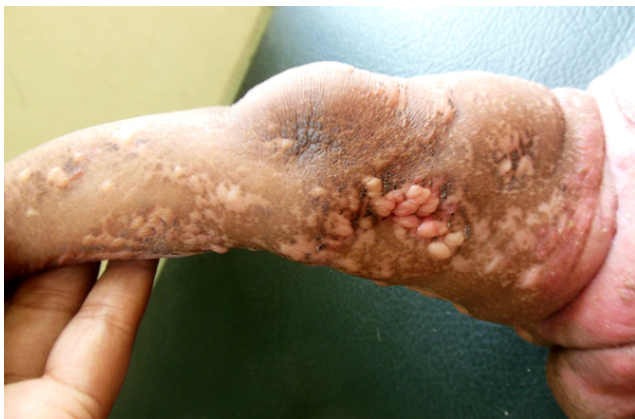**Fig. 1:**



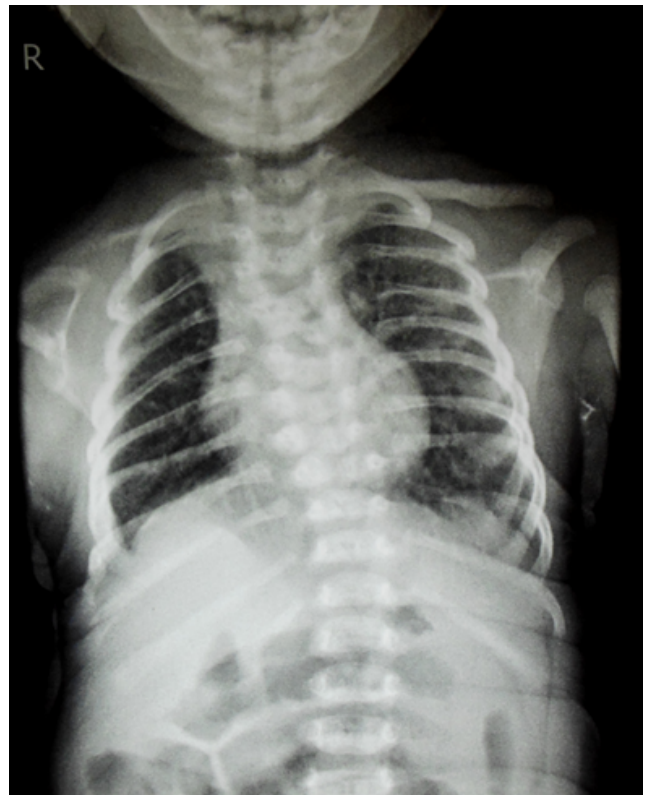
**Fig. 4:**



**Fig. 2:**

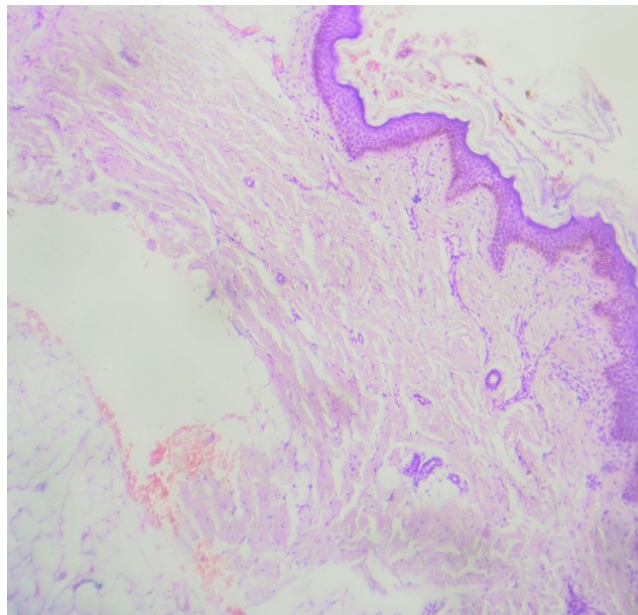


**Fig. 3:**



**Fig. 5:**





**Fig. 6:**

### 3. Discussion

Focal dermal hypoplasia (FDH) or Goltz syndrome is a meso-ectodermal disorder which has X-linked dominant inheritance. Newborns usually present with erythematous, hypopigmented, or depigmented atrophic macules, most commonly on thighs, buttocks and trunk, arranged in either Blaschkoid or reticulate pattern. In very few cases, even blisters or erosions may be present at birth that may leave behind atrophic scars, thus mimicking incontinentia pigmenti.<sup>10</sup> The hallmark of FDH is the thinning of the dermis resulting in depressed linear lesions with herniation of subcutaneous fat. This fat classically presents as soft, pinkish yellow to brown nodules in the popliteal and cubital fossa. Occasionally raspberry-like papillomas may be present on the lips, perineum, fingers, toes, ears, buccal mucosa and oesophagus.<sup>11</sup> Pruritus, hyperkeratosis of palms and soles, photosensitivity, xerosis, dermatoglyphic changes, sweating abnormalities, sparse hair, absent or dystrophic nails also have been reported.<sup>12</sup>

Later in life, several dental abnormalities may occur in the forms of hypodontia, microdontia and malocclusion and enamel hypoplasia.<sup>13</sup> Skeletal defects include hypoplasia of the digits, syndactyly, polydactyly, ectrodactyly and vertebral abnormalities such as kyphosis, scoliosis, and vertebral body fusions. Spina bifida has been reported in upto 60-70% patients of FDH. A pathognomonic finding is the lobster claw deformity seen in this disorder.<sup>14</sup> Long bones have typical findings in their metaphyses, they have fine, parallel, vertical, radio-opaque stripes striations which are known as osteopathia striata.

Characteristic facial features comprise rounded and small skull, pointed chin with triangular facial outline.

Asymmetry has been noted in alaenasi, face, trunk and limbs. Ocular abnormalities include microcornea, microphthalmia and colobomas. Other general observations which are commonly noted consist of short stature, mental retardation, hearing loss, microcephaly, cleft lip and palate. Gastrointestinal defects can be duodenal atresia, intestinal malrotation, hernias like umbilical, inguinal, epigastric or diaphragmatic.<sup>15</sup> Other organ abnormalities include bicornuate uterus, cardiac defects like patent ductus arteriosus and ventricular septal defect, hypoplasia of lungs, horseshoe kidneys, hypoplastic kidney or absent kidney, bilateral hydronephrosis and hydroureter. Rare cases of absent nipples and supernumerary nipples have also been reported.<sup>10,14</sup>

The morbidity and mortality of FDH depends on the extent and severity of organ involvement. Most of the internal organ affections in the syndrome are present at birth and usually remain unchanged. Although many severely affected babies die in infancy, the prognosis is generally good and most children live to adulthood.

Regular follow up is needed for early detection and timely preventative and/or corrective treatment of organ involvement in FDH patients. Treatment with a flashlamp-pumped pulse dye laser has shown to improve the clinical appearance of the telangiectatic and erythematous skin lesions.<sup>16</sup>

### 4. Conclusion

Goltz syndrome is a very rare disorder and its prevalence is very low in this region of world, it has been reported due to its rarity.

### 5. Conflicts of interest

None.

### 6. Source of Funding

None.

### References

1. Giam YC, Khoo BP. What syndrome is this? Focal dermal hypoplasia (Goltz syndrome). *Pediatr Dermatol.* 1998;15(5):399–402.
2. Lasocki AL, Stark Z, Orchard D. A case of mosaic Goltz syndrome (focal dermal hypoplasia) in a male patient. *Australas J Dermatol.* 2011;52(1):48–51.
3. Jain A, Chander R, Garg T, Shetty GSN. A rare multisystem disorder: Goltz syndrome-case report and brief overview. *Dermatol Online J.* 2010;16(6):2.
4. Goltz RW. Focal dermal hypoplasia syndrome: An update. *Arch Dermatol.* 1992;128(8):1108–1111.
5. Wang X, Reid-Sutton V, Omar-Peraza-Llanes J, Yu Z, Rosetta R, et al. Mutations in X-linked PORCN, a putative regulator of Wnt signaling, cause focal dermal hypoplasia. *Nat Genet.* 2007;39(7):836–838.
6. Paller. Wnt signaling in focal dermal hypoplasia. *Nat Genet.* 2007;39(7):820–821.
7. Leoyklang P, Suphapeetiporn K, Wanankul S, Shotelersuk V. Three novel mutation in the PORCN gene underlying focal dermal

- hypoplasia. *Clin Genet.* 2008;73(4):373–379.
8. Grzeschik KH, Bornholdt D, Oeffner F, Knig A, Boente MDC, et al. Deficiency of PORCN, a regulator of Wnt signaling, is associated with focal dermal hypoplasia. *Nat Genet.* 2007;39(7):833–835.
  9. Clements SE, Wessagowit V, Lai-Cheong JE, Arita K, Mcgrath JA. Focal dermal hypoplasia resulting from a new nonsense mutation, p.E300X, in the PORCN gene. *J Dermatol Sci.* 2008;49(1):39–42.
  10. Srinivas SM, Hiremagalore R. Focal Dermal Hypoplasia: A Rare Case Report. *Indian J Dermatol.* 2015;60(1):106.
  11. Zala L, Ettlin C, Krebs A. Fokale dermale Hypoplasie mit Keratokonus, Osophagus papillomaen und Hidrokystomen. *Dermatol.* 1975;150(3):176–185.
  12. Temple IK, Macdowall P, Baraitser M, Atherton DJ. Focal dermal hypoplasia (Goltz syndrome). *J Med Genet.* 1990;27(3):180–187.
  13. Baxter AM, Shaw MJ, Warren K. Dental and oral lesions in two patients with focal dermal hypoplasia (Goltz syndrome). *Br Dent J.* 2000;189(10):550–553.
  14. Riyaz N, Riyaz A, Chandran R, Rakesh SV. Focal dermal hypoplasia (Goltz syndrome). *Br Dent J.* 2000;189(10):550–553.
  15. Irvine AD, Stewart FJ, Bingham EA, Nevin NC, Boston VE. Focal dermal hypoplasia (Goltz syndrome) associated with intestinal malrotation and mediastinal dextroposition. *Am J Med Genet.* 1996;62(3):213–215.
  16. Alster TS, Wilson F. Treatment of cutaneous lesions with 585-nm flashlamp-plumed pulsed dye laser. *Arch Dermatol.* 1995;131(2):143–144. Focal dermal hypoplasia (Goltz syndrome).

### Author biography

**Nidhi Gupta** Senior Resident

**Debabrata Bandyopadhyay** Professor and Head

**Shashank Bhargava** Assistant Professor

**Cite this article:** Gupta N, Bandyopadhyay D, Bhargava S. A rare case report of Goltz syndrome and review of literature. *Indian J Clin Exp Dermatol* 2019;5(4):356-359.