



Original Research Article

Trichoscopic findings in alopecia areata- a cross sectional study

Krishnendra Varma¹, Ujjwal Kumar¹, Manu Kataria^{1,*}¹Dept. of Dermatology, RD Gardi Medical College, Ujjain, Madhya Pradesh, India

ARTICLE INFO

Article history:

Received 02-03-2020

Accepted 13-05-2020

Available online 25-06-2020

Keywords:

Trichoscopy

Alopecia areata

Exclamation mark hair

Black dots

Yellow dots

ABSTRACT

Background: Alopecia areata remains one of the common cases presenting in clinical practice. Considering the anxious state of patients it becomes very important to correctly diagnose the cause and type of alopecia followed by the appropriate treatment. Trichoscopy is a novel, sensitive, non invasive modality which provides rapid detection of alopecia areata with advanced diagnostic accuracy, predicts the cause of disease and decreases unnecessary biopsies.

Aim and Objectives: To determine the Trichoscopic findings in alopecia areata in adult population.

Materials and Methods: 122 patients with clinically diagnosed alopecia areata were enrolled. After taking proper history and consent trichoscopy was done using a Dinolite digital microscope system in both non polarized and polarized modes and their photographs were taken.

Result: 122 patients with alopecia areata were enrolled. Yellow dots were the most common trichoscopic findings observed in 108 (88.5%) patients followed by short vellus hair 66 (54.1%), short regrowing hair 58 (47.5%), exclamation mark hair 56 (45.9%), black dots 44 (36.1%) and broken hair 34 (27.9%).

© 2020 Published by Innovative Publication. This is an open access article under the CC BY-NC license (<https://creativecommons.org/licenses/by-nc/4.0/>)

1. Introduction

Alopecia areata (AA) is a common non scarring alopecia affecting 0.1-0.2 percent of general population of all races.¹ It usually presents as well circumscribed patches of sudden hair loss. It can affect males and females of any age and in many cases a family history of AA itself or other autoimmune disorders is present. Patients with AA have higher than expected incidence of thyroid disease, vitiligo and atopic eczema.²⁻⁴

Clinical diagnosis of AA is not challenging but at times it may be confused with other patchy alopecias like Tinea capitis, Trichotillomania, Telogen effluvium etc. Moreover the activity and severity of the disease can not be assessed clinically. Trichoscopy reveals specific patterns in AA and can be an aid to diagnose, assess severity and disease activity in AA.

Trichoscopic findings in AA may differ depending on disease activity, severity and duration of the disease. Black

dots, dystrophic and fractured hair, exclamation mark hair (EMH) are the most specific findings in AA and are indicative of abrupt anagen alterations and correlate with strong and ongoing disease activity. While yellow dots may be observed in all stages of both acute and chronic alopecia areata, short re-growing hair indicate a better prognosis.⁵

2. Materials and Methods

The study was a cross sectional observational study conducted in the Department of Dermatology, Venereology and Leprosy, R.D.Gardi Medical College and C.R. Gardi Hospital, Ujjain (M.P.), between January 2017-December 2018. Male and female patients of clinically diagnosed Alopecia areata between the age group of 18-50 years were included after taking informed consent. Hair loss due to external injury, chemotherapy or any drugs and systemic illness and hair shaft disorders were excluded.

In every patient a detailed history was elicited and recorded on a proforma, and relevant clinical examination was performed, following which trichoscopic examination

* Corresponding author.

E-mail address: livemanu@gmail.com (M. Kataria).

was performed using a DINOLITE digital microscope system with adjustable polarization flexible LED system equipped with a video camera with lenses providing magnifications ranging from 20X to 220X.

3. Results

A total of 122 patients with AA were enrolled including 76 males and 46 females. The mean age of presentation was 30.46 years. 80 (65.5%) patients were between the age group of 20-40 years. Majority (95%) of the patients presented within 6 months of the onset of alopecia areata. On trichoscopy Yellow dots were the most common trichoscopic findings observed in 108 (88.5%) patients followed by short vellus hair 66 (54.1%), short regrowing hair 58 (47.5%), exclamation mark hair 56 (45.9%), black dots 44 (36.1%) and broken hair 34 (27.9%).




Fig. 1: Trichoscopy showing yellow dots (arrow) and short vellus hair (circle)

4. Discussion

Yellow dots, first proposed by Ross et al.⁶ are seen as yellow colored round or polycyclic dots, which represent follicular infundibulum, distended with degenerating keratinocytes and sebum. Yellow dots are the most common and most sensitive feature of alopecia areata. In a study conducted by Inui et al.⁷, yellow dots were seen in 63.7% of cases in contrast to Ross et.al. study⁶ where 94.8% cases with alopecia areata had yellow dots. Similarly a study from North India by Chiramel et al.⁸ found 87.5% patients of alopecia areata with yellow dots. In our study yellow dots were observed in 88.5% patients. In a study by Naveen et al.⁹ in South India, the yellow dots were found in 57.33% of patients. The low incidence may be attributed to the skin color of South Indian patients which make the yellow dots difficult to visualize. Although characteristic of alopecia areata, yellow dots are also seen in androgenetic alopecia, discoid lupus erythematosus, dissecting cellulitis of scalp etc.⁵

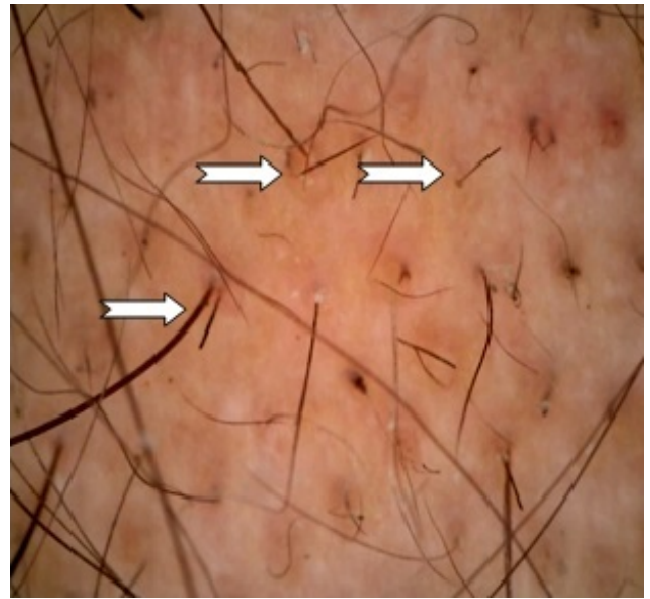


Fig. 2: Trichoscopy showing exclamation mark hair (arrows)

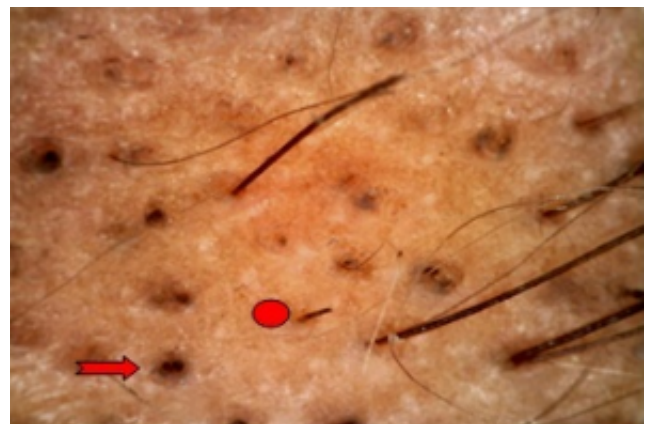


Fig. 3: Trichoscopy showing black dots (arrow) and broken hair (circle)

Exclamation mark hair (EMH) is a broken hair with a dark, frayed, thick tip. Its proximal portion is thin and hypopigmented. EMH are typical of alopecia areata and represent peribulbar lymphocytic activity leading to thin hair production. They are co-related with disease activity.¹⁰ In 2014, Ankad et al.¹¹ also reported them to be the sign of active disease.¹¹ EMH were seen in 30% 31.7% of cases by Inui et al.⁷ and Ankad et al.¹¹ respectively.

Dystrophic or broken hair (BH) correlates with disease activity. In our study broken hair were seen in 27.9% of the cases. BH were observed in varying proportions from 30% to 75% in various published studies.^{7,8,11}

Black dots (BD) are seen within the yellow dots and represent broken pigmented hair (cadaverized hair), that are fractured before emerging from the scalp due to severe

inflammatory process or a tractional trauma.¹² Numerous black dots are found in patients with AA. Previous studies have shown BD ranging from 20% to 77%.^{7,8,11} In our study BD were seen in 36.1%.

Short vellus hair (SVH) represent hair re-growth. They appear as either short, upright, tapered regrowing terminal hairs of normal thickness or as thin coiled “pig tail” hair. SVH were seen in 54.1% of cases of AA in our study. Our findings were consistent with studies by Chiramal et al⁸ (50%) and Thappa et al¹³ (40.9%).

5. Conclusion

Trichoscopy is a rapid and non invasive tool which can be reliably used to diagnose and assess the severity and disease activity in Alopecia areata. Hence a trichoscopic evaluation should be done in every case of AA.

6. Source of Funding

None.

7. Conflict of Interest

None.

References

1. Tan E, Tay YK, Goh CL, Giam YC. The pattern of alopecia areata in Singapore - A study of 219 Asians. *Int J Dermatol*. 2002;41:748–53.
2. Wasserman D, Guzman-Sanchez DA, Scott K, McMichael A. Alopecia areata. *Int J Dermatol*. 2007;46:121–31.
3. Alkhalifah A, Alsantali A, Wang E, Mcelwee KJ, Shapiro J. Alopecia areata update: Part I. Clinical picture, histopathology, and pathogenesis. *J Am Acad Dermatol*. 2010;62:177–88.
4. Barahmani N, de Andrade M, Slusser JP, Wei Q, Hordinsky M, Price VH, et al. Human Leukocyte Antigen Class II Alleles Are Associated with Risk of Alopecia Areata. *J Invest Dermatol*. 2008;128(1):240–3.
5. Tosti A, Duque-Estrada B. Dermoscopy in hair disorders. *J Egypt Womens Dermatol Soc*. 2010;7:1–4.
6. Ross EK, Vincenzi C, Tosti A. Videodermoscopy in the evaluation of hair and scalp disorders. *J Am Acad Dermatol*. 2006;55(5):799–806.
7. Inui S, Nakajima T, Nakagawa K, Itami S. Clinical significance of dermoscopy in alopecia areata: analysis of 300 cases. *Int J Dermatol*. 2008;47(7):688–93.
8. Sharma V, Chiramal M, Khandpur S, Sreenivas V. Relevance of trichoscopy in the differential diagnosis of alopecia: A cross-sectional study from North India. *Indian J Dermatol Venereol Leprol*. 2016;82(6):651–8.
9. Naveen K, Athanikar S, Reshme P, Hegde S. Clinical and dermatoscopic patterns of alopecia areata: A tertiary care centre experience. *Int J Trichology*. 2013;5(3):132.
10. Rudnicka L, Olszewska M, Rakowska A, Czuwara J, Areata A. In: Atlas of Trichoscopy. London: Springer; 2012. p. 205–20.
11. Ankad B, , Beergouder S, Khageshan A. Atypical Presentation of Lupus Vulgaris: A Case Report. 2014;1.
12. Black dots in trichoscopy. *Clin Exp Dermatol*. 2012;37(6):615–9.
13. Thappa D, Mane M, Nath A. Utility of dermoscopy in alopecia areata. *Indian J Dermatol*. 2011;56(4):407.

Author biography

Krishnendra Varma Professor and Head

Ujjwal Kumar Associate Professor

Manu Kataria Junior Resident IIIrd Year

Cite this article: Varma K, Kumar U, Kataria M. **Trichoscopic findings in alopecia areata- a cross sectional study.** *IP Indian J Clin Exp Dermatol* 2020;6(2):160-162.