

Annular Pustular Psoriasis in a Five Year Old Child

Nidhi R Sharma^{1,*}, Kiran Godse², Sharmila Patil³, Nitin Nadkarni⁴, Manjyot Gautam⁵

¹Senior Resident, Department of Dermatology, Shaheed Hasan Khan Government Medical College, Nalhar, Mewar,
^{2,4}Professor, ³Professor & HOD, ⁵Associate Professor, Department of Dermatology, Dr. D.Y. Patil Medical College,
Nerul, Navi Mumbai

***Corresponding Author:**

Email: drmidhirsharma@gmail.com

ABSTRACT

Background: Annular pustular psoriasis is a unique variant of pustular psoriasis with a relatively good prognosis. It has been classified in four forms: von zumbusch, annular, exanthematous and localized (except for palmoplantar). The APP variant has also been referred to as “erythema circine recidivans”, Lapiere-type psoriasis, and erythema annulare centrifugum-type psoriasis.

Main Observations: Five year old male child came with pus filled lesions over the body since 1 month. He had similar complaints 7 months back which were pus filled lesions. He presented with fever associated with chills. Lesions were in form of well-defined annular erythematous plaques surrounded by a rim of few mm size pustules present over trunk and extremities both in extensor and flexor area. Histopathological examination showed sub corneal pustule, club shaped rete ridges and suprapapillary thinning with dilated blood vessels. A diagnosis of annular pustular psoriasis was made.

Results: We report this case for the rarity of the condition with chronic and relapsing course but with a good prognosis.

INTRODUCTION

Annular pustular psoriasis is a unique variant of pustular psoriasis with a relatively good prognosis. It has been classified in four forms: von zumbusch, annular, exanthematous and localized (except for palmoplantar). We report a case of five year old child with annular pustular lesions all over the body since one month. Histopathology of the pustular lesion showed subcorneal pustule with suprapapillary thinning and dilated blood vessels.

With clinical and histopathological findings a diagnosis of annular pustular psoriasis was made.

CASE REPORT

A five year old male child came with pus filled lesions over the body since 1 month. Patient had similar complaints 7 months back which were pus filled lesions, he was treated with tablet methotrexate and showed complete clearing of lesions within 6 months and when medication was stopped within a month he had an sudden eruption of annular pus filled lesions all over the body including genitals but sparing mucosa, palms and soles. He had presented with fever associated with chills. However, there was no history of stress, joint complaints, sore throat, urinary tract infection, long term use of any drug or treatment or similar complaints in the family.

On examination the lesions were distributed symmetrically all over the body including trunk, extremities, scalp, external ear and genitals with sparing of palms, soles and mucosa. Lesions were in form of well-defined annular erythematous plaques surrounded by a rim of few mm size pustules present over trunk

and extremities both in extensor and flexor area [Fig. 1].

Over genitals, on the shaft of penis erythematous plaques with few pustules were seen. Koebner's phenomenon was positive. Pitting was present on most of the nails. On General examination patient was toxic, showed tachycardia, pyrexia of 101 degree F and with normal blood pressure. Systemic examination was normal.

A differential diagnosis of impetigo, annular pustular psoriasis, tinea incognito and linear IgA dermatosis was considered.

Laboratory investigations showed increased total leucocyte count of 22,000/cmm with neutrophilia. Other blood investigations including erythrocyte sedimentation rate, C- reactive protein, Liver and renal function, serum calcium were within normal limits.

Gram stain showed pus cells without cocci.

Histopathology examination showed subcorneal pustule with epidermis showing with few areas of parakeratosis, acanthosis and club shaped rete ridges. There is suprapapillary thinning with dilated blood vessels. Dermis showed lymphocytic infiltrate which was mainly perivascular [Fig. 2]. A final diagnosis of annular pustular psoriasis was made.

Patient was treated with injection amoxicillin (100 mg /kg /day) thrice a day for 7 days, tablet acitretin 25mg alternate day for 3 months along with emollients over the body and moderate potency topical steroids on the scalp. And within a week there was complete clearance of pustular lesions with scaling present all over the lesions.

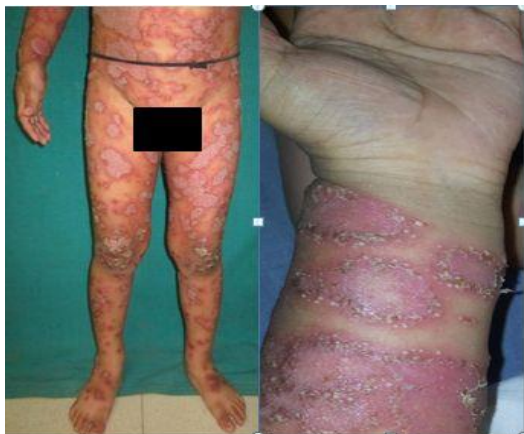

Fig. 1: Well defined annular erythematous plaques surrounded by a rim of few mm size pustules present over trunk and extremities and flexor aspect of forearm

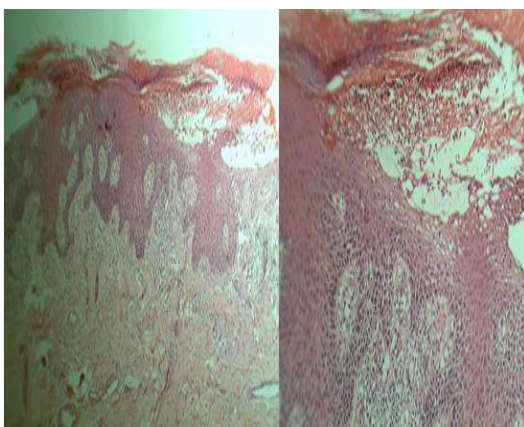


Fig. 2: Subcorneal pustule with epidermis showing with few areas of parakeratosis, acanthosis and club shaped rete ridges

DISCUSSION

Psoriasis is a chronic inflammatory condition with multifactorial aetiology. The exact pathogenesis of psoriasis is not well understood. 71% of children with psoriasis have a positive history for psoriasis in a first degree relative⁽¹⁾. Early onset of the disease is related to allele HLA-Cw6 at the gene PSORS1⁽²⁾. It affects about 3.5% of the population with 10% of these patients develop psoriasis before 10 years of age.

Factors such as Streptococcal pharyngitis and perianal streptococcal dermatitis, trauma, emotional stress, and drugs like withdrawal of corticosteroids, beta blockers, antimalarial and lithium can precipitate and exacerbate psoriasis in children.

Pustular psoriasis is not often seen in children. Baker and Ryan classified this type of psoriasis in four forms: von zumbusch, annular, exanthematous and localized (except for palmoplantar)⁽³⁾. APP has been noted to have a more benign course than GPP⁽⁴⁾. The APP variant has also been referred to as “erythema circine

recidivants”, Lapiere-type psoriasis, and erythema annulare centrifugum-type psoriasis^(5,6).

Psoriasis often presents differently in children than in adults. It is characterized by annular lesions with erythematous, scaly, and pustular margins. Involvement of the face and flexural regions are more common in children than adults. Psoriatic arthritis and nail involvement are uncommon. Annular pustular psoriasis, a manifestation of generalized pustular psoriasis, occurs more frequently in children than in adults.

Differential diagnoses like atopic dermatitis, staphylococcal scalded skin syndrome, miliaria pustulosa, tinea corporis, nummular atopic dermatitis, granuloma annulare, urticaria, erythema multiforme, and erythema annulare centrifugum should be ruled out by correlating clinical data and histopathological findings. It also includes rarer conditions such as erythema chronicum migrans, ichthyosis linearis circumflexa, and annular erythema of infancy.

For treatment patient and parent counselling is of utmost importance explaining the chronicity and relapsing nature of the disease. Emollients and keratolytic agents are important part in the topical treatment of psoriasis. Tablet acetrein in a dose of 0.5 – 1mg /kg B.W are the drug of choice and oral administration with milk or fatty foods enhances absorption⁽⁷⁾. Other therapeutic options include cyclosporine A, NBUVB, methotrexate and daps one. Another recent option is biologicals such as infliximab and etanercept. Annular pustular psoriasis is a unique variant of pustular psoriasis with a relatively good prognosis⁽⁸⁾.

A study by Kumar *et al* with 419 children with psoriasis age of onset ranged from 4 days to 14 years, male and female incidence was equal, and plaque type psoriasis was the most common clinical presentation⁽⁹⁾. In a study from South India on pattern of dermatoses in children over a period of one year, psoriasis accounted for 1.4% of the total skin conditions⁽¹⁰⁾.

CONCLUSION

There are less than 200 cases of the pustular psoriasis in children⁽³⁾, described in medical literature⁽¹¹⁾. Hence therefore we report this case for the rarity of the condition.

REFERENCES

1. Morris A, Rogers M, Fischer G, et al. Childhood psoriasis: a clinical review of 1262 cases. *Pediatric Dermatol* 2001;18:188-98.
2. Valdimarsson H. The genetic basis of psoriasis. *Clin Dermatol* 2007 Nov-Dec;25:563-7.
3. Baker H, Ryan TJ. Generalized pustular psoriasis. A clinical and epidemiological study of 104 cases. *Br J Dermatol*. 1968;80: 771-793.
4. Farber EM, Nall L. Pustular psoriasis. *Cutis* 1993; 51: 29-32.
5. Park YM, Kang H, Cho BK. Annular pustular psoriasis localized to the dorsa of the feet. *Acta Derm Venereol*.1999;79: 161- 162.

6. Marks R. Erythema-annulare like pustular psoriasis. *Br Med* 1968; 80: 128 - 129.
7. Kopp T et al . Successful use of acitretin in conjunction with narrowband ultraviolet B phototherapy in a child with severe pustular psoriasis, von Zumbusch type. *Br J Dermatol* 2004;151: 912 - 916.
8. Liao PB et al . Annular pustular psoriasis--most common form of pustular psoriasis in children: report of three cases and review of the literature. *Pediatr Dermatol*. 2002 Jan-Feb;19(1): 19 -25.
9. Kumar B, Jain R, Sandhu K, Kumar B. Epidemiology of childhood psoriasis: A study of 419 patients from northern India. *Int J Dermatol* 2004;43: 654 - 658.
10. Karthikeyan K, Thappa DM, Jeevankumar B. Pattern of pediatric dermatoses in a referral center in South India. *Indian Pediatr* 2004;41: 373- 377.
11. Cassandra M, Conte E, Cortez B. Childhood pustular psoriasis elicited by the streptococcal antigen: a case report and review of the literature. *Pediatr Dermatol*. 2003;20: 506-510.