

Content available at: <https://www.ipinnovative.com/open-access-journals>

IP Indian Journal of Clinical and Experimental Dermatology

Journal homepage: <https://www.ipinnovative.com/journals/IJCED>

## Original Research Article

# An observational study to analyze the association of Acne Vulgaris, Seborrhea and Alcohol consumption in clinically diagnosed cases of Dyssebacia

Sukanya G<sup>1</sup>, Ojas Dipak Kulkarni<sup>1</sup>, N. Ashok Kumar<sup>1,\*</sup>, D Manoharan<sup>1</sup>,  
K Manoharan<sup>1</sup>

<sup>1</sup>Dept. of Dermatology, Venereology and Leprosy, Sree Balaji Medical College and Hospital, Chennai, Tamil Nadu, India



## ARTICLE INFO

## Article history:

Received 30-09-2020

Accepted 28-10-2020

Available online 05-12-2020

## Keywords:

Acne vulgaris

Dyssebacia

Pellagra

Seborrhea Spinulosa

Seborrheic dermatitis

## ABSTRACT

**Background:** ‘Dyssebacia’ also termed as ‘Seborrhea Spinulosa’, is a condition presenting with numerous follicular papules, usually centered around the nasolabial area, consisting of plugs of inspissated sebum. This condition is seen frequently in cases of Pellagra, and has been quoted to be the 5<sup>th</sup> D of Pellagra. Dyssebacia is seen rampantly among cases of acne vulgaris and seborrheic dermatitis. As alcoholism leads to a state of vitamin deficiency and because of its close association with Pellagra, it also has been considered as an independent co-factor for the causation. This study thereby aims at analysing the association of acne vulgaris, seborrhea and alcohol consumption in cases clinically diagnosed as Dyssebacia.

**Materials and Methods:** We have included 25 cases of Dyssebacia in this study. After enrollment, a thorough history was taken followed by a dermatological examination with a keen interest to note the presence of, or a past history of acne vulgaris and seborrheic dermatitis. A history regarding alcohol consumption was also sought for.

**Results:** Of the 25 cases of Dyssebacia, which included 16 males (64%) and 9 females (36%), 18 cases (72%) had a history of Acne vulgaris and Seborrhea both. Majority of cases (17 of 25; 68%) were in the age-group of 18-35 years. History of alcohol consumption was obtained from 7 males (28%). A male with Pellagra also reported to our department having marked dyssebacia, photosensitive dermatitis, hyperpigmentation along the dorsal aspects of hands and feet etc.

**Conclusion:** In conclusion, it was found in our study that Acne vulgaris and Seborrheic dermatitis indeed have a strong association with Dyssebacia. Alcohol consumption does not seem add risk to the causation, except in case of chronicity.

© This is an open access article distributed under the terms of the Creative Commons Attribution License (<https://creativecommons.org/licenses/by/4.0/>) which permits unrestricted use, distribution, and reproduction in any medium, provided the original author and source are credited.

## 1. Introduction

Nasolabial Dyssebacia which has been rightly termed as Seborrhea Spinulosa or Shark skin, is a condition which presents with multiple follicular papules formed by plugs of inspissated sebum in the dilated follicular orifices.<sup>1</sup> Dyssebacia has a close association with Pellagra which is a commonly encountered nutritional dermatosis, especially in India,<sup>2</sup> due to deficiency of Niacin (Vitamin B3) typically in alcoholics. Pellagra was originally described as a disease of 3 Ds namely: Diarrhoea, Dermatitis, Dementia.<sup>1</sup> Later

on, in the course of time, ‘Death’ was added as the 4<sup>th</sup> D. But, with emerging clinical evidence, we now have reached a point in time, wherein Dyssebacia is being considered as the 5<sup>th</sup> D of Pellagra due to its overwhelming co-existence.<sup>3</sup>

We have often encountered patients of Dyssebacia with no associated photosensitivity or other Pellagroid features. These cases show remarkable concurrence with acne vulgaris and/or seborrheic dermatitis. Patients often tend to show response to Dyssebacia with ongoing treatment protocols for these two conditions. Commonly affected are the middle-aged individuals. The possibility of alcohol consumption having an additive role to the causation of Dyssebacia proper, still poses some doubt.

\* Corresponding author.

E-mail address: [dr.ashokkumar25@gmail.com](mailto:dr.ashokkumar25@gmail.com) (N. A. Kumar).

This study has thereby tried to determine the association of acne vulgaris, seborrhea and alcohol consumption with Nasolabial Dyssebacia.

## 2. Materials and Methods

The study was conducted in the Dermatology outpatient department of Sree Balaji Medical College and Hospital, Chennai, India, between November 2019 to April 2020. After prior approval from the institutional ethical committee, we commenced with the study. A detailed record was obtained from 25 cases diagnosed clinically to have Dyssebacia. A well-written, informed consent was obtained from every case before recruiting them to the study. A thorough history of their prevailing skin condition was recorded along with emphasis given on the active presence or past history of acne vulgaris and seborrhea. Alcohol consumption if present, was also noted with details pertaining to the type, quantity and frequency of liquor consumed and the duration since when they have been consuming it. All cases of Dyssebacia were diagnosed on only clinical grounds due to scarcity of data regarding the criteria for diagnosis.

## 3. Results

Of the 25 cases included in the study, 16 (64%) were males and 9 (36%) were females. Graph 1 gives male to female ratio. All the patients were above the age of 18 years, with majority of the them (68%; 17 of 25 cases) being younger than 35 years of age. Graph 2 gives an age-sex comparison of cases. Figure 1 (a and b) are clinical photographs of patients having classical Dyssebacia. A history of concurrent acne vulgaris and seborrheic dermatitis was present in 18 of 25 cases (72%), whereas only 1 case had isolated Acne vulgaris (4%) and 4 cases had isolated Seborrheic dermatitis (16%). Figure 2 (a and b) are clinical photographs of cases having Dyssebacia with acne vulgaris and seborrhea. 13 of 25 cases (52%) had a history of Dyssebacia from 6 months to 1 year. Graph 3 gives the duration of dyssebaca. Furthermore, only 7 of 25 cases (28%) gave a history of alcohol consumption and all were males. We also report of a case of Pellagra with marked Dyssebacia and other clinical findings of photosensitivity, hyperpigmentation and an associated history of chronic alcoholism. Figure 3 (a, b and c) are clinical photographs of the individual with Pellagra and associated Dyssebacia.

Of the 25 cases, 19 individuals (76%) had a non-vegetarian diet, with high fat content. Of the remaining 6 cases who consumed vegetarian food, 4 cases consumed high fat food whereas the remaining 2 consumed low-fat, high fibre and high protein containing food. The overall intensity of Dyssebacia was found to be much less in those 2 cases consuming low-fat food.

Few cases also had co-existent dermatoses which mark no significance due to lack of consistence. Alopecia areata, Scabies, Psoriasis Vulgaris, Dermatophytosis, Atopic dermatitis were present in 5 individuals respectively and they were getting treated for the same.

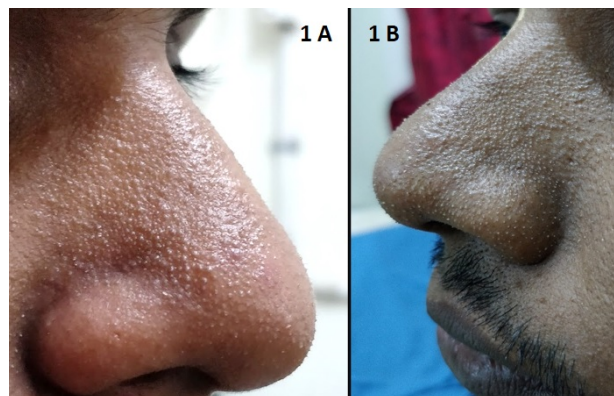

Fig. 1:

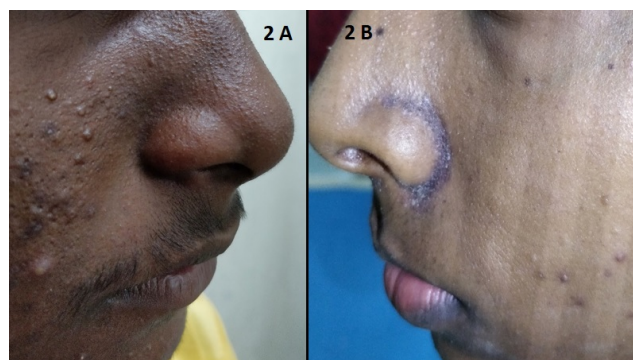

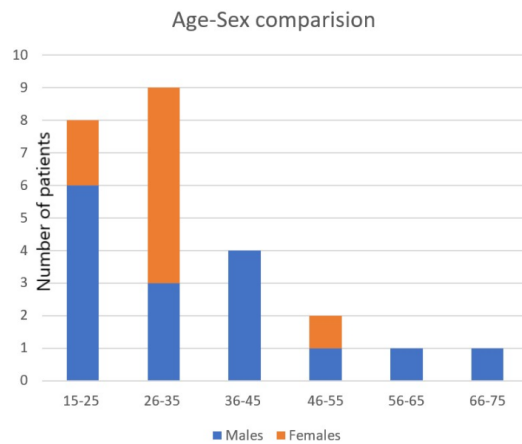
Fig. 2:

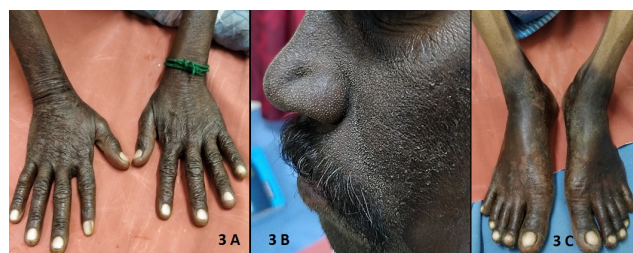

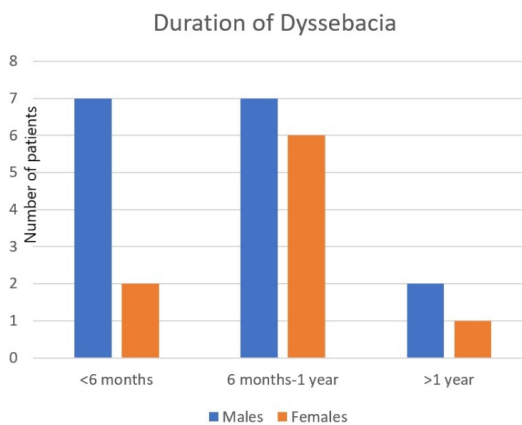
Fig. 3:

## 4. Discussion

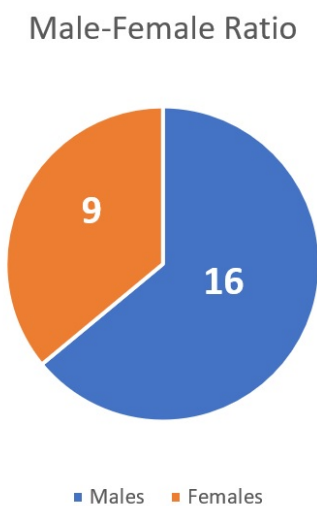
Dyssebacia bears clinical importance as it proves to be an early marker of Niacin deficiency. Pellagra which was earlier called Austrian Leprosy, almost consistently presents with Dyssebacia amongst its features. Pellagra presents



**Fig. 4:** Age-Sex comparison



**Fig. 5:** Duration of Dyssebacia



**Fig. 6:** Male-Female Ratio

with a range of cutaneous signs and symptoms like: Painful/pruritic erythema, scaling and hyperpigmentation mainly in a photo-distributed pattern, vesicles and bullae (seen uncommonly), hyperkeratotic and well-delineated plaques, involvement of the upper part of the neck (Casal's necklace), angular stomatitis, cheilitis, glossitis, mucosal ulcers and Dyssebacia. Intractable diarrhoea, mental confusion, stupor, pellagrous encephalopathy are frequently encountered.<sup>4</sup>

Niacin is a water-soluble vitamin which is obtained partly from diet and partly from endogenous synthesis from tryptophan. Niacin is required for the synthesis of NAD and NADP (Nicotinamide-adenine dinucleotide) which are components taking part in numerous metabolic reactions in our body. In those populations where corn and maize are consumed in plenty, niacin deficiency exists, as in these grains niacin is tightly bound and unless it is hydrolysed, it cannot be brought to use. Even in individuals consuming Alcoholics are prone to get Niacin deficiency primarily due to inadequate consumption. Several drugs like anti-convulsants,<sup>5</sup> sulphonamides, chloramphenicol, azathioprine<sup>6</sup> etc., have shown to cause niacin deficiency and thereby Pellagroid symptoms. Mental deterioration is quite peculiar to niacin deficiency and shows remarkable response to Nicotinamide. Pellagra has also been seen in conjunction with Inflammatory bowel disease and Carcinoid syndrome.<sup>7,8</sup>

It was first quoted by Fred HL, that Dyssebacia is the '5<sup>th</sup> D' of Pellagra. Diarrhoea, Dermatitis, Dementia and Death are known to all as the 4 Ds of the disease. Pellagra is the only known photosensitive dermatosis with death as a cardinal feature.<sup>2</sup>

In routine clinical practice, Dyssebacia is not uncommon to be encountered. Not always do we see Pellagroid features and this points us to determine other co-factors to the causation of Dyssebacia. Acne vulgaris and Seborrheic dermatitis is seen in many individuals with Dyssebacia. The middle-aged, with high sebum production seem to be the most affected. Classically, a patient presenting with Dyssebacia complaints of sebaceous outgrowths seen on the nasolabial area. A history of cheesy, yellowish material being expressed from these lesions on side-to-side pressure is very peculiar. Individuals often complain of an intensely oily skin. A majority of cases often have active lesions of acne vulgaris or seborrheic dermatitis. Nasolabial Dyssebacia with evidence of Post-Seborrhea melanosis has been commonly encountered in our study.

In a study conducted by Asifa N. et al, history of acne vulgaris or Seborrhea was found in 4 of the 12 cases of Dyssebacia. Whereas in our study, 23 of 25 cases (92%) had an associated history of either acne vulgaris or Seborrhea or both.

Seborrheic dermatitis (thereby even Dyssebacia) is seen less commonly in extremes of age, probably because of

relative lack of sebum in children and lowered activity of sebaceous glands with advancing age.<sup>9</sup> This was found consistent in our study with clustering of cases mainly in the middle-aged individuals.

Alcohol consumption is known to be a risk factor for Niacin deficiency and Pellagra.<sup>10</sup> In our study only 7 of the 25 cases consumed alcohol of which 6 cases gave a history of consuming beer twice/thrice per month. But on the other hand, we also report of a case of Pellagra who had pronounced Dyssebacia, hyperpigmentation of the dorsal parts of hands and feet, hyperpigmentation and scaling noted on the face and neck mainly in a photo-distributed pattern, presence of hyperkeratotic scales on the forehead and cheeks and systemic features like hepato-splepnomegaly. This individual gave a history of alcohol consumption since past 10 years (60 ml of hard country liquor daily). This suggests that chronic alcoholism increases the propensity to develop dyssebacia.

## 5. Conclusion

Acne vulgaris and seborrhea have a striking co-existence in cases of Dyssebacia. Alcohol consumption does not seem to be adding to the risk of developing this condition, unless taken for prolonged period of time. Patients showed improvement on treatment with topical cleansers consisting of Glycolic acid/Salicylic acid, topical and oral retinoids (Isotretinoin 10 mg once daily), Selenium sulphide shampoos etc., which were given for the treatment of acne vulgaris and seborrheic dermatitis and were not directly aimed to clear Dyssebacia per se. We wish to conclude that Nasolabial Dyssebacia, does seem to occur in acne/seborrhea prone skin. Routine dermatological therapies for clearing associated acne/seborrhea with careful counselling should work. Patients should seek a dietary advice for low-fat containing food.

## 6. Source of Funding

No financial support was received for the work within this manuscript.

## 7. Conflict of Interest

The authors declare they have no conflict of interest.

## References

1. Asifa N, Shashi ARK, and NR. Dyssebacia: An early cutaneous marker of niacin deficiency. *Int J Med and Dent Sci.* 2017;6(2):1539–42.
2. Wan P, Moat S, Anstey A. Pellagra: a review with emphasis on photosensitivity: Review of pellagra with emphasis on photosensitivity. *Br J Dermatol.* 2011;164(6):1188–2000.
3. Fred HL. Dyssebacia"-A Fifth D of Pellagra. *Pract Gastroenterol.* 2003;27(3):41–52.
4. Hegyi J, Schwartz RA, Hegyi V. Review pellagra: dermatitis, dementia, and diarrhea. *Int J Dermatol.* 2004;43(1):1–5.
5. Kaur S, Goraya JS, Thami GP, Kanwar AJ. Pellagrous Dermatitis Induced by Phenytoin. *Pediatr Dermatol.* 2002;19(1):93. doi:10.1046/j.1525-1470.2002.0024e.x.
6. Oliveira A, Sanches M, Selores M. Azathioprine-induced pellagra. *J Dermatol.* 2011;38(10):1035–7. doi:10.1111/j.1346-8138.2010.01189.x.
7. Rosmaninho A, Sanches M, Fernandes I, Pinto-Almeida T, Vilaça S, Oliveira A, et al. Pellagra as the initial presentation of Crohn disease. *Dermatol Online J.* 2012;18(4):12.
8. Bell HK, Poston GJ, Vora J, Wilson NJE. Cutaneous manifestations of the malignant carcinoid syndrome. *Br J Dermatol.* 2005;152(1):71–5. doi:10.1111/j.1365-2133.2004.06273.x.
9. Montagna W. Morphology of ageing skin: The cutaneous appendages. In: *Advances in Biology of Skin: Ageing.* vol. IV. Oxford: Pergamon Press; 1965. p. 1–16.
10. Pipili C, Cholongitas E, Ioannidou D. The diagnostic importance of photosensitivity dermatoses in chronic alcoholism: report of two cases. *Dermatol Online J.* 2008;14(11):15.

## Author biography

**Sukanya G**, Assistant Professor

**Ojas Dipak Kulkarni**, Junior Resident

**N. Ashok Kumar**, Professor

**D Manoharan**, Professor

**K Manoharan**, Professor and HOD

**Cite this article:** Sukanya G, Kulkarni OD, Kumar NA, Manoharan D, Manoharan K. An observational study to analyze the association of Acne Vulgaris, Seborrhea and Alcohol consumption in clinically diagnosed cases of Dyssebacia. *IP Indian J Clin Exp Dermatol* 2020;6(4):345-348.