



Original Research Article

Onychoscopic evaluation of various nail disorders at a Tertiary care center

Krishnendra Varma¹, Ujjwal Kumar¹, Praneeta Jain^{1,*}¹Dept. of Dermatology, Venereology and Leprology, R. D. Gardi Medical College, Ujjain, Madhya Pradesh, India

ARTICLE INFO

Article history:

Received 24-10-2020

Accepted 17-11-2020

Available online 05-12-2020

Keywords:

Dermoscopy

Longitudinal melanonychia

Nail

Nail lichen planus

Nail psoriasis

Onychomycosis

Onychoscopy

Scleroderma

ABSTRACT

Background : Nail diseases have always been a challenge for dermatologists. Because diagnosis is not always based on clinical examination and time taken for histopathology KOH or culture examination is long, there has always been a quest for easy and faster method. Onychoscopy, a rapid office-based technique helps see minuscule details, can hence aid in diagnosis.

Aim : To study dermoscopic features in various nail disorders.

Materials and Methods : 126 patients with clinically evident nail diseases were recruited in the cross-sectional descriptive study. After clinical examination, all nails were subjected to dermoscopic examination. Fischer's exact test was applied with a significance threshold of $p < 0.05$.

Results : Onychomycosis (n=49) was the commonest nail disorder having spiked pattern as the most common (91.8%) dermoscopic feature. Nail psoriasis (n=32) had onycholysis (84.4%) as the most frequent feature. Nail lichen planus (n=5) had longitudinal fissures (80%) while chronic paronychia (n=5) had erythema and scaling on the PNF (100%). Longitudinal melanonychia (n=5) was associated with regular parallel grey/ brown lines in all cases while trachyonychia had longitudinal ridges in 75% cases. Dilated capillaries (75%), microhemorrhages (75%), capillary dropouts (75%) were seen commonly in systemic sclerosis (n=4). Periungual verruca (n=4) had dermoscopic brownish black dots or globules in 100% cases. Alopecia areata (n=4) showed superficial small pits (100%) most commonly.

Conclusion : Dermoscopy helps in picking minute details not visible to the naked eye and hence could serve as an important diagnostic tool.

© This is an open access article distributed under the terms of the Creative Commons Attribution License (<https://creativecommons.org/licenses/by/4.0/>) which permits unrestricted use, distribution, and reproduction in any medium, provided the original author and source are credited.

1. Introduction

Nail diseases are approximately 10% of all the dermatological conditions.¹ Nails may be involved primarily or secondarily in either dermatologic or systemic diseases. They may also be affected without any skin involvement. Dermoscopy of the nail unit is referred to as onychoscopy. It is a noninvasive and rapid office-based technique. It was initially employed to study pigmentary abnormalities of the nail unit and for the visualization of proximal nail fold capillaries (NFC).² However, now onychoscopy has fast expanding indications and is an upcoming tool employed in the diagnosis of various

other nail pathologies. It can also be used for monitoring evolution, therapeutic response, and prognosis of the diseases. However, onychoscopy is technically difficult due to nail's size, shape, convexity, and hardness. The entire nail cannot be visualized as a whole at one particular time; therefore, it is sometimes cumbersome to take pictures of this area.

Study of nail diseases until recently was restricted to more on clinical, microbiological evaluation and less on histopathology. Diagnostic biopsy is a painful procedure. Also, reluctance of most clinicians to perform biopsies and lack of expertise among pathologists further compound the problem. Clinicopathologic tools are time-consuming and give false negative results in up to 35% of patients.³ Onychoscopy is a valuable tool to see subsurface structures,

* Corresponding author.

E-mail address: drpraneetajain@gmail.com (P. Jain).

hence, acts as a link between naked eye examination and histopathology.

2. Aim

To study dermoscopic features in various nail disorders.

3. Materials and Methods

After obtaining clearance from the Institutional Ethics Committee, this cross-sectional observational study was conducted in 126 consequent patients attending dermatology outpatient department of a tertiary care hospital over a period of 1 year, from January 2019 to December 2019. Patients with clinically detectable nail involvement were recruited for onychoscopic evaluation. Male and female patients of all age groups were included in the study while patients getting treatment for their nail diseases were excluded. After taking written consent, patients underwent a detailed history regarding onset, evolution, number of nails involved, underlying skin disease and systemic complaints. Then they were subjected to general physical examination, systemic and cutaneous examination. Relevant laboratory investigations like KOH examination, culture of nail clippings, and nail biopsy were carried out wherever necessary. All nails were then examined by a handheld dermoscope DermLite DL4 with a magnification of 10×. Higher magnification of up to 50× was used in both non polarized and polarized mode with and without interface medium (ultrasound gel). Digital photographs were taken by iPhone 6s. The findings were recorded and tabulated in master chart. The results were analyzed using statistical software SPSS v20. Fischer's exact test was applied in various categories and a p-value < 0.05 was considered statistically significant.

4. Results

Amongst the 126 patients enrolled, a mean age of 36.21 years was observed. The youngest patient was a 2-year-old while the oldest was 76 years old.

74 (58.7%) patients were males and 52 (41.3%) were females with a M:F ratio was 1.46:1.

Semi-skilled workers like factory workers, labourers, farmers, shopkeepers etc. comprised 35.7% of the total patients. Unemployed like housewives comprise 25% of the patients. Arithmetic skilled like clerks and students comprised 23% of the total patients while the least were professionals like doctors.

Many patients (48.4%) belonged to the lower class while middle class comprised 44.4% of the total patients. 77 (61.1%) patients were literate while 49 (38.9%) patients were illiterate out of the enrolled 126 cases.

A total of 697 nails were affected in 126 patients. The mean number of nails affected were 5.53 ± 5.3 .

The duration of nail diseases ranged from 1 week to 28 years with a mean of 1.5 years and a median of 6 months.

24 (19%) of the 126 patients had systemic diseases; the most observed conditions were hypertension [11(8.7%)] followed by diabetes mellitus [7(5.6%)]. 2 patients had HIV infection. 48 (38.1%) patients of the total 126 had no underlying dermatological condition. The most common skin disease encountered was psoriasis vulgaris in 26 (20.6%) patients followed by tinea infection in 15 (11.9%) patients. Palmoplantar psoriasis and lichen planus were found each in 5 (4%) patients. Lesser frequent dermatological disorders include systemic sclerosis (3.2%), verruca vulgaris (2.4%), alopecia areata (2.4%).

4.1. The common dermoscopic findings in various nail disorders are:

Onychomycosis (n=49)

Distal and lateral subungual onychomycosis (DLSO) being the commonest was seen in 40 (81.63%) patients, whereas 7 (14.28%) patients had total dystrophic onychomycosis (TDO). Proximal subungual onychomycosis (PSO) and superficial white onychomycosis (SWO) each were seen in 1 (2%) case.

Spiked pattern (91.8% vs 6.5% wherein, 91.8% stands for this dermoscopic finding in onychomycosis and 46.8% stands for this finding in other nail disorders), chromonychia (89.8% vs 19.8%), leukonychia (79.6% vs 6.5%), subungual hyperkeratosis (79.6% vs 37.6%) and distal irregular termination (79.6% vs 22%) were found to be statistically significant in onychomycosis in comparison to other nail disorders.

On statistically comparing between DLSO and TDO, none of the findings were statistically significant.

Nail psoriasis (n=32)

Statistically significant findings include onycholysis (84.38% vs 56.4%), circular punctate depressions (81.25% vs 11.7%), dented onycholysis pattern (75% vs 0%), reddish-purple streaks (71.88% vs 22.3%), subungual hyperkeratosis of the compact type (68.75% vs 4.2%), reddish onycholysis border (40.6% vs 0%), proximal nail plate scales (50% vs 26.6%).

Less common findings: ridges (18.75%), dilated proximal nail fold capillaries (12.5%), dilated hyponychial capillaries (6.25%), salmon patch seen as reddish-orange globules (9.38%).

Nail lichen planus (n=5)

Common findings: Longitudinal fissures (80%), lamellar splitting (40%), longitudinal grooves converging to center (40%), chromonychia (40%).

Chronic paronychia (n=5)

Proximal and lateral nail fold erythema (100%), proximal and lateral nail fold scale (100%), destroyed cuticle (80%), transverse brown bands (60%), chromonychia (40%).

Table 1: Distribution of patients according to their nail disorders

Condition	Frequency	Percentage
Onychomycosis	40	31.7%
Distal and lateral subungual onychomycosis	7	5.6%
Total dystrophic onychomycosis	1	0.8%
Proximal subungual onychomycosis	1	0.8%
Superficial white onychomycosis	32	25.4%
Nail Psoriasis	2	1.6%
Nail Psoriasis + DLSO	5	4%
Chronic Paronychia	5	4%
Longitudinal Melanonychia	5	4%
Nail Lichen Planus	4	3.2%
Trachyonychia	4	3.2%
Nail Pitting (Alopecia areata)	4	3.2%
Nails in Systemic sclerosis	4	3.2%
Peri/subungual verruca	2	1.6%
Eczema	2	1.6%
Habit tic deformity	1	0.8%
Nails in Discoid Lupus Erythematosus	1	0.8%
Pterygium inversus unguis	1	0.8%
Subungual hematoma	1	0.8%
Nails in Ectodermal dysplasia	1	0.8%
Nails in Systemic Lupus Erythematosus	1	0.8%
Pyogenic Granuloma	1	0.8%
Nails in Pityriasis Rubra Pilaris	1	0.8%
Nail in Porokeratosis of Mibelli	1	0.8%
Total	126	100%

Table 2: Dermoscopic patterns in distal lateral subungual onychomycosis (DLSO) and total dystrophic onycholysis (TDO)

Dermoscopic findings	DLSO		TDO	
	Frequency (n=40)	Percentage	Frequency (n=7)	Percentage
Onycholysis	37	92.5	7	100
Chromonychia	36	90	7	100
Subungual hyperkeratosis	33	82.5	6	85.7
Ruinous pattern	33	82.5	6	85.7
Leukonychia	31	77.5	6	85.7
Distal irregular termination	31	77.5	6	85.7
Spiked pattern	27	67.5	3	42.9
White fluffy shadows	17	42.5	3	42.9
Lamellar micro-splitting	13	32.5	3	42.9
Longitudinal striae	10	25	3	42.9
Transverse striae	1	2.5	0	0

Longitudinal melanonychia (n=5)

Regular parallel grey/ brown lines (100%), nail plate background of grey/brown color (40%).

Systemic sclerosis (n=4)

Dilated capillaries (75%), microhemorrhages (75%), capillary dropouts (75%), avascular areas (75%), ragged cuticle (75%), giant capillaries (50%).

Trachyonychia (n=4)

Rough surface (100%), longitudinal ridges (75%), superficial circular punctate depressions (25%).

Periungual verrucae (n=4)

Brownish black dots or globules (100%), brownish black streaks (50%), onycholysis (50%), hyperkeratotic mass seen

beneath nail plate (50%).

Alopecia areata (n=4)

Superficial small circular punctate depressions (100%), regular distribution (25%).

5. Discussion

According to the results obtained in our study, nail diseases were most encountered in the fourth decade [32(25.4%)], followed by third decade [30(23.8%)]. This could be attributed to an increased physical activity and a greater concern among the adults of these age groups and their approachable tendency for health care. This was concordant

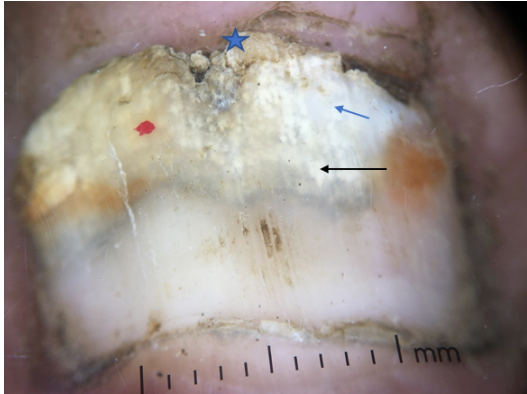


Fig. 1: Distal lateral subungual onychomycosis: Distal onycholysis with a typical spiked pattern and a jagged proximal edge (black arrow). Distal nail plate shows irregular termination (star). Onycholytic area shows white fluffy shadows (blue arrow).

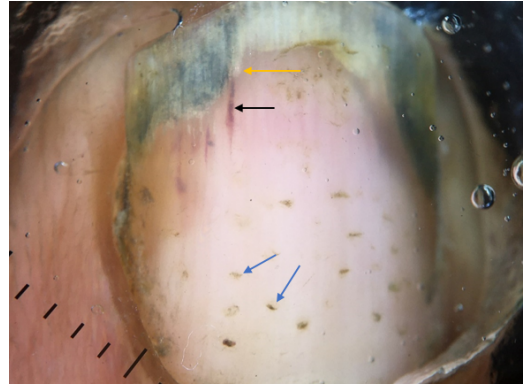


Fig. 4: Nail psoriasis: Splinterhaemorrhage- reddish purple longitudinal streaks present on distal nail plate (black arrow). Pits seen as circular punctate depression random in distribution (blue arrows). Dented border of onycholysis (yellow arrow)

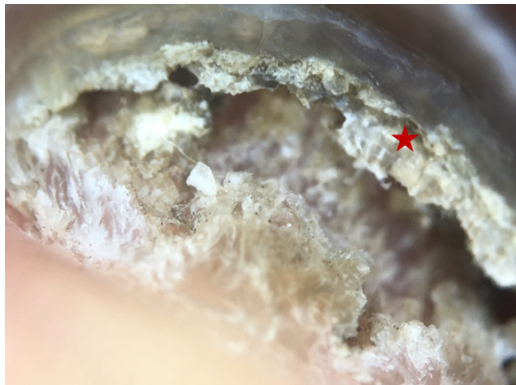

Fig. 2: Total dystrophic onychomycosis: Ruinous aspect of subungual hyperkeratosis with distal irregular termination (star)

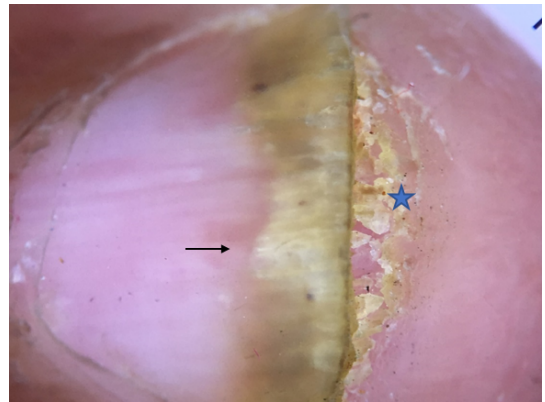


Fig. 5: Nail psoriasis: Proximal reddish border of onycholysis (black arrow). Subungual hyperkeratosis (blue star).

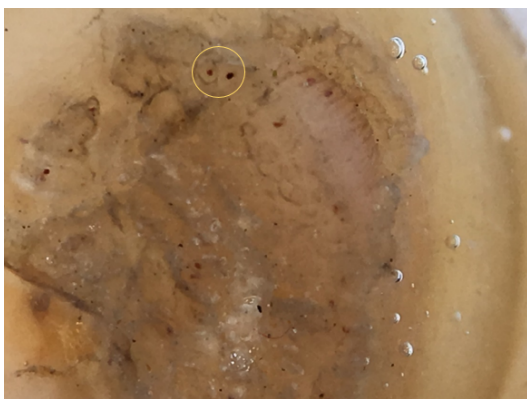


Fig. 3: Subungual verruca: Hyperkeratotic structure with numerous punctate capillaries (yellow circle).

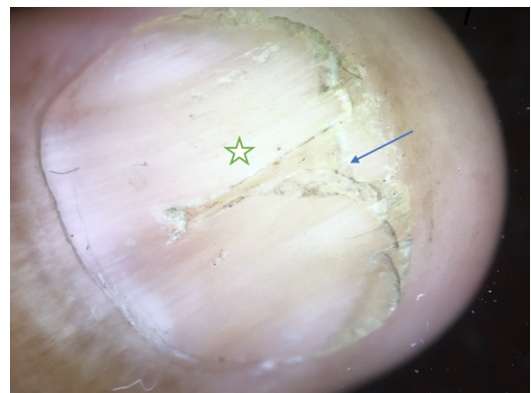


Fig. 6: Nail lichenplanus: Multiple longitudinal fissures (star) seen and distal splitting of nail plate (blue arrow) with nail plate thinning




Fig. 7: Longitudinal melanonychia: Multiple longitudinal parallel regular brownish bands seen with no PNF pigmentation

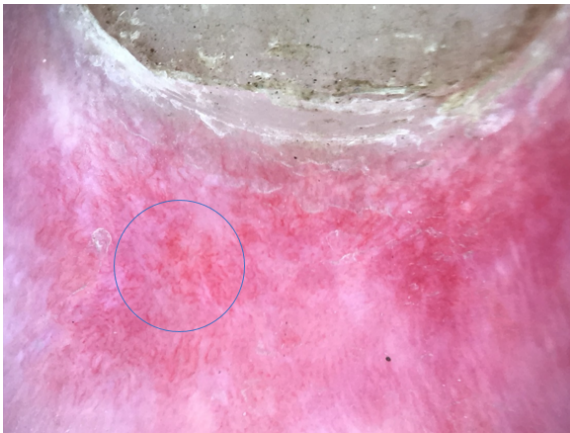

Fig. 8: Nail fold capillaroscopy in disseminated DLE: normal architecture of nail fold capillaries is lost. Multiple bushy and bizarre capillaries seen suggestive of neoangiogenesis (circle).

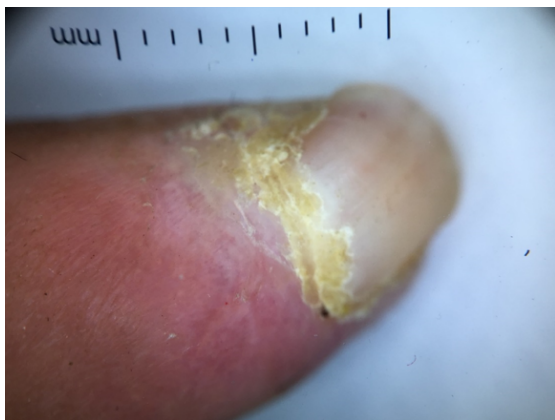

Fig. 9: Systemic sclerosis: Micromonychia with parrot beak shaped nail and ragged cuticle.

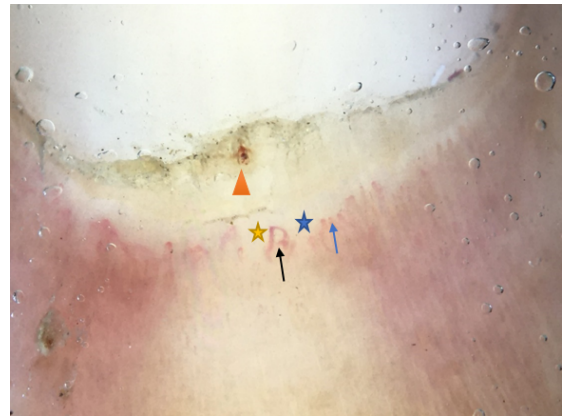


Fig. 10: Active pattern of systemic sclerosis: Many dilated (blue arrow) and giant capillaries (black arrow) with capillary dropouts (blue star), avascular areas (yellow star) and microhaemorrhage (triangle).

with the study done by Puri et al.⁴ where majority [200(40%)] belonged to the third and fourth decade, followed by fifth and sixth decade [150(30%)] and with the study done by Rathod et al.³ where the most common age group was fourth decade [49(19.6%)] followed by second decade [47(18.8%)].

In our study, there was a male preponderance [M:F = 1.46:1] which was similar to the findings of other Indian studies by Puri et al.⁴, Rathod et al.³ and Bhat YJ et al.⁵ This could be because of better accessibility of males to health care facilities.

A bulk [89(79.6%)] of patients belonged to rural areas in our study which was comparable to the study by Bhat YJ et al.⁵ where 151 (63.71%) patients belonged to rural areas. Place of study mainly serving the rural population could explain the dominance of rural patients in the study.

A higher incidence of nail disorders was found amongst semi-skilled workers [45(35.7)]. Also, housewives [32(25.4%)] and maids had a higher incidence of fungal nail infection and chronic paronychia owing to their frequent contact with water and detergents. Similar findings were observed in a study by Rathod et al.³ where they found a prevalence of chronic paronychia in 15.4%, nail changes due to pitted keratolysis in 15.4% and DLSSO in 11.1% patients who were housewives or domestic helps. Students comprised 21.4% (27) of the total patients in our study. This could be ascribed to an increased awareness amongst them. Similar findings were reported by Rathod et al.³ and Puri et al.⁴ where the incidence in students was 23.2% and 12% respectively.

Fingernails outnumbered toenails as they were exclusively involved in 78 (61.9%) and 13 (10.3%) patients, respectively. Both fingernails and toenails were involved in 35 (27.8%) patients. Fingernails being more cosmetically concerning could have led to a higher medical

approach. In a study by Rathod et al.³, fingernails were significantly ($p=0.000$) more commonly involved than toenails and right hand fingernails were most frequently involved in 192 patients (78.6%) followed by left hand fingernails [171(68.4%)], right foot toenails [109(43.6%)] and left foot toenails [102(40.8%)].

Number of nails involvement was found to be statistically significant ($p=0.001$) with 1-5 nails being most frequently involved in 83 (65.9%) patients followed by 6-10 nails involvement in 30 (23.8%) patients. 16-20 nails were involved in 11 (8.7%) patients. Similar findings were noted by Kumar et al.⁶ with 1-5 nails being most involved in 133 (49.4%) followed by 6-10 nails in 114 (42.4%) cases. However, Puri et al.⁴ observed that 6-10 nails were most affected [190(38%)] followed by 1-5 nails in 175 (35%) patients.

The mean duration of disease observed was 1.5 years. 56% patients had a duration between 1 month and 1 year in a comparable study by Rathod et al.³ The duration of disease was quite variable owing to the asymptomatic nature of nail disorders.

Onychomycosis was the most common nail disorder observed in our study and this was concordant with Puri et al.⁴, Bhat YJ et al.⁵ and Kumar et al.⁶ with 25%, 34.18% and 34.2% prevalence respectively, while Rathod et al.³ found onychomycosis as the second most common disorder after nail psoriasis.

Fingernails outnumbered toenails in our study, as opposed to the findings in literature. In the present study, onycholysis was the most common finding present in 44 (89.8%) cases. Onychoscopy had the distinct advantage of demarcating the proximal edge of the onycholytic area. Linear onycholytic edge was commonly seen in traumatic onycholysis while a jagged edge characterized onychomycosis.⁷ A spiked pattern with jagged edge was noted in 30 (61.2%) cases, while others [19(38.8%)] had a linear edge. The association of spiked pattern with onychomycosis was found to be statistically significant ($p<0.05$). This finding was concordant with previous studies conducted by Yadav and Khopkar (100%),⁸ Piraccini et al. (100%),⁹ Jesús-Silva et al. (23.8%)¹⁰ and Nargis et al. (78.3%).¹¹

We observed chromonychia of the nail plate to be statistically significant ($p<0.05$). It was seen in 43 (87.8%) cases, most frequently being yellow (42.9%) followed by brown (16.3%), multicolour or the 'aurora borealis pattern' (12.3%), black (6.1%) and green (6.1%). In a study by Piraccini BM et al., a similar pattern of chromonychia (yellow>brown>black: 70%>51%>24%) has been described.⁹ They also described white chromonychia in 59% cases, a statistically significant finding in diagnosing onychomycosis. Similar findings were also noted by Kayarkatte MN et al.¹²

In the present study, leukonychia was studied independently and was found to be statistically significant for diagnosing onychomycosis. White fluffy shadows were found 40.8% patients followed by longitudinal striae in 28.6% patients. Morphological types of leukonychia were first described by Kayarkatte MN et al.¹² where they found white fluffy shadows in 63.6% patients. However, to diagnose onychomycosis, no statistically significant relation was observed with these morphological types.

Subungual hyperkeratosis was observed in 39 (79.6%) cases, of which all of them [39(100%)] showed ruins aspect/ruinous appearance. The association of subungual hyperkeratosis, as well as ruinous appearance with onychomycosis, was found to be statistically significant ($P < 0.05$). Concordant findings were noted in all 10 nails of onychomycosis studied by De Crignis et al.¹³, while Kayarkatte MN et al.¹² noted subungual hyperkeratosis in 75 (85.2%) cases, of which 52 (59.1%) showed ruins aspect/ruinous appearance.

Distal irregular termination of the nail plate was observed in 39 (79.6%) cases, with a significant association with onychomycosis ($P < 0.05$). This concurred with the findings of Kayarkatte MN et al.¹² Fine irregular transverse splitting, dermoscopically appreciated as lamellar micro-splitting of the nail plate was observed in 16 (32.6%) of cases. Kayarkatte MN et al.¹² found lamellar micro-splitting in 51.1% patients.

In nail psoriasis, the most common observation in our study was onycholysis (84.4%) followed by pits (81.3%), splinter hemorrhages (71.9%) and subungual hyperkeratosis (68.8%). However, pits were the commonest findings in studies by Rathod et al.(64.5%),³ Bhat YJ et al.⁵ (85.71%) and Wanniang et al.(84%)¹⁴ while splinter haemorrhage was the commonest in the study by Yorulmaz et al.(73.1%).¹⁵

Depending on the part of nail unit involvement, nail psoriasis had a myriad of clinical and dermoscopic manifestations. Nail changes also positively correlated with the severity of disease and presence of arthritis.¹⁶ Psoriatic onycholysis was dermoscopically seen as whitish onycholytic area distally with a proximal characteristic reddish border (40.63%) which was not always visible to the naked eye. The onycholytic edge was dented in 75% while linear in others. Pits were dermoscopically seen as deep punctate depressions, random in distribution and surrounded by whitish halo. The psoriatic pits were randomly distributed and were irregular in size and shape. Splinter haemorrhages were perceived as brownish-purple longitudinal streaks when old and bright red streaks when fresh seen commonly on the distal part of nail plate. They result from rupture of capillaries underneath the nail plate in the grooves. Subungual hyperkeratosis was regarded as non-ruinous aspect (non-destructive or compact) as opposed to onychomycosis. Nail plate scales (50%) were noticed in the

proximal part of nail plate as whitish irregular scales which were not commented upon in detail in any other studies. In a study by Iorizzo et al.¹⁷, hyponychial capillaries were witnessed as dilated, tortuous and with an irregular distribution in all the cases [30(100%)].¹⁷ Proximal nail fold showed alterations in capillary architecture with coiled and drop out vessels. Capillaries along the onychodermal band were commonly found to be dilated and surrounded by a whitish halo (6.3%), which was discordant in the study by Yorulmaz et al. (64.2%).¹⁵ Pseudo-fiber sign corresponded to arterial and venous ends of capillaries seen in 34.3% cases in a study by Yorulmaz et al.¹⁵ However, we failed to observe pseudo-fiber sign owing to the less magnification provided by our dermoscope. Salmon spots, also known as 'oil drop sign' (9.3%) were seen as dull red to orange-red globules in the nail plate while Bhat YJ et al.⁵ and Polat et al.¹⁸ observed salmon spots in 42.9% and 47.5% cases.

The onychoscopic abnormalities demonstrated in nail lichen planus were of nail matrix, bed and paronychia origin.¹⁹ In our study, longitudinal fissures, lamellar splitting, pterygium and chromonychia were the most frequent findings each accounting in 40% of patients. These findings were concordant with Rathod et al.³ (64.3%) and Bhat YJ et al.⁵ (88.9%) where longitudinal fissures were the most common findings. However, Nakamura et al.¹⁹ and Bhat YJ et al.⁵ noted longitudinal streaks as the most frequent finding. Pterygium was dermoscopically appreciated as longitudinal grooves converging to center. It was seen in 2 (40%) patients, while other studies noted a slightly less percentage. Such pterygia suggest aggressive nature of the disease and possibly a poor response to therapy.¹⁹ These could help decide whether or not to initiate aggressive therapy. Anonychia occurred due to destruction of nail matrix was not found in our study, while was seen in 1.3% cases of Nakamura et al.¹⁹ and 44.4% patients of Bhat YJ et al.⁵

Chronic paronychia is an inflammatory dermatosis affecting nail folds primarily, seen as reddish swelling and white scales on dermoscopy (100%). Irritants like detergents, caustics, candidal infection cause destruction of cuticle and its dermoscopically seen as absent cuticle (80%). Secondary nail matrix involvement causes Beau's lines seen as transverse brown bands (60%) and brownish discoloration of nail plate (40%). Rathod et al.³ found transverse brown bands (87.5%) and brown colour (66.7%) to be statistically significant.

5 (3.9%) patients showed longitudinal melanonychia exclusively, one amongst them had nail discoloration in all 20 nails. Melanonychia can be because of either melanocytic activation or proliferation, thereby producing grey or brown-black bands respectively. When a malignant cause is suspected, irregular dark pigment bands are seen dermoscopically along with pigmentation on cuticle or periungual areas (Hutchinson's sign). Pigmentation of upper

free edge of distal nail plate shows origin at proximal matrix while if in the lower portion shows origin at distal matrix.²⁰

Regular, parallel, uniformly spaced longitudinal grey (40%) and brown (60%) lines were seen in this study. 40% patients had a background grey/brown discoloration, and none showed pigmentation on proximal nail fold or cuticle. Brown lines were seen in nail matrix nevus, which was later proven histopathologically. Grey lines in all 20 nails were seen as a result of zidovudine in one patient, while were physiologic in other. Similar findings were observed by Rathod et al.³ None of our patients showed positive Hutchinson's sign.

Connective tissue disorders were seen in 6 (4.8%) of the total 126 patients of which 4 (3.2%) had systemic sclerosis, 1 (0.8%) had systemic lupus erythematosus and 1 (0.8%) had disseminated discoid lupus erythematosus. Proximal nail fold changes were commonly seen in connective tissue disorders which remained undetected by unaided eye, but on dermoscopy capillary loops and haemorrhage could be detected easily.

In our study, apart from micromonychia and parrot beak nail, the capillaroscopic findings observed in systemic sclerosis were dilated capillaries, microhemorrhages, capillary dropouts, avascular areas, and ragged cuticle, each in 3 (75%) patients. The common findings in systemic sclerosis observed by Chojer et al. (n=16) were avascular areas (81.25%), bizarre capillaries (81.25%), capillary dropouts (75%) and dilated capillaries (68.75%).²¹ Similar frequency of nail fold capillaroscopy changes had been reported by Maricq et al.²² and Bergman et al.²³

The common findings in lupus erythematosus were dilated capillaries, microhemorrhages and ragged cuticle noted in both the patients. Chojer et al. (n=11) also noted dilated capillaries in 72.7% patients followed by microhemorrhages in 36.4% patients.²¹ Hyponychial capillary patterns were altered in the patient of discoid lupus erythematosus. Hyponychial capillary patterns were not commented upon by Chojer et al.²¹

Periungual or subungual verrucae were seen in 4 (3.2%) patients. Dermoscopy showed brownish black dots or globules which were seen in all the patients followed by brownish black streaks, onycholysis and hyperkeratotic mass seen beneath nail plate, each in 2 (50%) patients. These black dot/globules/streaks represented dilated capillaries in papillary dermis. Hyperkeratotic mass attributed to abnormal growth of cells thereby causing abnormalities in nail plate and detached from nail bed. Rathod et al.³ noted multiple blackish-brown dot/globules/streaks in 100% (n=22) cases followed by onycholysis in 50% cases. Similar findings were noted by Piraccini et al.²⁴

Dermoscopic examination of trachyonychia (n=4) revealed rough surface in all the patients (100%) which was followed by longitudinal ridges in 75% cases and

pits in 25% cases. Longitudinal ridges corresponded to onychorrhexis. Similarly, Rathod et al.³ found longitudinal fissures in 100% cases which was followed by white dots and streaks in 80% cases.

In our study, we encountered 4 patients of alopecia areata exclusively showed superficial, multiple circular punctate depressions corresponding to pits in all the 4 cases. 3(75%) of them had a random distribution and 1(25%) had a regular geometric distribution, characteristically known as the “Scotch plaid appearance.” Similar findings were noted by Rathod et al.³ where 75% cases showed pits while 50% cases showed longitudinal fissures.

6. Limitations

The sample size in our study was too small to use onychoscopy as the diagnostic modality solely and thus more studies with larger sample size are required to validate these findings. It provides new criteria for diagnosis, hence in patients with diagnostic dilemma histopathological examination becomes mandatory.

With the advent of better dermoscopes with higher magnifications (up to 100X), proximal nail fold capillaries could be better seen. Ours provided a magnification of 10X, hence they were not appreciated well.

7. Conclusion

Onychoscopy is an easy, non-invasive, fast and a cost-effective diagnostic tool that can allow detection of subtle nail changes not visible to the naked eye. It assists in diagnosis of nail disorders earlier so that they can be treated even before the disease progresses. In addition, it can help in differentiating benign lesions from malignant ones and helps us in avoiding unnecessary and painful nail biopsies. It also has an advantage of monitoring the progression of disease. However, the interpreter needs to have a thorough knowledge of the nail anatomy and its disorders. Hence, it is recommended to regularly incorporate nail dermoscopy in routine nail examination.

8. Source of Funding

No financial support was received for the work within this manuscript.

9. Conflict of Interest

The authors declare they have no conflict of interest.

References

- Berker DARD, Baran R, Dawber RPR. Disorders of nails. In: T B, S B, N C, C G, editors. Rook's textbook of dermatology. vol. 62. Oxford: Blackwell Science; 2004. p. 62–3.
- Tosti A, Argenziano G. Dermoscopy Allows Better Management of Nail Pigmentation. *Arch Dermatol*. 2002;138(10):1369–70. doi:10.1001/archderm.138.10.1369.
- Chatterjee M, Neema S, Rathod D, Makhecha MB, Singh T. A Cross-sectional Descriptive Study of Dermoscopy in various Nail Diseases at a Tertiary Care Center. *Int J Dermoscopy*. 2017;1(1):11–9. doi:10.5005/jp-journals-10061-0003.
- Puri N, Kaur T. A study of nail changes in various dermatosis in Punjab, India. *Our Dermatology Online*. 2012;3(3):164–70. doi:10.7241/ourd.20123.38.
- Bhat YJ, Mir MA, Keen A, Hassan I. Onychoscopy: an observational study in 237 patients from the Kashmir Valley of North India. *Dermatol Pract Concept*. 2018;8(4):283–91.
- Kumar U, Varma K, Shayalwar A. Nail changes in various dermatoses: an observational study conducted at tertiary care center, Ujjain, Madhya Pradesh, India. *Int J Res Dermatol*. 2020;6(2):237–43. doi:10.18203/issn.2455-4529.intjresdermatol20200603.
- Piraccini BM, Alessandrini A, Starace M. Onychoscopy: Dermoscopy of the Nails. *Dermatol Clin*. 2018;36:431–8.
- Yadav T, Khopkar U. White streaks: Dermoscopic sign of distal lateral subungual onychomycosis. *Indian J Dermatol*. 2016;61(1):123. doi:10.4103/0019-5154.174151.
- Piraccini BM, Balestri R, Starace M, Rech G. Nail digital dermoscopy (onychoscopy) in the diagnosis of onychomycosis. *J Eur Acad Dermatol Venereol*. 2013;27:509–13.
- Jesús-Silva MA, Martínez F, Roldán-Marín R, Arenas R, R. Dermoscopic patterns in patients with a clinical diagnosis of onychomycosis—results of a prospective study including data of potassium hydroxide (KOH) and culture examination. *Dermatol Pract Concept*. 2015;5(2):5.
- Nargis T, Pinto M, Shenoy MM, Hegde S. Dermoscopic features of distal lateral subungual onychomycosis. *Indian Dermatol Online J*. 2018;9:16–25.
- Singal A, Kayarkatte MN, Pandhi D, Das S, Sharma S. Nail dermoscopy (onychoscopy) findings in the diagnosis of primary onychomycosis: A cross-sectional study. *Indian J Dermatol, Venereol Leprol*. 2020;86(4):341–9. doi:10.4103/ijdv.ijdv1_100_19.
- Crignis GD, Valgas N, Rezende P, Leverone A, Nakamura R. Dermatoscopy of onychomycosis. *Int J Dermatol*. 2014;53(2):e97–9. doi:10.1111/ijd.12104.
- Wanniang N, Navya A, Pai V, Ghodge R. Comparative Study of Clinical and Dermoscopic Features in Nail Psoriasis. *Indian Dermatol Online J*. 2020;11(1):35–40.
- Yorulmaz A, Artuz F. A study of dermoscopic features of nail psoriasis. *Adv Dermatol Allergol*. 2017;1(1):28–35. doi:10.5114/ada.2017.65618.
- Asfiya A, Shanavaz AA, Shenoy M, Shenoy M, B V, et al. B V. Utility of dermoscopy in nail psoriasis: Its correlation with the Nail Psoriasis Severity Index (NAPSI) and psoriatic arthritis. *IP Indian J Clin Exp Dermatol*. 2019;5(2):121–6. doi:10.18231/ij.ijced.2019.026.
- Iorizzo M, Dahdah M, Vincenzi C, Tosti A. Videodermoscopy of the hyponychium in nail bed psoriasis. *J Am Academy Dermatol*. 2008;58(4):714–5. doi:10.1016/j.jaad.2007.11.026.
- Polat A, Kapicioğlu Y. Dermoscopic findings of psoriatic nail and their relationship with disease severity. *Turkderm*. 2017;51(4):119–23. doi:10.4274/turkderm.54289.
- Nakamura R, Broce AAA, Palencia DPC, Ortiz NIA, Leverone A. Dermatoscopy of nail lichen planus. *Int J Dermatol*. 2013;52(6):684–7. doi:10.1111/j.1365-4632.2011.05283.x.
- Tosti A, Piraccini BM, de Farias DC. Dealing with Melanonychia. *Semin Cutan Med Surg*. 2009;28(1):49–54. doi:10.1016/j.sder.2008.12.004.
- Chojer P, Mahajan BB. Nail fold dermoscopy in collagen vascular disorders: A cross-sectional study. *Indian J Dermatol, Venereol Leprol*. 2019;85(4):439. doi:10.4103/ijdv.ijdv1_495_18.
- Maricq HR. Widefield capillary microscopy. technique and rating scale for abnormalities seen in scleroderma and related disorders. *Arthritis Rheum*. 1981;24(9):1159–65. doi:10.1002/art.1780240907.
- Bergman R, Sharony L, Schapira D, Nahir MA, Balbir-Gurman A. The Handheld Dermatoscope as a Nail-Fold Capillaroscopic Instrument. *Arch Dermatol*. 2003;139(8):1027–30. doi:10.1001/archderm.139.8.1027.

24. Piraccini BM, Bruni F, Starace M. Dermoscopy of non-skin cancer nail disorders. *Dermatol Ther.* 2012;25(6):594–602. doi:10.1111/j.1529-8019.2012.01521.x.

Ujjwal Kumar, Associate Professor

Praneeta Jain, Resident

Author biography

Krishnendra Varma, Professor and Head

Cite this article: Varma K, Kumar U, Jain P. Onychoscopic evaluation of various nail disorders at a Tertiary care center. *IP Indian J Clin Exp Dermatol* 2020;6(4):382-390.