



Case Report

Trichoadenoma of vulva: A rare case with rare site of presentation

Haradanahalli Nagaraju Pavithra^{1,*}, Ranjeev Bhagat¹, Mala Bhalla²

¹Dept. of Pathology, Govt. Medical College and Hospital, Chandigarh, India

²Dept. of Dermatology and Venereology, Govt. Medical College and Hospital, Chandigarh, India



ARTICLE INFO

Article history:

Received 13-10-2020

Accepted 02-01-2021

Available online 22-02-2021

Keywords:

adnexal tumor

hair follicle differentiation

trichoadenoma

ABSTRACT

Trichoadenoma is a rare benign adnexal tumor of skin with differentiation towards hair structure. It was first described by Niklowski in 1958 and so is also known as trichoadenoma of Nikolowski. It shares its features with trichoepithelioma and trichofolliculoma, which are the other common benign adnexal tumors with differentiation towards hair structure. Vulva being an unusual site for occurrence of trichoadenoma, there are very few cases reported in the literature at this site. Here we report a case of trichoadenoma of vulva.

© This is an open access article distributed under the terms of the Creative Commons Attribution License (<https://creativecommons.org/licenses/by/4.0/>) which permits unrestricted use, distribution, and reproduction in any medium, provided the original author and source are credited.

1. Case History

A 47-year-old female presented with a well-defined skin colored non-tender asymptomatic nodule of 1x1cm over the vulva for almost one year. There was no history of any sexually transmitted disease. General physical examination was within normal limits and there was no inguinal lymphadenopathy. Haematological and biochemical investigations were within normal limits. Serological tests for syphilis and HIV were non reactive. The clinical possibilities considered were inclusion cyst and skin tag. The nodule was excised and sent for histopathology. (Figure 1)

The sample was processed for routine histopathological examination. The hematoxylin and eosin stained sections were examined under light microscopy. The epidermis was relatively unremarkable. Dermis shows numerous horn cysts lined by multiple layers of eosinophilic cells. There was attempted gland formation at places. Some of the cysts were dilated. Few islands of eosinophilic cells without keratinization are seen. Occasional cysts showed presence of granular layer between the keratin and eosinophilic cells. One of the cysts ruptured eliciting lymphohistiocytic

reaction in the surrounding area. (Figure 2) There were no basaloid cells surrounding the eosinophilic cells. There were no hair shafts.

2. Discussion

Adnexal tumors of skin are an interesting and complex entity in dermatopathology. It is important to differentiate the adnexal tumors as benign and malignant and also differentiate them from the epidermal and epithelial tumors. Hair follicle and its pilosebaceous unit are adnexal structures with different group of tumors. This group comprises of various tumors with differentiation towards hair structure. Trichoadenoma is one among them which is also known as trichoadenoma of Nikolowski.¹⁻⁴

Its common presentation is on face and buttocks in adults with more than 50% cases occurring over the face. Other common sites are thigh, shoulder and neck.^{3,5}

Trichoadenoma commonly presents as a skin colored lesion. The histopathology will be similar to that of our case. In addition, rare islands may show granular layer with keratohyaline granules.¹⁻³

Absence of basaloid cells around the eosinophilic cells differentiates it from the trichoepithelioma and absence of hair shaft differentiates it from trichofolliculoma.

* Corresponding author.

E-mail address: drpavithrahn@gmail.com (H. N. Pavithra).

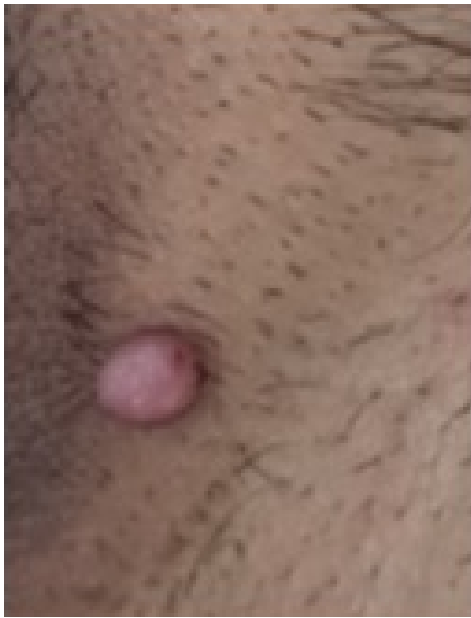

Fig. 1: Skin colored nodule of 1x1cm over the vulva

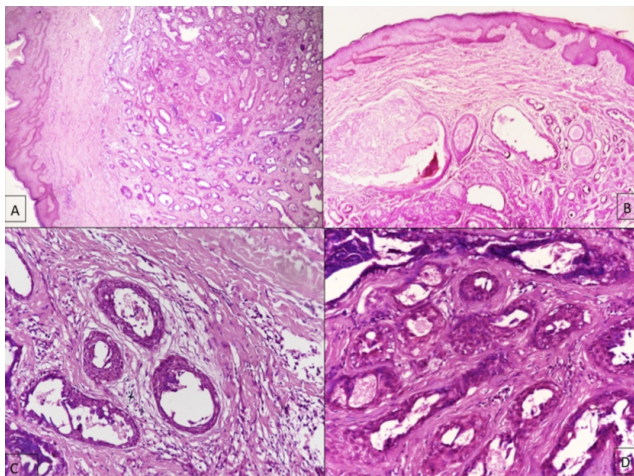


Fig. 2: Photomicrographs H&E stain sections of trichoadenoma. [A] 4X objective: normal epidermis, islands of eosinophilic cells without keratinization in dermis. [B] 10x objective: horn cysts with layers of eosinophilic cells. [C] and [D]. 20x objective: of the same.

Trichoblastoma is another benign adnexal tumor with differentiation towards hair structure composed of islands of basaloid cells without connection with the overlying epidermis. Trichoadenoma, at times may be difficult to differentiate from keratotic basal cell carcinoma in exceptional cases. A careful and thorough microscopic examination of the tissue should help differentiate them.

3. Source of Funding

No financial support was received for the work within this manuscript.

4. Conflict of Interest

The authors declare they have no conflict of interest.

References

1. Stewart CL, Novoa RA, Seykora JT. Tumors of epidermal appendages. In: Elder DE, Elenitsas R, Rosenbach M, Murphy G, Rubin A, editors. *Lever's histopathology of the skin*. 11th Edn. Philadelphia: Wolters Kluwer; 2015. p. 2012–182.
2. Swaroop DSK, Ramakrishna BA, Bai SJ, Shanthi V. Trichoadenoma of Nikolowski. *Indian J Pathol Microbiol*. 2008;51(2):277–9. doi:10.4103/0377-4929.41695.
3. Sangwaiya A, Bairwa S, Kalhan S, Sharma P, Satarkar RN. Trichoadenoma of Nikolowski - A rare tumour with unusual presentation over vulva. *J Clin Diagn Res*. 2017;11(1):5–6.
4. Undeutsch W, Rassner G. Trichoadenoma (Nikolowski). A clinical and histologic case report. *Hautarzt*. 1984;35(12):650–2.
5. Shimanovich I, Krahl D, Rose C. Trichoadenoma of Nikolowski is a distinct neoplasm within the spectrum of follicular tumors. *J Am Acad Dermatol*. 2010;62(2):277–83. doi:10.1016/j.jaad.2009.06.086.

Author biography

Haradanahalli Nagaraju Pavithra, Demonstrator

Ranjeev Bhagat, Associate Professor

Mala Bhalla, Professor

Cite this article: Pavithra HN, Bhagat R, Bhalla M. Trichoadenoma of vulva: A rare case with rare site of presentation. *IP Indian J Clin Exp Dermatol* 2021;7(1):84-85.