



## Case Report

# PRP therapy in chronic diffuse alopecia areata – A case report

Sheilly Kapoor<sup>1</sup>, Kashish Tyagi<sup>1,\*</sup>, Ishani Mohapatra<sup>2</sup>, Komal Sharma<sup>1</sup>

<sup>1</sup>Dept. of Dermatolgy, Medanta -The Medicity, Gurugram, Haryana, India

<sup>2</sup>Dept. of Pathology, Medanta -The Medicity, Gurugram, Haryana, India



### ARTICLE INFO

#### Article history:

Received 02-07-2021

Accepted 02-09-2021

Available online 11-12-2021

#### Keywords:

Platelet rich plasma therapy.

### ABSTRACT

**Introduction:** Alopecia areata, an auto-immune disorder characterised by the appearance of non-scarring bald patches affecting the hair bearing areas of the body, it can be extremely difficult to treat and has a poor prognosis despite many therapeutic options. Platelet Rich Plasma (PRP) has been previously used to treat variety of alopecia including alopecia areata.

**Summary:** A 21-year old girl presented with asymptomatic loss of hair from the scalp for the last more than two years. On examination, there was diffuse loss of hair all over the scalp with few small, thin light-coloured hair in the occipital region. Histopathological examination showed miniaturised hair follicles surrounded by variable inflammatory lymphohistiocytic infiltrate with a marked reduction in terminal-vellus hair ratio to 1:1. The response to previous treatments was poor at the end of 1 year. A trial of PRP was given with no adjuvant treatment with a total of eight sessions of PRP.

**Results:** Dramatic response was noted after 2 sessions in the form of improvement in hair diameter and total volume. Resistant areas also started showing hair growth.

**Discussion:** There are a few studies assessing the role of PRP therapy in AA. First report to establish the efficacy of PRP as a treatment modality in AA, showed PRP therapy to be superior to TCA and Placebo in growing pigmented hair in AA patches. A case report with ophiasis type AA resistant to intralesional steroid injections showed excellent response to PRP therapy. Previous studies have demonstrated beneficial role of PRP therapy in cases of patchy alopecia areata, in contrast ours was a case of chronic diffuse AA. In spite of many treatment modalities tried for more than a year, the response was unsatisfactory. PRP therapy yielded amazing results in the form of hair growth over resistant areas and overall increase in pigmented hair which were sustained at one and a half year follow up. Our case was unique in the way that excellent response to PRP treatment was noted (a) In a case of diffuse alopecia areata. (b) In a case non-responsive to standard modalities. (c) In a case with no other supportive treatment.

This is an Open Access (OA) journal, and articles are distributed under the terms of the [Creative Commons Attribution-NonCommercial-ShareAlike 4.0 License](https://creativecommons.org/licenses/by-nc-sa/4.0/), which allows others to remix, tweak, and build upon the work non-commercially, as long as appropriate credit is given and the new creations are licensed under the identical terms.

For reprints contact: [reprint@ipinnovative.com](mailto:reprint@ipinnovative.com)

## 1. Introduction

Alopecia areata (AA) is an auto-immune disorder characterized by the appearance of non-scarring bald patches affecting the hair bearing areas of the body.<sup>1</sup> Hair loss can be patchy, confluent or diffuse, scalp being the most common site. Long standing AA can be extremely

difficult to treat and has a poor prognosis.<sup>2</sup> Despite available therapeutic options, there has been a constant search for new, more effective hair restoration treatment. Platelet-rich plasma could be one such treatment. Growth factors in platelets' granules of PRP bind in the bulge area of hair follicle, promoting hair growth thus making PRP a potential useful therapeutic tool for alopecias, without major adverse effects.<sup>3</sup> Platelet-rich plasma (PRP) has been previously used to treat a variety of alopecias including AA

\* Corresponding author.

E-mail address: [kashish.tyagi93@gmail.com](mailto:kashish.tyagi93@gmail.com) (K. Tyagi).

with variable success rates.<sup>4</sup>

We hereby, report a case of chronic diffuse AA showing excellent response to PRP therapy.

## 2. Case Summary

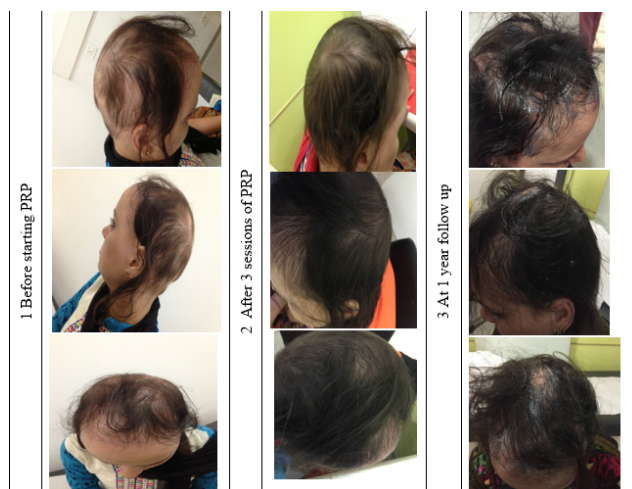A 21-year old girl presented with asymptomatic loss of hair from the scalp for more than two years. At the onset, it started as small round patches of hair loss which gradually coalesced to involve whole of the scalp. There was no history of similar illness in family, no history of drug intake and no history suggestive of systemic illness.

On examination, there was patchy loss of hair involving the scalp with few small, thin light-coloured hair in the occipital region, no other body site was involved. On the basis of examination a diagnosis of chronic diffuse alopecia areata progressing to alopecia totalis was made, which was confirmed by doing a skin biopsy for Histopathological examination from the sample taken from occipital scalp. Histopathology stained section showed epidermis and dermis with miniaturised hair follicles surrounded by variable inflammatory lymphohistiocytic infiltrate [Fig 1-2].

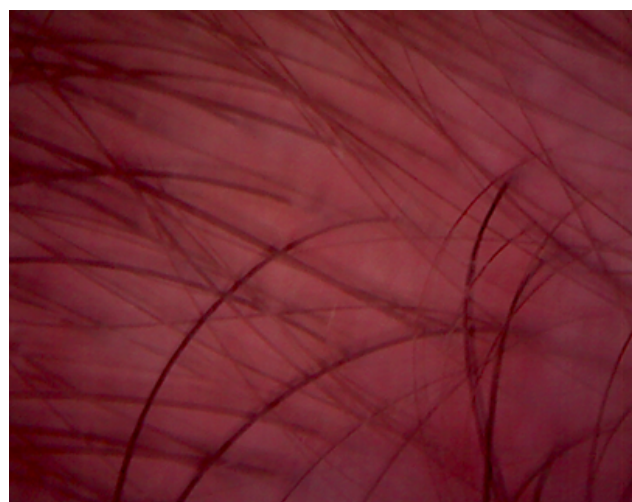
Patient had given history of undergoing treatment previously with no response. As a primary approach the girl was started on oral corticosteroids in the form of oral mini pulse therapy (Betamethasone 5 mg as a single morning dose after breakfast on 2 consecutive days in a week for 3 months and then tapered off over next 3 months),<sup>5</sup> topical clobetasol propionate 0.05% lotion, topical 5% minoxidil solution and vitamin supplements. In addition to OMP, Azathioprine 50 mg daily was added after 3 months as the response to treatment was very slow and frequently relapsing. Partial regrowth of thin hair was noted in some areas of scalp at 6 months but was short lasting even with the ongoing treatment. In addition to this, intralesional triamcinolone acetonide injections (TCA) were started in completely bald areas of scalp at 3 weekly intervals and continued for further 3 months. The response to treatment was still poor at the end of 1 year in the terms of relapses and appearance of new hair loss patches, which had an impact of the young girl's psychological state and it led her to stop all the ongoing treatment.

Then it was decided to go off the track and give a trial with PRP therapy. Patient agreed to undertake the trial. No other adjuvant treatment was given as patient did not want to take it. A total of eight sessions of PRP therapy were given.

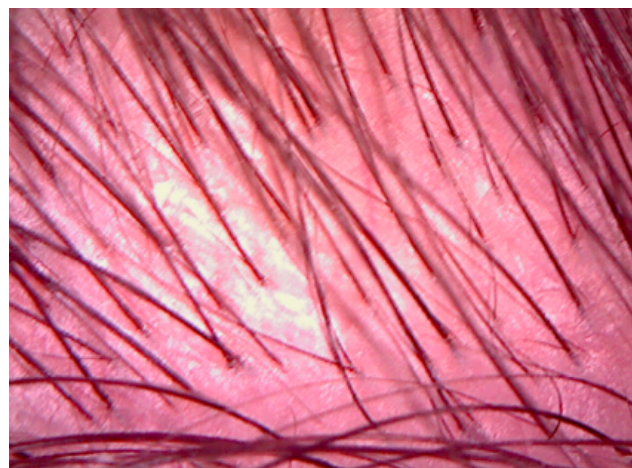
PRP was prepared using double spin technique<sup>6</sup> and sessions were repeated every 4 weeks. Dramatic response was noted after 2 sessions in the form of improvement in hair diameter and total volume. Resistant areas also started showing hair growth [Fig 4,5]. Patient has been under follow up since last one and a half years and hair growth is sustained.



**Fig. 1:**



**Fig. 2:** E-scopic image before starting PRP therapy



**Fig. 3:** E-scopic image after 3 sessions of PRP therapy

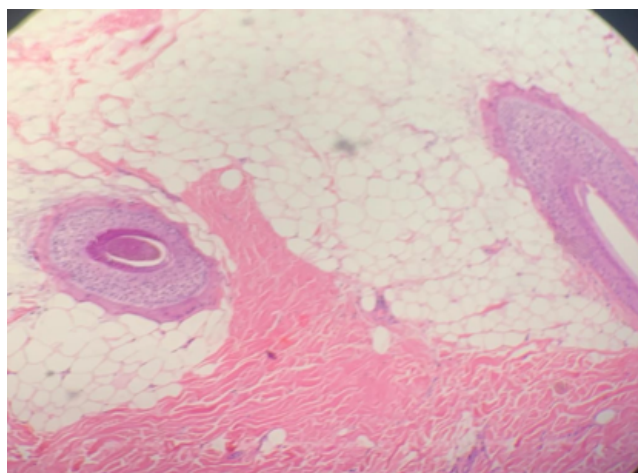


Fig. 4:

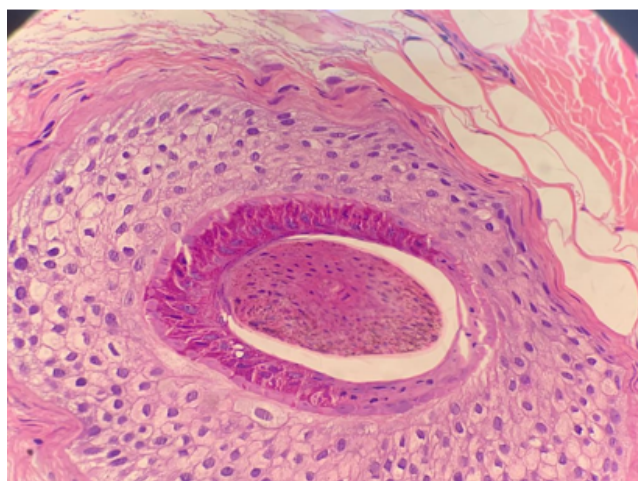


Fig. 5:

### 3. Discussion

There are a few studies assessing the role of PRP therapy in AA. First report to establish the efficacy of PRP as a treatment modality in AA was published by Trink et al in 2013.<sup>7</sup> This study showed PRP therapy to be superior to TCA and Placebo in growing pigmented hair in AA patches. Another study by Taieb et al showed PRP therapy to be effective in AA but inferior to Minoxidil.<sup>8</sup> Another study by Shumez et al compared PRP with TCA but there was no statistically significant difference between the two.<sup>9</sup> A study by Sukhbir Singh showed positive effect of PRP therapy in 20 subjects.<sup>10</sup> Another case report with ophiasis type AA resistant to intralesional steroid injections showed excellent response to PRP therapy.<sup>11</sup> In all these studies, the cases with patchy hair loss only were included. On the other hand, Ovidio and Roberto negated the role of PRP therapy in giving persistent results and preventing relapses in cases of chronic diffuse alopecia areata.<sup>12</sup> Previous studies have

demonstrated beneficial role of PRP therapy in cases of patchy alopecia areata, in contrast ours was a case of chronic diffuse AA. In spite of many treatment modalities tried for more than a year, the response was unsatisfactory. PRP therapy yielded amazing results in the form of hair growth over resistant areas and overall increase in pigmented hair which were sustained at one and a half year follow up. Our case was unique in the way that excellent response to PRP treatment was noted

1. In a case of diffuse alopecia areata.
2. In a case non- responsive to standard modalities.
3. In a case with no other supportive treatment.

Another similar case of chronic diffuse AA reported by Mubki showed improvement in hair growth but here PRP therapy was combined with TCA.<sup>13</sup>

### 4. Conflicts of Interest

The authors declare that there are no conflicts of interest regarding the publication of this paper.

### 5. Source of Funding

None.

### References

1. Paus R, Olsen AE, Messenger GA. Hair growth disorders. In: Fitzpatrick T, Wolff K, Goldsmith A, Gilchrist A, Paller SA, Leffell J, et al., editors. *Dermatology in General Medicine*. 7th Edn. New York: Mc-Graw-Hill; 2008. p. 753–77.
2. Alkhalifah A, Alsantali A, Wang E, McElwee KJ, Shapiro J. Alopecia areata update: part I. Clinical picture, histopathology, and pathogenesis. *J Am Acad Dermatol*. 2010;62(2):177–88. doi:10.1016/j.jaad.2009.10.032.
3. Maria-Angeliki G, Alexandros-Efstratios K, Dimitris R, Konstantinos K. Platelet-rich Plasma as a Potential Treatment for Noncicatricial Alopecias. *Int J Trichology*. 2015;7(2):54–63. doi:10.4103/0974-7753.160098.
4. Li ZJ, Choi HI, Choi DK, Sohn KC, Im M, Seo YJ, et al. Autologous Platelet-Rich Plasma: A Potential Therapeutic Tool for Promoting Hair Growth. *Dermatol Surg*. 2012;7(2):1040–6. doi:10.1111/j.1524-4725.2012.02394.x.
5. Pasricha JS, Kumrah L. Alopecia totalis treated with oral mini-pulse (OMP) therapy with betamethasone. *Indian J Dermatol Venereol Leprol*. 1996;62(2):106–9.
6. Dhurat R, Sukesh MS. Principles and Methods of Preparation of Platelet-Rich Plasma: A Review and Author's Perspective. *J Cutan Aesthet Surg*. 2014;7(4):189–97. doi:10.4103/0974-2077.150734.
7. Trink A, Sorbellini E, Bezzola P, Rodella L, Rezzani R, Ramot Y, et al. A randomized, double-blind, placebo- and active-controlled, half-head study to evaluate the effects of platelet-rich plasma on alopecia areata. *Br J Dermatol*. 2013;169(3):690–4. doi:10.1111/bjd.12397.
8. Taieb MAE, Ibrahim H, Nada EA. Platelets rich plasma versus minoxidil 5% in treatment of alopecia areata: A trichoscopic evaluation. *Dermatol Ther*. 2016;30(1). doi:10.1111/dth.12437.
9. Shumez H, Prasad P, Kaviarasan PK. Intralesional platelet rich plasma vs Intralesional triamcinolone in the treatment of alopecia areata: a comparative study. *Int J Med Res Health Sci*. 2015;4(1):118–22.
10. Singh S. Role of platelet-rich plasma in chronic alopecia areata: Our centre experience. *Indian J Plast Surg*. 2015;48(1):57–9.

11. Donovan J. Successful treatment of corticosteroid-resistant ophiasis-type alopecia areata (AA) with platelet-rich plasma (PRP). *JAAD Case rep.* 2015;1(5):305–7. doi:10.1016/j.jdc.2015.07.004.
12. Ovidio R, Roberto M. Limited Effectiveness of Platelet-Rich-Plasma Treatment on Chronic Severe Alopecia Areata. *Hair Ther Transplant.* 2014;4(1):1–2. doi:10.4172/2167-0951.1000116.
13. Mubki T. Platelet-rich plasma combined with intralesional triamcinolone acetonide for the treatment of alopecia areata: A case report. *J Dermatol Dermatol Surg.* 2015;doi:10.1016/j.jdds.2015.11.002.

**Kashish Tyagi**, Fellow Dermatology

**Ishani Mohapatra**, Consultant

**Komal Sharma**, Fellow Dermatology

**Cite this article:** Kapoor S, Tyagi K, Mohapatra I, Sharma K. PRP therapy in chronic diffuse alopecia areata – A case report. *IP Indian J Clin Exp Dermatol* 2021;7(4):363-366.

### Author biography

**Sheilly Kapoor**, Senior Consultant