



## Original Research Article

## Therapeutic outcome and safety of intralesional vitamin d3 in the treatment of cutaneous warts

Anshu Maheswari<sup>1</sup>, Atul Bothra<sup>2</sup>, Pankaj Adhicari<sup>2</sup>, Bornali Dutta<sup>2,\*</sup>, Seujee Das<sup>2</sup>

<sup>1</sup>Skin Square, Guwahati, Assam, India

<sup>2</sup>Dept. of Dermatology, Gauhati Medical College and Hospital, Guwahati, Assam, India



## ARTICLE INFO

## Article history:

Received 08-12-2021

Accepted 02-03-2022

Available online 30-03-2022

## Keywords:

Cutaneous Warts

Intralesional treatment

Vitamin D3

Immunotherapy

## ABSTRACT

**Introduction:** Cutaneous warts are a common but vexing condition with high recurrence rate and tendency to spread inspite of various therapeutic options. Intralesional immunotherapy is an attractive modality as it has an additional role of clearing both treated and distant warts by stimulating cell-mediated immunity against human papilloma virus.

**Aims and Objectives:** To evaluate efficacy and safety profile of intralesional Vitamin D3 formulation in the treatment of cutaneous warts.

**Materials and Methods:** Patients with multiple cutaneous warts were injected intralesionally with Vitamin D3 (0.2 ml, 15 mg/ml) at an interval of 2 weeks for maximum of 4 sessions, and patients were followed up for 6 months.

**Results:** Of the 106 patients included, complete clearance was seen in 26 (76.4 %) patients of verruca vulgaris, 20 (66.6 %) of palmoplantar warts, 18 (100 %) of plane warts, 6 (50 %) of genital and filiform warts each. Moderate response was seen in 14 (13.2%) patients while mild response was seen in 6 (5.7 %) patients. No response was seen in 10 (9.4 %) patients. No serious adverse effects were reported.

**Conclusion:** Intralesional Vitamin D3 is effective, safe, cheap and long lasting modality with a short downtime for the treatment of multiple cutaneous warts.

This is an Open Access (OA) journal, and articles are distributed under the terms of the [Creative Commons Attribution-NonCommercial-ShareAlike 4.0 License](https://creativecommons.org/licenses/by-nc-sa/4.0/), which allows others to remix, tweak, and build upon the work non-commercially, as long as appropriate credit is given and the new creations are licensed under the identical terms.

For reprints contact: [reprint@ipinnovative.com](mailto:reprint@ipinnovative.com)

### 1. Background

Verrucae (Warts) are common epidermal proliferations caused by human papillomavirus, an epitheliotropic DNA virus.<sup>1</sup> Although spontaneous improvement is seen in 65-78% of cases, the cosmetic disfigurement, recurrent nature and pain (especially on the palms and soles) are frequent reasons for patients seeking treatment.<sup>2</sup> Till recently, local destruction was the commonly employed modality through topical keratolytics, electrocoagulation, cryotherapy, surgical excision or laser therapy. These modalities lead to significant tissue destruction, pain and frequent recurrences. Immunotherapy by various

antigens is a new promising modality which has shown to clear both treated and distant warts by mounting a delayed hypersensitivity reaction to the viral antigen. Immunotherapy acts by enhancing cell mediated immunity against HPV, thus helping in clearance of both treated and distant warts.<sup>3</sup>

### 2. Aims and Objectives

The primary objective of this study was to evaluate the efficacy of intralesional vitamin D<sub>3</sub> for the treatment of warts. The secondary objectives were to study the side effect profile, correlation of efficacy with the wart subtype, correct dosage and median time of efficacy as well as the time of recurrence(if any).

\* Corresponding author.

E-mail address: [dr.bornali.dutta@gmail.com](mailto:dr.bornali.dutta@gmail.com) (B. Dutta).

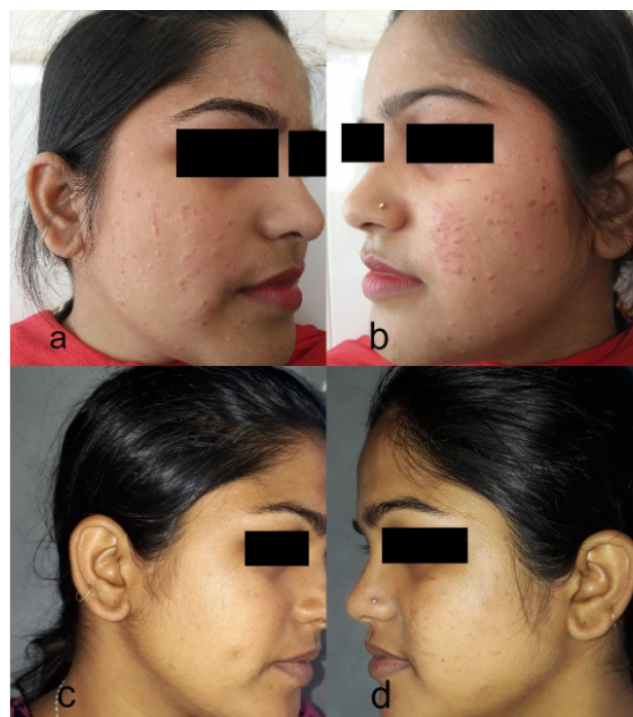### 2.1. Procedure

A hospital based prospective interventional study was carried out in the Department of Dermatology of a tertiary care hospital which was followed by per protocol statistical analysis. Data and records of patients (5 – 70 years) with multiple ( $\geq 2$ ) warts over a period of 2 years from 1st April 2017 to 31st March 2019 were studied. Written informed consent of the patients had been taken. Patients whose data and photographic records were available and who were followed up till 6 months of the last injection were included in the study. Patients receiving any other treatment for warts, pregnant and lactating females and those with history of immunosuppression or hypersensitivity to Vitamin D<sub>3</sub> were excluded from the study. The study was approved by the Institutional Ethical Committee. Method of injection and outcome evaluation: Vitamin D<sub>3</sub> (0.2 ml, 15 mg/ml) was injected into the base of two warts/per session (largest in size) after injecting lignocaine (0.2 ml, 20mg/ml). Injections were repeated every 2 weeks for a maximum of 4 sessions or until complete clearance, whichever was earlier. Patients were followed up for 6 months after the last injection to study for any side effects or recurrence. Serum calcium levels were monitored. Photographic records and data were recorded at treatment session for resolution of the treated wart and the distant warts, reduction in the size and number of warts and any immediate or delayed complications or side effects. Results were graded as complete clearance, moderate response, mild response and no response by comparing with the baseline clinical photographs. Complete clearance implied clearance of all distant and treated warts, moderate response denoted 50-100% reduction in size and/or number of warts, while mild response indicated 1-50% reduction in size and/or number of warts. Patients showing no reduction in size or number of warts after 4 injections were classified as no response. After completion of the 4 sessions or in case of complete clearance before completion of the sessions, patients were followed up for 6 months (at two monthly interval) to look for recurrence or any delayed complication.

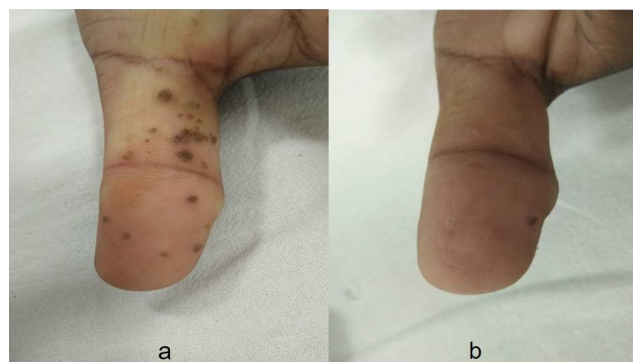
### 3. Results

The study included 106 patients including 58 males and 48 females (M: F- 1.2: 1). Patients ranged from 6 – 65 years with a mean of 28.64 years. The number of warts ranged from 2 to 26 warts with a mean of 10.28 warts. Of the 106 patients, 34 (32.08 %) had verruca vulgaris, 30(28.03 %) had palmoplantar warts, 18(16.98 %) had plane warts and 12(11.32%) had genital and filiform warts each.

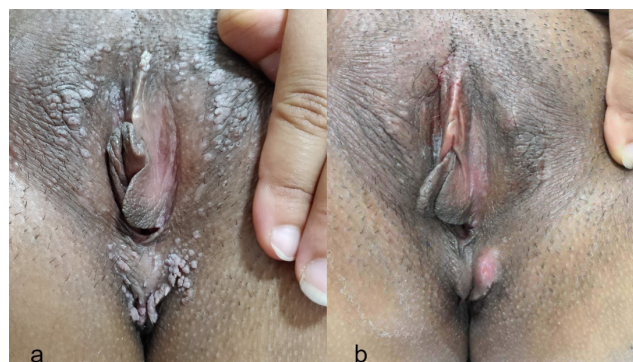Complete clearance was seen in 76.4 % of verruca vulgaris, 66.6 % of palmoplantar warts, 100 % of plane warts and 50 % of genital and filiform warts each. Moderate response was seen in 13.2% while mild response was seen in 6 patients 5.7 %. No response was seen in 9.4 %.



**Fig. 1:** a,b: Pre treatment plane warts in the face; c,d: post intralesional vitamin D<sub>3</sub> showing complete resolution



**Fig. 2:** a: Pre treatment verruca vulgaris on the thumb; b: Post intralesional vitamin D<sub>3</sub> showing moderate response



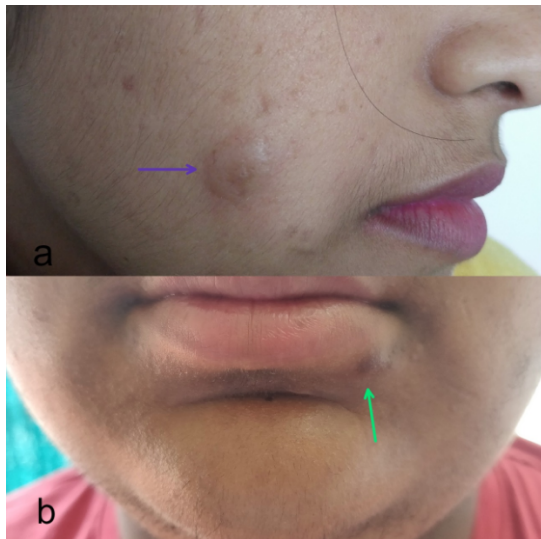
**Fig. 3:** a: Pre treatment genital warts; b: Post intralesional vitamin D<sub>3</sub> showing complete response

**Table 1:** The response of various types of warts to intralesional vitamin D3

	<b>Verruca vulgaris (n = 34) (%)</b>	<b>Palmoplantar warts (n=30) (%)</b>	<b>Plane warts (n=18) (%)</b>	<b>Genital warts (n=12) (%)</b>	<b>Filiform warts (n=12) (%)</b>	<b>Total (n=106) (%)</b>
Complete clearance	<b>26 (76.4)</b>	<b>20 (66.6)</b>	<b>18 (100)</b>	<b>6 (50)</b>	<b>6 (50)</b>	<b>76 (71.7%)</b>
Moderate response	4 (11.8)	4 (13.3)	0 (0)	2 (16.7)	4 (33.3)	14 (13.2%)
Mild response	2 (5.8)	2 (6.7)	0 (0)	2 (16.7)	0 (0)	6 (5.7%)
No response	2 (5.8)	4 (13.3)	0 (0)	2 (16.7)	2 (16.7)	10 (9.4%)
Total	34	30	18	12	12	106 (100%)

**Table 2:** Comparison of different immunotherapy agents in warts

<b>Antigen/Vaccine</b>	<b>Study</b>	<b>Number of patients</b>	<b>Maximum number of sessions</b>	<b>Interval between sessions</b>	<b>Clearance rate (%)</b>
Mycobacterium w (indicuspranii) vaccine	Singh et al <sup>4</sup>	44	10	2 weeks	54.5
Candida albicans antigen	Majid et al <sup>5</sup>	34	3	3 weeks	55.9
MMR vaccine	Saini et al <sup>6</sup>	86	3	3 weeks	46.5
PPD	Saoji et al <sup>7</sup>	55	4	2 weeks	76
Vitamin D3	Our study	106	4	2 weeks	71.7

**Fig. 4:** **a:** Blue arrow shows swelling at the site of intralesional Vitamin D<sub>3</sub> injection; **b:** Green arrow shows hyperpigmentation at the site of intralesional vitamin D<sub>3</sub> injection

The response of the various types of warts to intralesional vitamin D<sub>3</sub> is tabulated in Table 1 (Figures 1, 2 and 3).

Of the 76 patients showing complete clearance, 56 required 4 sessions of Vitamin D<sub>3</sub>, 16 required 3 sessions while 4 patients required only 2 sessions of Vitamin D<sub>3</sub> injections. The average number of injections required for complete clearance was 3.68.

Complications were seen in 23 patients (18.8%), which included swelling at the site of injection in 16 patients (15.09%) and hyperpigmentation after injection in 4 patients (3.8%) (Figure 4). Swelling subsided in 2-3 weeks without

any treatment.

Recurrence was not seen in any patient during the 6 month follow up period. There was no increase in serum calcium level above the normal reference range in any of the patients during the entire study period.

#### 4. Discussion

Local destructive procedures are the commonly available treatment modality for warts which include electrocautery, lasers or cryotherapy. However, all these procedures are tedious and painful and not practical in case of multiple warts. These also cause destruction of the surrounding tissue and hence may lead to scarring. Moreover, there can be recurrence of warts even after complete removal by these procedures. Hence immunotherapy by use of various agents is a good option for treatment of warts. Immunotherapy acts by boosting immunity to HPV virus as a result of which both treated and distal warts are cleared.<sup>8</sup> Various agents have been used for immunotherapy such as Mycobacterium w vaccine,<sup>4</sup> Candida albicans antigen,<sup>5</sup> MMR (measles, mumps, rubella) vaccine,<sup>6</sup> Purified Protein Derivative (PPD) etc.<sup>7</sup> The advantage with immunotherapy is its low recurrence rate compared to the normal destructive procedures.

In the present study, we have used Vitamin D<sub>3</sub> for immunotherapy for the treatment of multiple warts. The exact mechanism of action of Vitamin D<sub>3</sub> as an immunomodulator is not known. Studies suggest that it can regulate proliferation and differentiation of keratinocytes and hence modulates cytokine production. It inhibits the expression of tumor necrosis factor (TNF)- $\alpha$ , TNF- $\gamma$ , interleukin-6 (IL-6) and IL-8, mediated through Vitamin D receptor (VDR)-dependent pathway.<sup>9</sup> Hence topical

Vitamin D<sub>3</sub> has been used in the treatment of warts in various studies.<sup>10,11</sup>

Kavya et.al. used intralesional vitamin D<sub>3</sub> for the treatment of palmoplantar and common warts.<sup>2</sup> A total of 42 patients were included in the study and maximum of 4 injections were given at 2 weekly interval. They achieved a clearance of 78.6% with recurrence in 2.38% patients. Similarly, Raghukumar et.al. studied the effect of Vitamin D<sub>3</sub> in verruca vulgaris, palmoplantar, filiform and plane warts.<sup>12</sup> Sixty patients were included in the study and a maximum of 4 sessions of Vitamin D<sub>3</sub> injections intralesionally were given at 2 weekly interval. Ninety percent of the patients responded while recurrence was seen in 3.33%. The results of both the studies were similar to our study as shown in the following table.

Various other antigens and vaccines have been used as immunotherapy and the response of these are compared in Table 2.

The response rate achieved in our study was 71.7 % in maximum of 4 sessions which was superior to the results achieved with Mycobacterium w vaccine, Candida albicans and MMR vaccine. However, treatment with PPD was superior to that of Vitamin D<sub>3</sub>, but the complications and side effects during injection were more in the form of pain, severe swelling, eczematous changes, constitutional symptoms like fever and bodyache. However, in our study we did not experience any major systemic or local side effects requiring any form of treatment. Also, there was no recurrence seen in our study during the 6 month follow up period.

## 5. Conclusion

Intralesional Vitamin D<sub>3</sub> injection is cheap and effective approach for treatment of multiple warts. Our study concludes its high efficacy in plane warts followed by verruca vulgaris. It is safe as compared to other immunotherapy agents with no major local or systemic side effects. It can be easily used in children as it is safe and painless compared to other locally destructive procedures.

The limitations of this study were its lack of a control group. However, the results are encouraging. Large well designed, randomised case control study is required to confirm the efficacy of intralesional Vitamin D<sub>3</sub> in the treatment of multiple warts.

## 6. Conflict of Interest

The authors declare they have no conflict of interest.


## 7. Source of Funding

No financial support was received for the work within this manuscript.

## References

1. Leto M, Jr GS, Porro A, Tomimori J. Human papillomavirus infection: etiopathogenesis, molecular biology and clinical manifestations. *An Bras Dermatol*. 2011;86(2):306–17.
2. Thappa DM, Chiramel MJ. Evolving role of immunotherapy in the treatment of refractory warts. *Indian Dermatol Online J*. 2016;7(5):364–70. doi:10.4103/2229-5178.190487.
3. Kavya M, Shashikumar BM, Harish MR, Shweta BP. Safety and efficacy of intralesional vitamin D<sub>3</sub> in cutaneous warts: An open uncontrolled trial. *J Cutan Aesthet Surg*. 2017;10(2):90–4. doi:10.4103/JCAS.JCAS\_82\_16.
4. Singh S, Chouhan K, Gupta S. Intralesional immunotherapy with killed Mycobacterium indicuspranii vaccine for the treatment of extensive cutaneous warts. *Indian J Dermatol Venereol Leprol*. 2014;80(6):509–14. doi:10.4103/0378-6323.144145.
5. Majid I, Imran S. Immunotherapy with intralesional Candida albicans antigen in resistant or recurrent warts: A study. *Indian J Dermatol*. 2013;58(5):360–5. doi:10.4103/0019-5154.117301.
6. Saini P, Mittal A, Gupta LK, Khare AK, Mehta S. Intralesional mumps, measles and rubella vaccine in the treatment of cutaneous warts. *Indian J Dermatol*. 2016;82(3):343–5. doi:10.4103/0378-6323.175920.
7. Saoji V, Lade NR, Gadegone R, Bhat A. Immunotherapy using purified protein derivative in the treatment of warts: An open uncontrolled trial. *Indian J Dermatol Venereol Leprol*. 2016;82(1):42–6. doi:10.4103/0378-6323.171650.
8. Sterling JC, Handfield-Jones S, Hudson PM. British Association of Dermatologists. Guidelines for the management of cutaneous warts. *Br J Dermatol*. 2001;144(1):4–11. doi:10.1046/j.1365-2133.2001.04066.x.
9. Alghamdi K, Kumar A, Moussa N. The role of Vitamin D in melanogenesis with an emphasis on vitiligo. *Indian J Dermatol Venereol Leprol*. 2013;79(6):750–8. doi:10.4103/0378-6323.120720.
10. Rind T, Oiso N, Kawada A. Successful treatment of anogenital wart with a topical Vitamin D(3) Derivative in an infant. *Case Rep Dermatol*. 2010;2(1):46–9. doi:10.1159/000312986.
11. Moscarelli L, Annunziata F, Mjeshtri A, Paudice N, Tsalouchos A, Zanazzi M, et al. Successful treatment of refractory wart with a topical activated Vitamin D in a renal transplant recipient. *Case Rep Transplant*. 2011;p. 368623. doi:10.1155/2011/368623.
12. Raghukumar S, Ravikumar BC, Vinay KN, Suresh MR, Aggarwal A, Yashovardhana DP, et al. Intralesional Vitamin D<sub>3</sub> Injection in the Treatment of Recalcitrant Warts: A Novel Proposition. *J Cutan Med Surg*. 2017;21(4):320–4. doi:10.1177/1203475417704180.

## Author biography

**Anshu Maheswari**, Consultant  <https://orcid.org/0000-0001-7146-4521>

**Atul Bothra**, Senior Resident  <https://orcid.org/0000-0002-7331-273X>

**Pankaj Adhicari**, Professor

**Bornali Dutta**, Associate Professor

**Seujej Das**, Senior Resident

**Cite this article:** Maheswari A, Bothra A, Adhicari P, Dutta B, Das S. Therapeutic outcome and safety of intralesional vitamin d3 in the treatment of cutaneous warts. *IP Indian J Clin Exp Dermatol* 2022;8(1):47-50.