



## Case Series

# Hypohidrotic ectodermal dysplasia- A case series demonstrating indistinguishable phenotypes produced by autosomal recessive and x-linked forms

Sushitha Votturu<sup>1,\*</sup>, Swarna Kumar Matavalum<sup>1</sup>, Vijaya Mohan Rao Avisi<sup>1</sup>, Navyatha Chamarthi<sup>1</sup>, Pavan Kumar Reddy Gurijala<sup>1</sup>

<sup>1</sup>Dept. of Dermatology, Narayana Medical College and Hospital, Nellore, Andhra Pradesh, India



### ARTICLE INFO

#### Article history:

Received 23-12-2021

Accepted 15-01-2022

Available online 30-03-2022

#### Keywords:

Hypohidrotic ectodermal dysplasia

Xlinked

Autosomal recessive

### ABSTRACT

Ectodermal dysplasia (ED) is a rare hereditary disorder involving two or more of the ectodermal structures, which include the skin, hair, nails, teeth, and sweat glands. Hypohidrotic ectodermal dysplasia (HED) is the most common type of ED. HED is usually an X-linked recessive (XLR) disorder affecting predominantly males. However, Autosomal recessive (AR) and Autosomal dominant (AD) forms have been described in rare cases. Here, we report three cases of HED showing different patterns of inheritance with similar phenotypes; one with a classic X-linked inheritance and the other two include female siblings with an Autosomal recessive inheritance.

This is an Open Access (OA) journal, and articles are distributed under the terms of the [Creative Commons Attribution-NonCommercial-ShareAlike 4.0 License](https://creativecommons.org/licenses/by-nc-sa/4.0/), which allows others to remix, tweak, and build upon the work non-commercially, as long as appropriate credit is given and the new creations are licensed under the identical terms.

For reprints contact: [reprint@ipinnovative.com](mailto:reprint@ipinnovative.com)

## 1. Introduction

Hypohidrotic ectodermal dysplasia (HED) is a rare genetic disorder characterized by the faulty development of the ectodermal structure resulting in anhidrosis or hypohidrosis, hypotrichosis, and hypodontia.<sup>1,2</sup> It is usually an X-linked recessive (XLR) disorder affecting predominantly males. Mutations in the gene encoding ligand ectodysplasin A (EDA) underlie classic, X-linked recessive HED, whereas mutations in the genes encoding EDA receptor (EDAR) and EDA receptor-associated death domain (EDARADD) result in autosomal dominant and autosomal recessive (AR) forms of HED respectively. Hereby, two case reports of HED showing different patterns of inheritance are described.

## 2. Case Report 1

Two sisters, 19-year-old and 15-year-old presented with a history of intolerance to heat, reduced sweating, sparsity of scalp hair, eyebrows, axillary and pubic hair, and

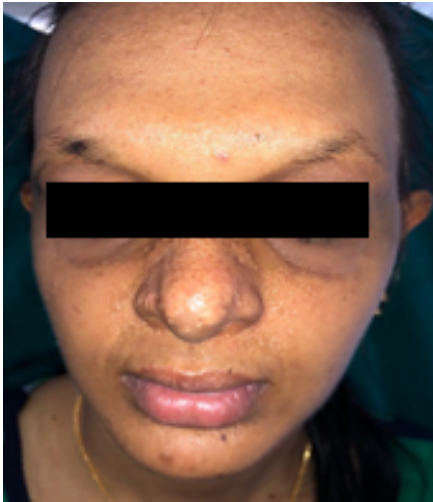
decreased dentition since childhood. They were born to consanguineous parents and there were no other similar cases in the family. On examination: Ill-defined skin-colored papules were seen over the nose and the periorbital skin is wrinkled and hyperpigmented in both sisters. Oral examination revealed dental prosthesis in elder sister and complete absence of teeth in younger sister. This report of two sisters with a complete syndrome of HED and history of consanguinity favors AR inheritance.

## 3. Case Report 2

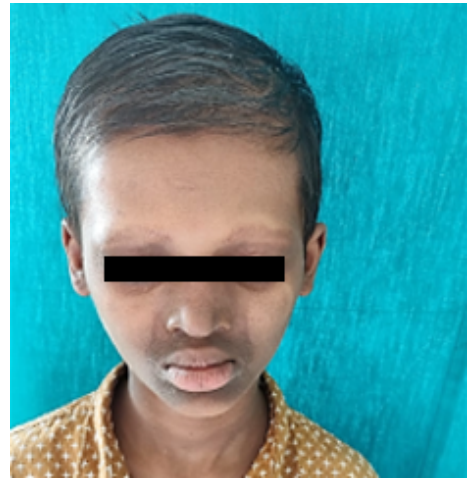A 10-year-old boy born to non-consanguineous parents presented with decreased sweating, absence of eyebrows, and sparse hair over the scalp and eyelashes. On examination, loose wrinkled and hyperpigmented skin at perinasal, perioral, and periorbital areas were noted. Frontal bossing and everted lips were also noted. Oral examination revealed a complete absence of teeth. A clinical diagnosis of X-linked HED was made based on history and clinical examination.

\* Corresponding author.

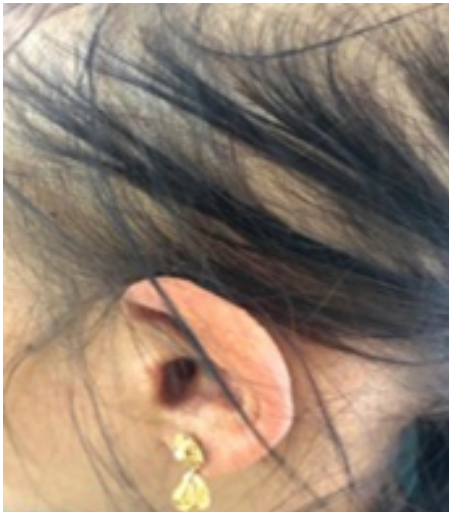E-mail address: [sushi.cool5@gmail.com](mailto:sushi.cool5@gmail.com) (S. Votturu).



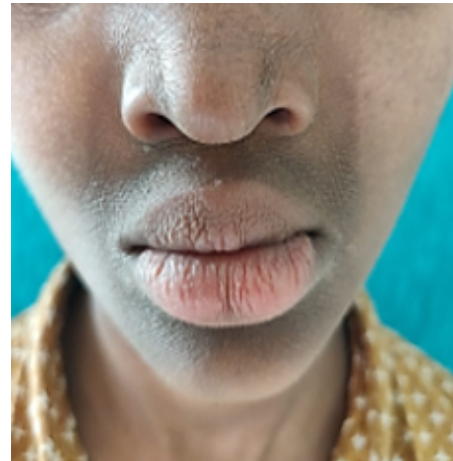
**Fig. 1:** Sparse eyebrows in elder sister



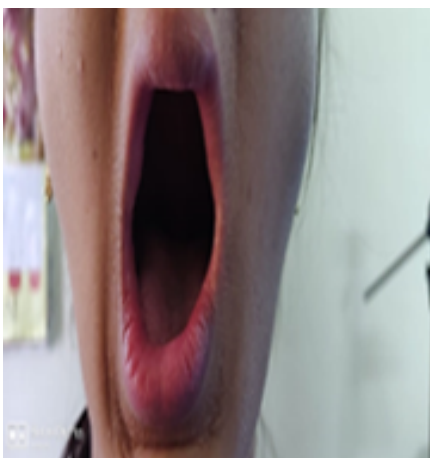
**Fig. 4:** Absence of eyebrows



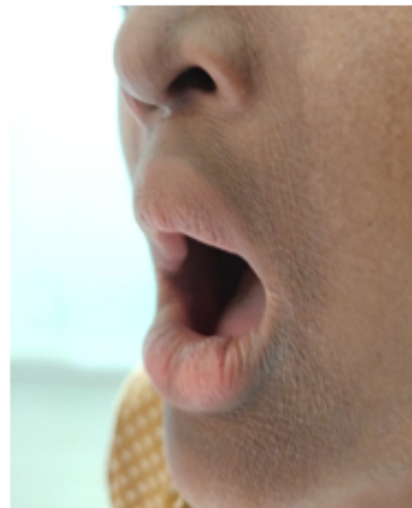**Fig. 2:** Reduced scalp hair in elder sister



**Fig. 5:** Hyperpigmented perioral skin



**Fig. 3:** Complete absence of teeth in younger sister



**Fig. 6:** Complete absence of teeth

#### 4. Discussion

Ectodermal dysplasia (ED) is a rare, heterogeneous group of disorders involving the structures developing from the primordial external germ layer such as hair, teeth, nails, and sweat glands. Hypohidrotic ectodermal dysplasia (Christ-siemens-Touraine syndrome) is the most common type among this group of disorders. Incidence is about 1 in 100,000 live births. Mutations in EDA encoding epithelial morphogen ectodysplasin. A results in X-linked recessive disease whereas mutations in EDAR & EDARADD results in Autosomal recessive and Autosomal dominant forms.

Clinically, the disease is characterized by the triad of hypohidrosis or anhidrosis, hypotrichosis, and oligodontia. Other clinical features include episodic high pyrexia and heat intolerance, smooth, dry, finely wrinkled skin, frontal bossing, prominent malar bones, sunken cheeks, depressed nasal bridge and pointed chin, maxillary hypoplasia, and low arched palate. Mucosal involvement in the form of atrophic rhinitis, sinusitis, dysphagia, hoarseness of voice, and bronchitis is seen.<sup>3,4</sup>

Diagnosis is based on clinical evaluation, identification of characteristic physical findings, and specialized laboratory tests which starch iodine test, pilocarpine iontophoresis to determine the reduction or absence of perspiration. Histopathology shows flattened epidermis and reduced number of sebaceous glands and hair follicles. In addition, dental x-rays aid in verifying the absence of certain teeth and characterize associated dental abnormalities. Molecular testing for mutations in EDA, EDAR, and EDARADD genes confirms the diagnosis. Prenatal diagnosis can be done by fetal skin biopsy and DNA probing techniques on a chorionic villus biopsy specimen.

Management of children with HED is a challenge because of their heat intolerance and susceptibility to pulmonary infections. Maintenance of a cool and ambient temperature is required. Advice regarding oral hygiene prevents early loss of teeth due to caries Provision of hair and dental prosthesis maintains patient's self-esteem.

#### 5. Conclusion

Phenotypically identical types of HED can be caused by mutations of both X-linked and autosomal loci. The findings

of equally affected males and females in single sibships, as well as the presence of consanguinity support an autosomal recessive mode of inheritance. Genetic counseling of the involved families plays an important preventive role.

#### 6. Conflict of Interest

The authors declare they have no conflict of interest.

#### 7. Source of Funding

No financial support was received for the work within this manuscript.

#### References

1. Agarwal S, Gupta S. Hypohidrotic ectodermal dysplasia. *Indian Dermatol Online J.* 2012;3:125–7.
2. Lodha A, Someshwar S. Hypohidrotic ectodermal dysplasia with autosomal inheritance: A rare entity. *Muller J Med Sci Res.* 2019;10(2):82–5.
3. Inamdar C. Anhidrotic ectodermal dysplasia-autosomal recessive form. *Indian J Dermatol Venerol Leprol.* 1994;60:163–4.
4. Munoz R, Lestringant G, Sybert V, Frydman M, Alswaini A, Frossard PM, et al. Definitive Evidence for an Autosomal Recessive Form of Hypohidrotic Ectodermal Dysplasia Clinically Indistinguishable from the More Common X-Linked Disorder. *The American Journal of Human Genetics.* 1997;61(1):94–100.

#### Author biography

**Sushitha Votturu**, Post Graduate

**Swarna Kumar Matavalum**, Associate Professor

**Vijaya Mohan Rao Avis**a, Professor and HOD

**Navyatha Chamarthi**, Post Graduate

**Pavan Kumar Reddy Gurijala**, Post Graduate

**Cite this article:** Votturu S, Matavalum SK, Avis VMR, Chamarthi N, Gurijala PKR. Hypohidrotic ectodermal dysplasia- A case series demonstrating indistinguishable phenotypes produced by autosomal recessive and x-linked forms. *IP Indian J Clin Exp Dermatol* 2022;8(1):64-66.