



## Case Series

## Mysterious mycetoma foot – A case series

Nivedha Priyanka A<sup>1,\*</sup><sup>1</sup>Dept. of Dermatology, Venereology and Leprosy, Aarupadai Vedu Medical College and Hospital (Vinayaka Missions Research Foundation Deemed University), Salem, Tamil Nadu, India

## ARTICLE INFO

## Article history:

Received 25-11-2022

Accepted 22-12-2022

Available online 04-04-2023

## Keywords:

Actinomycetoma

Madura Foot

Eumycetoma

## ABSTRACT

**Background:** Mycetoma or Madura foot is a unique tropical disease affecting skin, subcutaneous tissue, and bones commonly the foot, characterized by triad of localized swelling, multiple sinus tracts and discharge of grains or granules. The causative microorganism enters the skin through minor abrasions caused by trivial injuries. Mycetoma classified into eumycetoma caused by fungus such as *Madurella mycetomatis* etc, and actinomycetoma caused by bacteria such as *Actinomadura madurae* etc. Approximately 75% of mycetoma cases are actinomycetoma in India. Usually Actinomycetoma responds well to antibacterial therapy whereas eumycetoma poorly responds to antifungal therapy with frequent recurrences.

**Case Series:** Three cases of actinomycetoma foot were reported at Aarupadai Vedu Medical College and Hospital. These cases were males of low socioeconomic status, residing at villages (rural areas) around Chidambaram town and farmers by occupation. These cases were provisionally diagnosed as actinomycetoma foot clinically and with laboratory investigation such as KOH, Gram stain. Confirmation was done by Fungal culture and Biopsy. No bony involvement was confirmed by radiologically. These three cases were treated with Welsch regimen of 3 cycles of injection amikacin IV for 21 days thrice at the interval of 15 days combined with oral Cotrimaxole for 6 months showed satisfying response. Out of three cases one case showed recurrence due to irregular treatment undergone by the patient. The recurrence was confirmed by repeat biopsy which showed the evidence of sinus tracts lined by inflammatory vascular granulation tissue. This case was presented mainly to establish the prolonged disease course and often diagnosed at the later stage.

**Conclusion:** Therefore the diagnostic and therapeutic challenges along with epidemiological data emphasize the need to pay more attention to this unique neglected tropical disease.

This is an Open Access (OA) journal, and articles are distributed under the terms of the [Creative Commons Attribution-NonCommercial-ShareAlike 4.0 License](https://creativecommons.org/licenses/by-nc-sa/4.0/), which allows others to remix, tweak, and build upon the work non-commercially, as long as appropriate credit is given and the new creations are licensed under the identical terms.

For reprints contact: [reprint@ipinnovative.com](mailto:reprint@ipinnovative.com)

## 1. Introduction

Mycetoma or Madura foot is a unique tropical disease affecting skin, subcutaneous tissue and bones commonly foot.<sup>1</sup>

Characterized by triad of localized swelling, multiple sinus tracts and discharge of coloured grains predisposed by

thorn pricks and penetrating injuries.<sup>2</sup>

The epidemiology of disease characterised by an endemic region located between latitude of 15 degree south and 30 degree north known as Mycetoma belt.<sup>3</sup>

Classified as actinomycetoma (bacteria) and eumycetoma (fungi).<sup>1</sup>

Here we report three cases of actinomycetoma foot, treated with antibiotics to create awareness regarding the prevalence of disease.

\* Corresponding author.

E-mail address: [ashoknivedha08@gmail.com](mailto:ashoknivedha08@gmail.com)

(Nivedha Priyanka A).

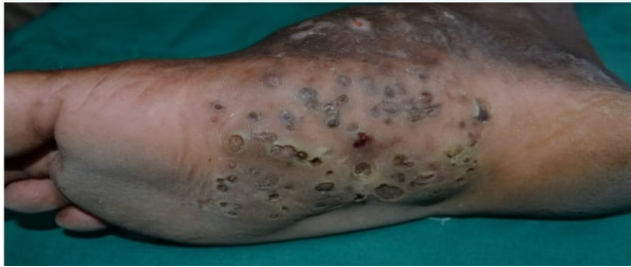## 2. Case Series Report

### 2.1. Case 1

A 35 year old male admitted with the complaints of swelling and discharge over the right foot for 1 year duration.

#### 2.1.1. On examination

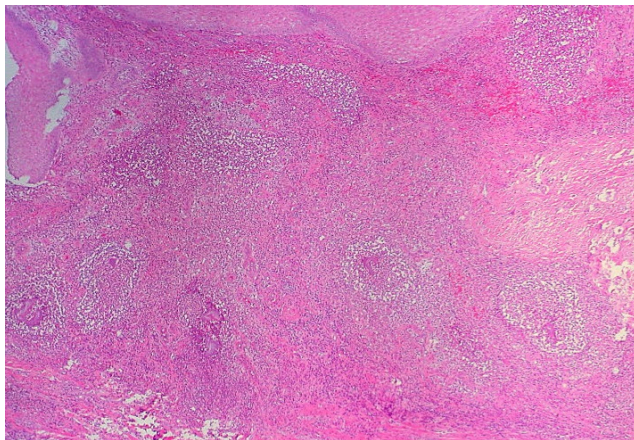
An ill defined nodular swelling of size 10x10x8cm seen over the medial aspect of right foot involving instep with multiple discharging sinuses.



**Fig. 1:**

#### 2.1.2. Investigations

Gram stain shows few pus cells and gram positive cocci. Potassium hydroxide mount shows no branched septate hyphae and fungal spores. Fungal culture shows no evidence of fungal filaments seen. X-Ray foot reveals no bony abnormalities. Histopathological examination shows Neutrophillic infiltrate seen surrounded by palisading histiocytes beyond which mixed inflammatory infiltrate comprising lymphocytes, plasma cells, eosinophils, macrophage and fibrosis seen.<sup>4</sup>



**Fig. 2:**

#### 2.1.3. Treatment

Patient was treated with Welsch regimen of 3 cycles of injection amikacin 15mg/kg IV for 21 days thrice at the

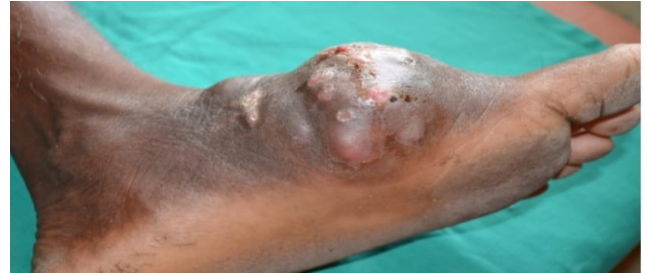interval of 15 days combined with Tab Sulfamethoxazole and trimethoprim (7 & 35mg/kg/day respectively) for 6 months showed satisfying response.<sup>5</sup>

### 2.2. Case 2

A 65 year old male admitted with the complaints of swelling and discharge over the left foot for 1 year duration.

#### 2.2.1. On examination

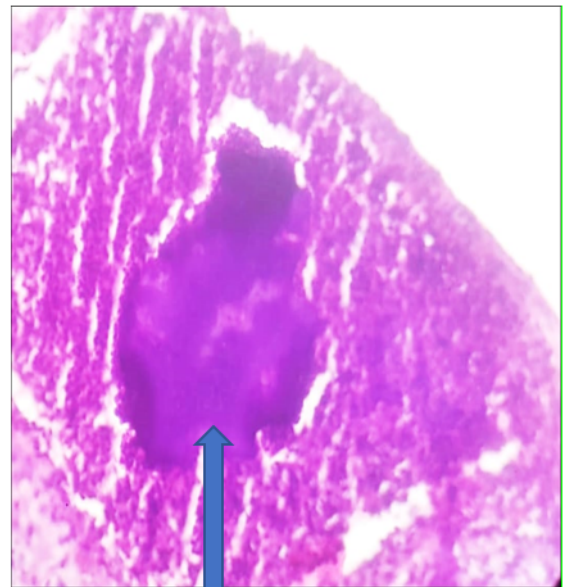
An ill defined diffuse swelling of size 10x10cm seen over the left foot with multiple discharging sinuses.



**Fig. 3:**

#### 2.2.2. Investigations

Gram stain shows multiple pus cells and gram positive cocci. Potassium hydroxide mount shows no branched septate hyphae and fungal spores. X-Ray Foot reveals underlying bony abnormalities with osteolytic changes. Histopathological Examination shows multiple sinus tracts are identified along with foci of microabscess admist actinomycetes colony.



**Fig. 4:** Splender hopplie phenomenon

### 2.2.3. Treatment

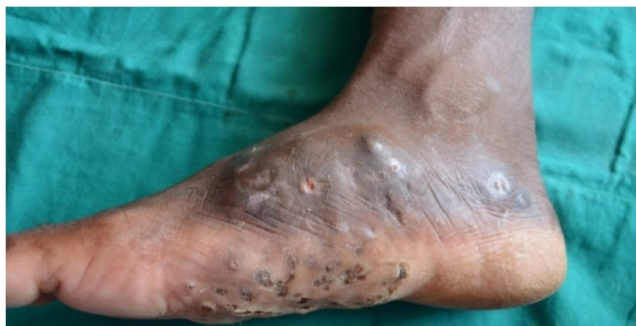Patient was treated with modified two step treatment for actinomycetoma with intensive phase of Gentamycin (80mg twice daily intravenously), and Tablet Trimethoprim Sulphamethoxazole (2 tablets of 960mg twice daily) for 4 weeks along with Maintenance Phase (Step 2) Doxyxycline 100mg orally, twice daily)and Tablet Trimethoprim Sulphamethoxazole as above for 6 months.<sup>6</sup>

### 2.3. Case 3

A 60 year old male admitted with the complaints of swelling with discharge over the right foot for 6 months duration.

#### 2.3.1. On examination

A localized well-defined tender swelling of size 6x6cm present over the dorsomedial aspect of right foot with multiple sinuses discharging white granules.



**Fig. 5:**

#### 2.3.2. Investigations

Gram stain shows gram positive cocci. Potassium hydroxide mount shows no evidence of fungal filaments. Biopsy was not done since the patient is not willing for biopsy.

#### 2.3.3. Treatment

Patient was started on welsch regimen. Recurrence was observed in this patient due to irregular treatment and poor compliance.

### 3. Discussion

Actinomycetoma caused by bacteria such as Actinomadura madurae, Actinomadura pelletieri etc.

In India prevalence of actinomycetoma is approximately 75%.

Actinomycetoma with high index of suspicion diagnosed at an earlier stage by microbial culture of discharging

grains or grains extracted by overnight saline dressing and histopathological examination.

Cutaneous tuberculosis, Osteomyelitis, Kaposi sarcoma can be close differential diagnosis.<sup>1</sup>

Periodical deeper tissue biopsy useful in partial debulking to assess disease activity.

Combination antibiotic therapy is necessary in case of actinomycetoma along with regular follow up and proper foot care.

### 4. Conclusion

Early diagnosis, prompt treatment and detection of underlying bony involvement may save the limb.

Therefore the diagnostic and therapeutic challenges in treating mycetoma foot and the epidemiological data emphasis the necessity to pay more attention to this unique neglected tropical disease.<sup>7</sup>

### 5. Conflict of Interest

None.

### 6. Source of Funding

None.

### References

1. Relhan V, Mahajan K, Agarwal P, Garg VK. Mycetoma: An Update. *Indian J Dermatol.* 2017;62(4):332–40. doi:10.4103/ijid.IJD\_476\_16.
2. Agarwal P, Jagati A, Rathod SP, Kalra K, Patel S, Chaudhari M, et al. Clinical Features of Mycetoma and the Appropriate Treatment Options. *Res Rep Trop Med.* 2021;12:173–9. doi:10.2147/RRTM.S282266.
3. Lichon V, Khachemoune A. Mycetoma: A review. *Am J Clin Dermatol.* 2006;7(5):315–21. doi:10.2165/00128071-200607050-00005.
4. Alam K, Maheshwari V, Bhargava S, Jain A, Fatima U, Haq EU, et al. Histological diagnosis of madura foot (mycetoma): a must for definitive treatment. *J Glob Infect Dis.* 2009;1(1):64–7.
5. Mathews S, Jadhav R, Reza A. Actinomycetoma-The Welsh Regimen in a Rural Indian Scenario. *Indian J Surg.* 2012;74(6):480–2. doi:10.1007/s12262-012-0481-0.
6. Ramam M, Bhat R, Garg T, Sharma VK, Ray R, Singh MK, et al. A modified two-step treatment for actinomycetoma. *Indian J Dermatol Venereol Leprol.* 2007;73(4):235–9. doi:10.4103/0378-6323.32888.
7. Zijlstra EE, Van De Sande W, Welsh O, Mahgoub ES, Goodfellow M, Fahal AH, et al. Mycetoma: a unique neglected tropical disease. *Lancet Infect Dis.* 2016;16(1):100–12.

### Author biography

Nivedha Priyanka A, Senior Resident

**Cite this article:** Nivedha Priyanka A. Mysterious mycetoma foot – A case series. *IP Indian J Clin Exp Dermatol* 2023;9(1):58-60.