

Content available at: <https://www.ipinnovative.com/open-access-journals>

IP Indian Journal of Clinical and Experimental Dermatology

Journal homepage: [www.ijced.org/](http://www.ijced.org/)

## Case Report

# Use of MatriDerm® (skin substitute) and split skin graft in one stage in wound healing of exposed tibia without periosteum in two patients

Sudhir Singh <sup>1,\*</sup><sup>1</sup>Dept. of Plastic Surgery, Getwell Hospital, Varanasi, Uttar Pradesh, India

### ARTICLE INFO

#### Article history:

Received 12-04-2023

Accepted 26-05-2023

Available online 03-07-2023

#### Keywords:

MatriDerm the skin substitute

Trauma

Diabetic wound

Split skin graft

Tibia bone denuded off periosteum

Single stage

### ABSTRACT

Reporting two cases one of two centimetres breadth and the other of four centimetres breadth exposed tibia bone devoid of periosteum due to post debridement involving periosteum elevator to remove infective tissue which was successfully covered by a simple procedure with MatriDerm® and split skin graft in a single stage. Tibia bone was not drilled to sprout granulation tissue from bone marrow to create a granulated vascularised bed for second-stage skin grafting. It avoided local flap or microsurgical free flap surgery for small exposed bone devoid of periosteum. Both cases had a pleasing aesthetic outlook after a few months of follow-up. Difficult to find instances of more than two centimetres of exposed tibia devoid of periosteum covered successfully in a single stage by this procedure.

This is an Open Access (OA) journal, and articles are distributed under the terms of the [Creative Commons Attribution-NonCommercial-ShareAlike 4.0 License](https://creativecommons.org/licenses/by-nc-sa/4.0/), which allows others to remix, tweak, and build upon the work non-commercially, as long as appropriate credit is given and the new creations are licensed under the identical terms.

For reprints contact: [reprint@ipinnovative.com](mailto:reprint@ipinnovative.com)

## 1. Introduction

Reporting two cases one of 2 cm breadth and the other of four centimetres breadth exposed tibia bone devoid of periosteum due to post debridement involving periosteum elevator to remove infective tissue were successfully covered by a simple procedure to cover with MatriDerm® and split skin graft in a single stage One study claimed to cover two centimetres breadth successfully in two out of six cases by this method.<sup>1</sup> This avoided the use of microsurgical-free flaps or local flaps and was aesthetically pleasing. Drilling of the tibia bone was not done to sprout granulation tissue from bone marrow to create a granulated vascularised bed and thus no need for second-stage skin grafting. It avoided local flap or microsurgical free flap surgery for small exposed bone devoid of periosteum.

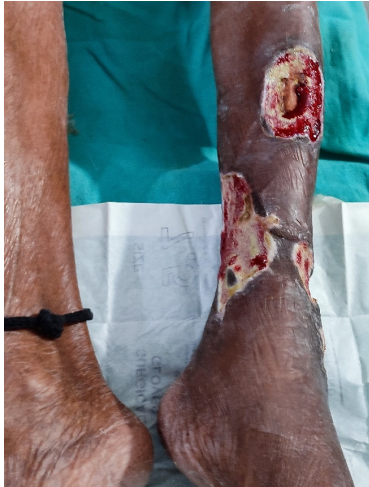## 2. Case 1

Eighty-seven years old man with irregularly controlled diabetes on oral antidiabetic treatment for the last 10 years had four weeks old infected wound over the left tibia [shin]. It was debrided and the infective wound bed was removed with a periosteal elevator thus bare bone devoid of periosteum was exposed. Two more wounds had also occurred over either side of the left ankle which was later skin grafted at the same time when the exposed bone was dealt. The incident was due to the patient slipping in the bathroom and swelling occurred in the lower half of the left leg and hot fomentation created a scald burn which ultimately got infected with a foul-smelling discharge within a week. Insulin and sensitive antibiotics were administered to this moribund patient. Pseudomonas infection controlled and regular dressing done. VAC at -125 mercury pressure was applied on all three wounds for one week. The exposed bone tibia wound was covered with single stage 37x52 mm MatriDerm® 1 mm thickness and very thin split skin graft. The wound on either side

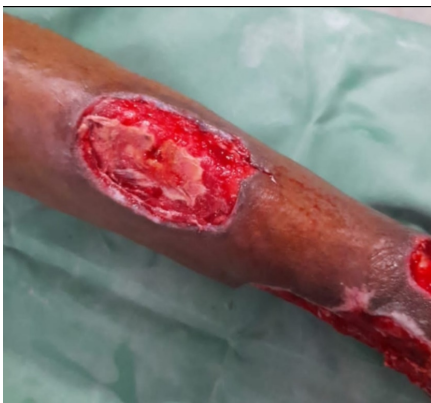\* Corresponding author.

E-mail address: [s.sulekha@gmail.com](mailto:s.sulekha@gmail.com) (S. Singh).

of the left ankle region with granulating soft tissue was also covered with a split skin graft of medium size. The dressing was done after seven days and a hundred per cent graft uptake was there. Proper diabetic control and sensitive antibiotics were continued. Wound dressings were repeated at 5 days intervals. The wound healed in three weeks' time and the follow-up at three months was aesthetically very pleasing (Figures 1, 2, 3, 4 and 5).



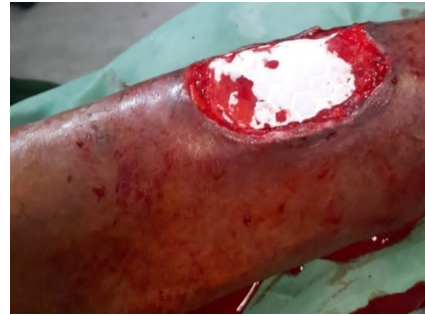**Fig. 1:** A Patient wound



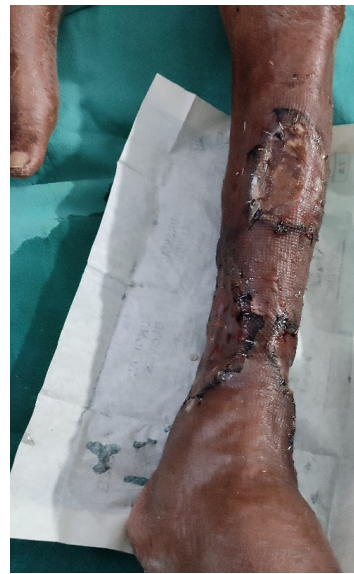**Fig. 2:** Exposed tibia bone devoid of periosteum.

### 3. Case 2

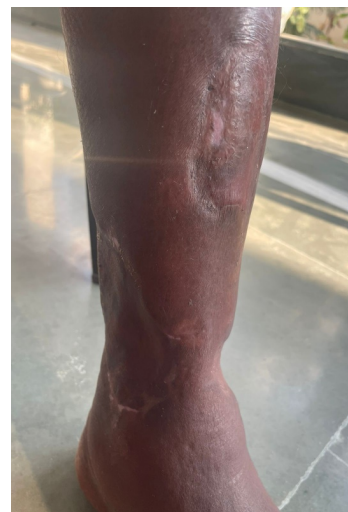The twenty-four-year-old male had a crush injury to his right lower limb. The external fixator was applied for the fracture of both bones at the lower one-third. Debridement of necrosed tissue and skin glove done. The tibial shaft with two-centimetre breadth and five-centimetre length without periosteum was exposed. The fracture site was covered with a retrograde posterior tibial artery flap. After five days single stage application of MatriDerm® and thin



**Fig. 3:** MatriDerm® applied



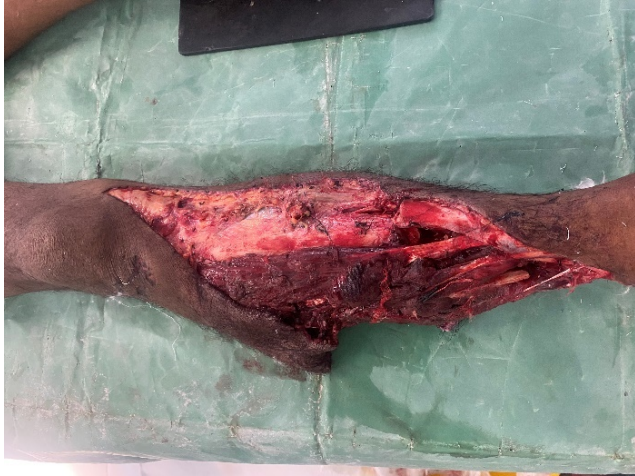**Fig. 4:** Also skin graft applied in a single stage



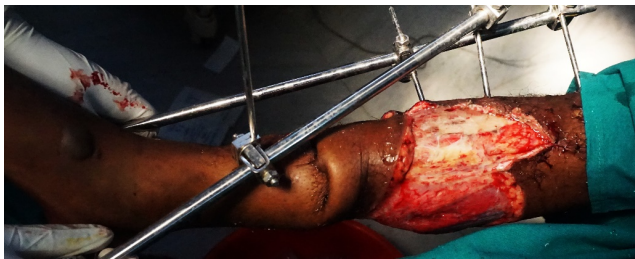**Fig. 5:** 3 months follow-up.



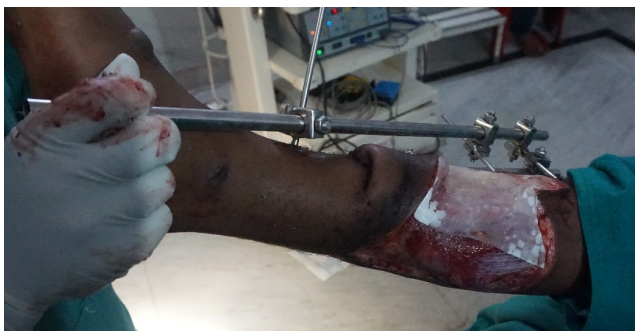split skin graft over the exposed bone and surrounding portion of the wound. The rest was covered with skin graft only. Later pseudomonas infection was encountered but managed successfully with bacteriophages and antibiotics. The wound healed in three weeks and later further orthopaedic management was done and a follow-up at five months was aesthetically pleasing(Figures 6, 7, 8, 9 and 10).



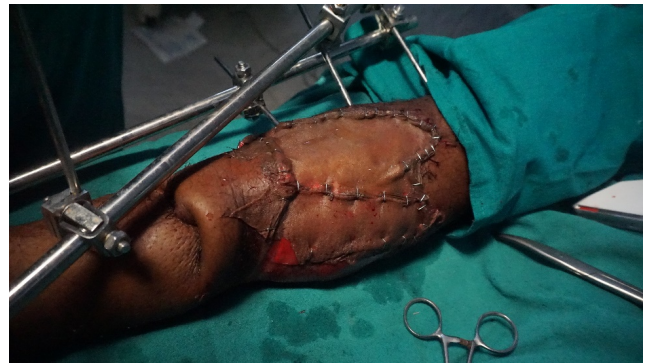**Fig. 6:** Road traffic injury with fracture and exposed bone shaft.



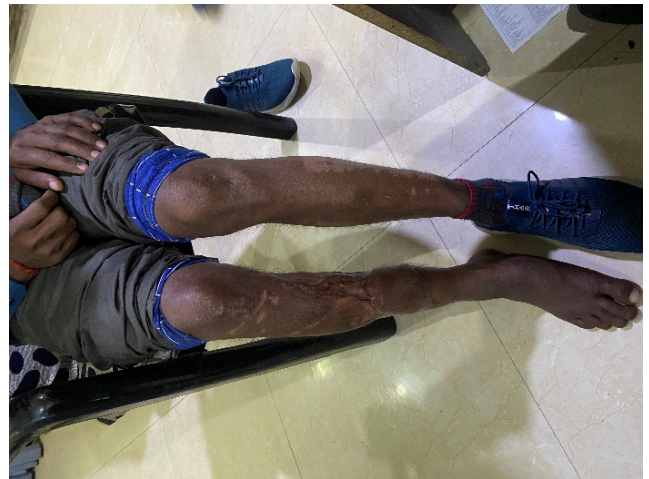**Fig. 7:** Fracture covered with flap and exposed shin bone is seen.



**Fig. 8:** MatriDerm applied



**Fig. 9:** Also added skin graft in single stage.



**Fig. 10:** Fig. 10: single stage matriDerm® + skin graft to cover exposed bone with 2cm breadth devoid of periosteum and soft tissue + pedicled flap to cover fracture site with Five months follow-up.

#### 4. Discussion

Only a few successful cases had been reported on the extensive periosteal devoid tibia to an extent of twelve centimetres in length but breadth not more than two centimetres indicating MatriDerm® was successful in healing by forming a bridge for growth of neovasculture from margins of the wound. Small wound devoid of any vasculature is covered easily by providing a scaffold through a skin substitute which gets vascularised at a faster rate to form a vascularised bed on which skin graft takes up easily.<sup>1,2</sup> In one study two cases out of six were successful.<sup>1</sup> Both cases of two centimetres and four centimetres breadth by us had been successful. Tibia bone exposed and devoid of periosteum to any length but breadth not gone beyond four centimetres defect could be healed by this method. Further study on more cases is required. This simple procedure avoided local flap or microsurgical free flap surgery. No occurrence of donor deformity. The skin substitute MatriDerm® had been used to cover successfully extensive

scalp bare bone without pericranium as the outer table was removed and immediately MatriDerm® with a skin graft was applied in the single stage or as the second stage after getting good granulation tissue by multiple drilling of the outer cortex of skull bone.<sup>3,4</sup> MatriDerm® is successfully used over the exposed bone of the extremity where periosteum is present or as the second stage after getting granulation tissue by multiple drilling of bone followed by VAC application. It needs vascularised tissue to imbibe neo-vascularization into its scaffold as done for donor site aesthetic purposes in post-radial forearm flap harvesting.<sup>5</sup> It is natural that skin substitutes should go beyond bare bone by one centimetre to cover the vascular area at the edges to get vascularised. The skin substitute behaves as a vascularised bridge to support a thin auto-skin split graft applied over it as a single stage. Both the cases healed through skin substitute as no loss of skin graft occurred and even the four centimetres wound breadth defect healed without much scarring of secondary intention.

## 5. Conclusion

MatriDerm® vascularised over the small exposed bone devoid of vascular periosteum to the extent of four centimetres breadth irrespective of length. No need for the drilling of bone required to sprout granulation tissue from bone marrow to create a granulation vascularised bed for second-stage skin grafting. It avoided local flap or microsurgical free flap surgery and thus donor deformity. Aesthetically pleasing result in three month time.

## 6. Conflict of Interest

There are no conflicts of interest in this article.


## 7. Source of Funding

None.

## References

1. Heckmann A, Radtke C, Rennekampff HO, Jokuszies A, Weyand B, Vogt PM, et al. [One-stage defect closure of deperiosteated bone and exposed tendons with MATRIDERM® and skin transplantation. Possibilities and limitations]. *Unfallchirurg*. 2011;115(12):1092–8. doi:10.1007/s00113-011-2003-0.
2. Morozzo U, Villafañe JH, Ieropoli G, Zompi SC, Cleland JA, Navissano M, et al. Soft Tissue Reconstructions with Dermal Substitutes Versus Alternative Approaches in Patients with Traumatic Complex Wounds. *Indian J Surg*. 2015;77(3):1180–6. doi:10.1007/s12262-015-1235-6.
3. Petrie K, Cox CT, Becker BC, Mackay BJ. Clinical applications of acellular dermal matrices: A review. *Scars Burn Heal*. 2022;8:20595131211038313. doi:10.1177/20595131211038313.
4. Bertolli E, Campagnari M, Molina AS, Macedo MP, Pinto CAL, Cunha IW, et al. Artificial dermis (MatriDerm(R)) followed by skin graft as an option in dermatofibrosarcoma protuberans with complete circumferential and peripheral deep margin assessment. *Int Wound J*. 2013;12(5):545–7. doi:10.1111/iwj.12157.
5. Burger A, Kiehlmann M, Gruenherz L. Donor Site Defect Coverage of the Forearm with Dermal Substitute After Harvesting Radial Forearm Free Flap for Phalloplasty: Is MatriDerm® Worth the Effort? *Indian J Surg*. 2023;doi:10.1007/s12262-023-03705-3.

## Author biography

**Sudhir Singh**, Hon. IMA Professor & Senior Consultant Plastic Surgery  
 <https://orcid.org/0000-0002-8242-6990>

**Cite this article:** Singh S. Use of MatriDerm® (skin substitute) and split skin graft in one stage in wound healing of exposed tibia without periosteum in two patients. *IP Indian J Clin Exp Dermatol* 2023;9(2):116-119.