

Content available at: <https://www.ipinnovative.com/open-access-journals>

IP Indian Journal of Clinical and Experimental Dermatology

Journal homepage: www.ijced.org/

Original Research Article

Role of dermoscopy in hyperpigmented skin disorders: A tertiary care centre experience

Rutu Harsh Oza^{1*}, Shreya Agrwal², Jaydipkumar Tank³, Amita Sutaria⁴,
Kirti S Parmar⁴, Bela J Shah⁴, Navin R Chaudhary⁵, Kriteeka Saini⁶, Harshita Vyas⁴,
Shikha R Shah⁷, Deval Mistry⁸

¹Alvura Skin Clinic, Ahmedabad, Gujarat, India²Gupta Life Care Hospital, Hanumangarh, Rajasthan, India³GMERS Medical College, Junagadh \ Junagad, Junagadh, Gujarat, India⁴Dept. of Dermatology, Civil Hospital, Ahmedabad, Gujarat, India⁵Navin Skin Clinic, Patan, Gujarat, India⁶Consultant Dermatologist, Madhya Pradesh, India⁷Dept. of Dermatology, Postgraduate Institute of Medical Education & Research (PGIMER), Chandigarh, India⁸Dr. R R Gupta Skin Clinic, Ahmedabad, Gujarat, India

ARTICLE INFO

Article history:

Received 28-11-2023

Accepted 10-11-2023

Available online 05-01-2024

Keywords:

Dermoscopy

hyperpigmented disorders

Indian

ABSTRACT

Introduction: Dermoscopy, performed with a handheld instrument called dermatoscope, is a non-invasive and in-vivo technique for the evaluation of various skin lesions in clinical practice. Although many studies have shown the importance of dermoscopy in diagnosing skin lesions by supplementing naked-eye evaluation, Indian data on its usefulness is scarce. We aimed to describe dermoscopic findings in various pigmented conditions in skin of colour.

Materials and Methods: A retrospective observational study was carried out in a tertiary care hospital in western India for the period of two years- October 2015 to September 2018. Patients were selected from the available records by using pre-specified selection criteria. Detailed demographic and clinical parameters were recorded. The dermoscopic examination was done using DermLite DL3 polarised device. The histopathological findings, when available, were also evaluated.

Results: A total of 352 patients were identified, 181 males and 171 females. Out of the total number, 272 patients had melanocytic and 80 had non-melanocytic lesions. Benign melanocytic nevi (100 out of 272) and seborrheic keratosis (58 out of 70) were the most common observations for melanocytic and non-melanocytic lesions respectively.

Conclusion: The study provides real-world data on a large scale for dermoscopic findings in hyperpigmented lesions in Indian patients. This study corroborates with observations from previous studies to suggest quick and non-invasive use of dermoscopy for reliable diagnosis. Larger studies in future may obviate the need for biopsy while managing these patients.

This is an Open Access (OA) journal, and articles are distributed under the terms of the [Creative Commons Attribution-NonCommercial-ShareAlike 4.0 License](https://creativecommons.org/licenses/by-nc-sa/4.0/), which allows others to remix, tweak, and build upon the work non-commercially, as long as appropriate credit is given and the new creations are licensed under the identical terms.

For reprints contact: reprint@ipinnovative.com

1. Introduction

Dermoscopy, a non-invasive tool to examine microscopic details of skin lesions, allows visualization of surface and subsurface structures. Dermatoscope permits a better

* Corresponding author.

E-mail address: rutujoshi1370@gmail.com (R. H. Oza).

appreciation of morphology not visible by naked eye, thus opening a new dimension of evaluation.¹ ‘Dermoscopy’ term was introduced in 1921 by Saphier.² The first world dermoscopy congress, held in Rome in 2001, defined various structures seen in benign and malignant pigmentary disorders.³

Pigmented skin disorders are one of the most frequently encountered conditions in routine dermatology practice. This may be difficult to diagnose by gross macroscopic examination, specifically for Indian patients with dark skin. Dermoscopy helps to differentiate between melanocytic and non-melanocytic pigmented lesions and aids in diagnosing early malignant changes.⁴

Literature review suggested a paucity of real-world data from Indian patients for the role of dermoscopy in clinical practice. This study aimed to provide dermoscopic findings from Indian patients with various pigmented lesions.

2. Materials and Methods

A retrospective analysis was done from the evaluation of hospital records, for patients who presented to the dermatology outpatient department at tertiary care centre in western India, during the period of October 2015 to September 2018. Prior approval was taken from the Institutional Ethics Committee. All patients (both sex and age above 18 years) who had presented during the study period with hyperpigmented skin lesions were included in the study. Patients who had taken any treatment in last six months for the same were excluded. Informed consent was obtained from all patients. After a thorough clinical assessment, the dermoscopic examination was done for each patient using a dermatoscope (Dermlite DL3 - San Juan, Capistrano, CA, USA), with 10x magnification keeping approximately a distance of 1 inch from the skin surface. Dermoscopic findings were captured using a high-resolution camera.

All demographic, clinical, and dermoscopic details were collected in a pre-decided format. Punch skin biopsy was also performed in a few patients with equivocal results of clinical and dermoscopic findings.

A two-step method for dermoscopic classification of pigmented lesions was used: First, the lesions were differentiated as melanocytic versus non-melanocytic by the algorithm approved by Consensus Net Meeting Board, and then the lesions were further categorized as benign or malignant using the seven-point checklist method.⁵

3. Results

Total 352 patients satisfied selection criteria, 181 males (51.42%) and 171 females (48.57%). Punch biopsy results were also available for 105 patients. The maximum number of patients was in the age group of 21-30 years with the mean age being 35.5 years. Approximately 46% of the

patients had a single lesion and the remaining 54% had multiple pigmented lesions.

Patients were divided into two categories clinically based on lesion characteristics as melanocytic and non-melanocytic lesions. Table 1 outlines the number of patients in each category.

Table 1: Number of patients with melanocytic & non-melanocytic lesions

Category (n=total number in each category)	Disease	Number of patients (Total = 352)
Melanocytic lesions (n = 272)	Melanocytic nevus	100
	Melasma	52
	Lichen planus pigmentosus	50
	Freckles or lentiginos	30
	Beckers nevus	25
	Ashy dermatosis	5
	Exogenous oochronosis	4
	Melanoma	4
	Bowen's disease	2
	Non-melanocytic lesions	Seborrheic keratosis
Basal cell carcinoma (BCC)		22

3.1. Dermoscopic findings

3.1.1. Local features

The most common local feature observed was pigment network, seen in 45.2% of patients, followed in descending order by milia-like cysts, comedo-like openings, and blue-whitish veil; seen in 21.4%, 19% and 2.4% of patients respectively.

3.1.2. Global features

The most common global feature was reticular pattern; seen in 38.1% of patients. The other global features noted were parallel pattern in 9.5% of patients, globular pattern in 7.1%, and homogeneous pattern in 2.4% of patients.

elow provides details of various dermoscopic findings observed in patients with different hyperpigmented conditions.

3.1.3. Dermoscopic findings in melanocytic group

The most common clinical diagnosis for this category was benign melanocytic nevi. Out of 100 patients with benign melanocytic nevi, 30 patients had congenital whereas 70 patients had acquired lesions. Within the congenital variety, 28 out of 30 patients showed symmetrical findings. Twenty four out of thirty patients showed target networks. The next

common observations in the congenital subtype, after the target network, were homogeneous diffuse pigmentation and blue-grey globules, seen in 20 and 19 patients respectively. Figure 1a shows clinical picture of congenital melanocytic nevus and Figure 1b shows associated dermoscopic findings- homogenous diffuse pigmentation, focal thickening of network lines, and terminal hair follicles. On the other hand, in the acquired subtype, reticular (38%) and globular (33%) networks were the most common findings with other patterns found less frequently. Figures 2 and 3 illustrate clinico-dermoscopic pattern of junctional and compound subtypes of acquired nevus respectively. Out of the 52 patients with the diagnosis of melasma, 42 (84%) had generalized brown pigmentation with a spared follicular opening. Figure 4a and c are clinical pictures of two different patients with melasma whereas Figure 4b and d depicts their respective dermoscopic findings. Similar dark brown pigmentation was present on dermoscopic examination in all 50 patients with clinically diagnosed lichen planus pigmentosus. Seventy percent of these patients also had pigment accentuation around acrosyringium. [Figure 5 shows two patients with lichen planus pigmentosus involving face and legs respectively, with their dermoscopic and biopsy correlates]. In patients with freckles and lentigines, uniform pigmentation with moth-eaten edge and dark uniform network were the exclusive dermoscopic finding as shown in Figure 6. The majority (92%) of patients with Becker's nevus showed increased hair follicles around the affected region (Figure 7). All four patients with exogenous ochronosis had arciform streaks. (Figure 8 shows two patients with corresponding clinical / dermoscopic / histological features of exogenous ochronosis) Similarly, all melanoma patients showed atypical pigment network. Figure 9a and d are clinical pictures from patients with melanoma. Figure 9b and e are classic dermoscopic findings of ulceration and atypical pigment network in these patients. Figure 9c and f are biopsy pictures from the same patients with presence of melanocytes. Patients with ashy dermatosis showed grey-blue pigmentation and bluish-black pigmentation (in 3 out of 5 for each finding) and brownish dots (in 2 out of 5 patients).

3.1.4. Dermoscopic findings in non-melanocytic group

Among the 80 patients with non-melanocytic lesions, 58 had seborrheic keratosis and remaining 22 had basal cell carcinoma. As seen in Table 2, seven different dermoscopic findings were found in patients with seborrheic keratosis. Figure 10 shows three patients with seborrheic keratosis involving different areas with their respective dermoscopic features. (Figure 10e also highlights histo-pathologic findings in seborrheic keratosis) The most prevalent dermoscopic findings in these patients were fissures and ridges (77%) (Figure 10b), comedo-like openings (69%),

and cerebriform structures (60%). Patients with basal cell carcinoma, on dermoscopy, showed asymmetrical findings in the majority (90%). Other predominant findings in basal cell carcinoma were ulcerations (81%), large ovoid nests (77%), and vascular structures (7%) (Figure 11b illustrates dermoscopic features of BCC- large black grey ovoid nests, linear blood vessels, micro-ulceration and keratotic scales and Figure 11 a and c show clinical and biopsy correlates)

4. Histopathological findings

Only 105 patients had undergone a biopsy out of the total of 352 in the study. As shown in Table 3, the maximum results for patients undergoing biopsy were showing seborrheic keratosis and basal cell carcinoma with 21 and 20 patients respectively. This also pointed out that more than half of the patients with non-melanocytic lesions required biopsy for confirmation. Interestingly, 102 out of 105 patients with biopsy results had dermoscopic findings suggestive of a similar diagnosis. One patient with biopsy confirmed basal cell carcinoma had dermoscopic findings in favour of Bowen's disease and two patients of biopsy confirmed lichen planus had dermoscopy suggestive of ashy dermatosis.

5. Discussion

Hyperpigmented skin lesions are a wide spectrum of skin disorders that includes both melanocytic and non-melanocytic skin lesions. It is important to differentiate benign from malignant for the correct line of treatment. As it may not be feasible to take a biopsy in all cases, non-invasive alternatives such as dermoscopy can aid in diagnostic certainty to the naked eye observation.

Pigmented lesions can be melanocytic or non-melanocytic. Observation of pigmentation in dermoscopy can be correlated with melanin within keratinocytes or melanocytes. Dermoscopy can suggest melanocytic lesions by the presence of a pigment network, pseudo network, aggregated globules, branch streaks, and parallel patterns. On the other side, non-melanocytic lesions have different characteristic findings. Seborrheic keratosis presents as milia-like cysts, comedo-like openings, fissures and ridges, sharp demarcation with fingerprint-like structures, and hair pin-like blood vessels while pigmented BCC shows arborizing vessels, maple leaf-like areas, spoke wheel areas with ulcerations.⁶

In our study, 69% of patients with seborrheic keratosis had comedo-like openings which can be correlated pathologically with keratin-filled follicular openings. Another feature, milia-like cysts, found in 43.10% of patients with seborrheic keratosis, can be correlated with intraepidermal horn cysts. Similar results were seen in the study done by Rajesh G et al⁷ where fissures and ridges were seen in 100% of patients (77.59% in the present study)

Table 2: Number of patients with diverse dermoscopic findings in various hyperpigmented conditions

Category (Total number of patients)	Condition (N= number of patients)	Dermoscopic findings	Number of patients with each specific finding (percentage)	
Melanoc-ytic lesions (272)	1. Benign melanocytic nevi (100) [Congenital-30 & Acquired-70]	Congenital type: (Total 30)	Symmetry	28 (93.33%)
			Target network	24 (80%)
			Homogeneous diffuse pigmentation	20 (66.66%)
			Blue-grey globules	19 (63.33%)
			Blotches	16 (53.33%)
			Perifollicular pigmentation	11 (36.66%)
			Focal thickening of network	10 (33.33%)
			Reticular network	27 (38.54%)
			Globular pattern	23 (32.85%)
			Parallel pattern	14 (20%)
			Cobble-stone pattern	2 (2.85%)
			Homogeneous pattern	2 (2.85%)
			Multi-component pattern	1 (1.42%)
			Non-specific pattern	1 (1.42%)
			2. Melasma (52)	Diffuse brown pigmentation with sparing of the follicular opening Diffuse dark brown to grey pseudo-reticular pigmentation Dark brown pigmentation
	10 (16%)			
	50 (100%)			
	3. Lichen planus pigmentosus (LPP) (50)	Pigment accentuation around acrosyringium Heterogeneous colour distribution Granular deposits Pigment in a hem-like pattern Wickham's striae.	35 (70%)	
			30 (60%)	
			30 (60%)	
			15 (30%)	
			05 (10%)	
	4. Freckles and lentiginos (30)	Uniform pigmentation with moth-eaten edge Dark uniform network Increased hair follicles in affected areas	29 (97%)	
			8 (27%)	
			23 (92%)	
	5. Becker's nevus (25)	Pigment network Skin furrow hypopigmentation.	20 (80%)	
			13 (52%)	
6. Ashy dermatosis (5)	Grey-blue dots Bluish black pigmentation Brownish dots	3 (60%)		
		3 (60%)		
		2 (40%)		
7. Exogenous ochronosis (4)	Irregular brown or grey globular, annular, and arciform streaks	4 (100%)		
8. Melanoma (4)	Atypical pigment network Regression structures, vascular structures, irregular dots, and globules, bluish-white veil Irregular streaks on dermoscopy	4 (100%)		
		2 (50%)		
		1 (25%)		
9. Bowen's disease (2)	Atypical vascular structures or glomerular vessels Homogenous areas of greyish pigmentation Fissures and ridges	2 (100%)		
		1 (50%)		
		45 (77.59%)		
Non- melanocytic lesions (80)	1. Seborrheic keratosis (58)	Comedo like openings	40 (69%)	
		Cerebriform structures	35 (60.34%)	
		Fingerprint like pattern	28 (50%)	
		Milia like cysts	25 (43.10%)	
		Blue grey globules	12 (20.69%)	
	Asymmetry in dermoscopic findings	20 (90.91%)		
	Ulcerations or erosions	18 (81.81%)		
7. Basal cell carcinoma (22)	Large blue-grey ovoid nests Vascular structures Blue-grey globules Spoke wheel areas Maple leaf-like areas	17 (77.27%)		
		16 (72.73%)		
		15 (68.18%)		
		5 (22.73%)		
		3 (13.64%)		

Table 3: Number of patients with various diagnoses based on histopathology

Histopathological diagnosis	Number of patients
Seborrheic keratosis	21
Basal cell carcinoma pigmented variant	20
Lichen planus pigmentosus	20
Acquired melanocytic nevi	18
Melasma	07
Freckles	06
Melanoma	04
Exogenous ochronosis	02
Pigmented Bowen's disease	02

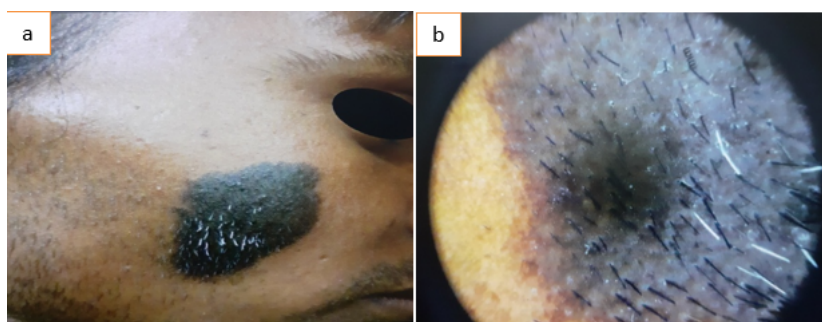


Figure 1: Congenital melanocytic nevus; **a:** Congenital melanocytic nevus clinical photograph; **b:** Dermoscopic picture shows homogenous diffuse pigmentation, focal thickening of network lines, terminal hair follicles

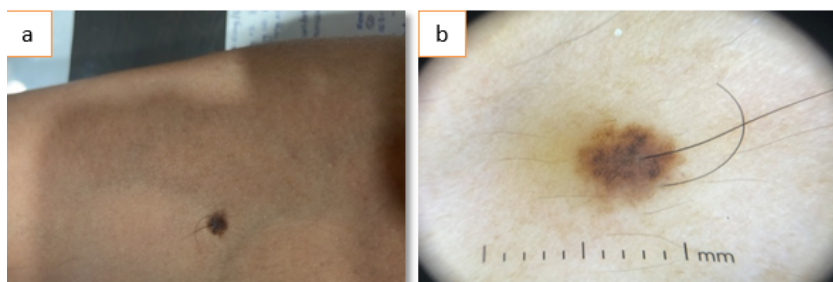


Figure 2: Acquired junctional melanocytic nevus; **a:** Acquired melanocytic nevus on forearm; **b:** Reticulo – globular pattern with homogenous pigmentation;

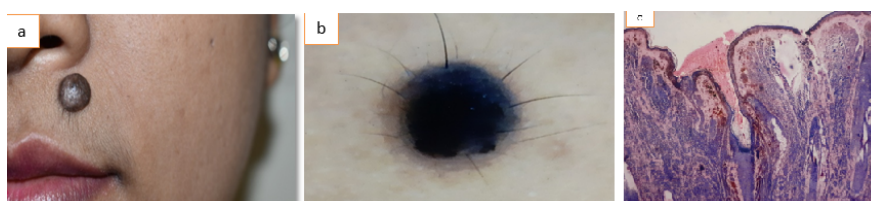


Figure 3: Acquired compound melanocytic nevus; **a:** Clinical picture of acquired compound melanocytic nevus on face; **b:** Homogenous diffuse pigmentation with symmetry; **c:** Histopathologic picture of benign melanocytic nevus showing melanin in basal layer and in the upper dermis.

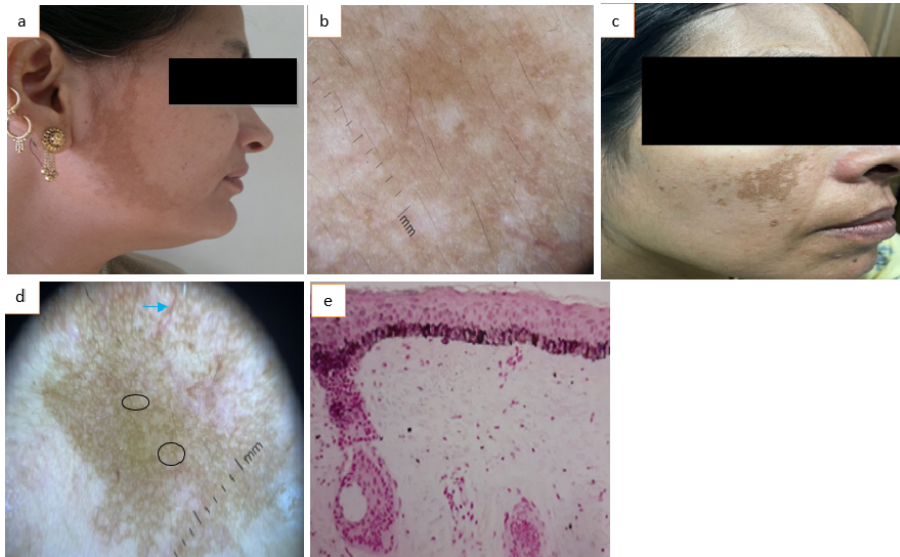


Figure 4: Melasma; **a:** Clinical picture of melasma; **b:** Exaggerated pseudo reticular pigment network superimposed by reticulo – globular pattern of brown pigment; **c:** clinical picture of melasma; **d:** Granules and dots of pigment (black circle) & Telangiectasias (blue arrows); **e:** Histology of melasma showing hyper-pigmented basal layer

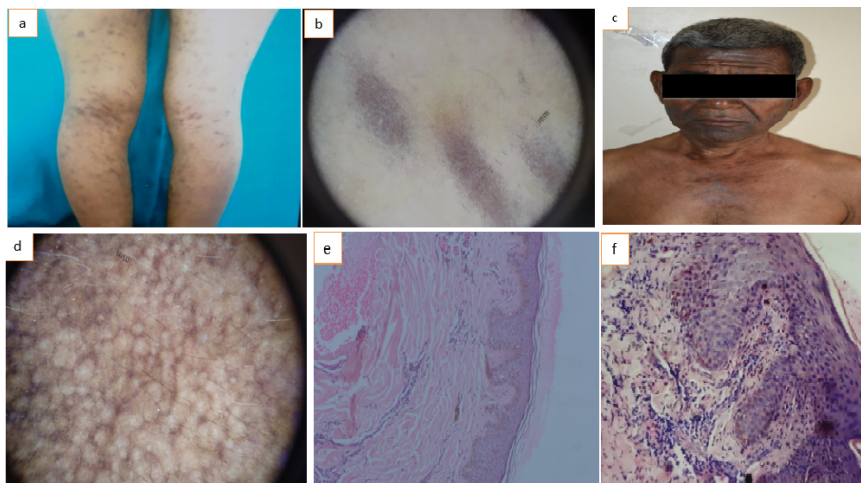


Figure 5: Lichenplanus pigmentosus; **a:** Clinical picture of Lichen Planus Pigmentosus (LPP); **b:** Dark brown pigmentation with granular deposits; **c:** Clinical picture of LPP; **d:** Dark brown pigmentation with perifollicular pigment accentuation; **e:** Histopathology of patient -a, shows pigmented basal layer vacuolization with pigment incontinence, dermal melanophages, and perivascular lymphocytic infiltrate; **f:** Histopathology of patient -a, shows pigmented basal layer vacuolization with pigment incontinence, dermal melanophages, and perivascular lymphocytic infiltrate

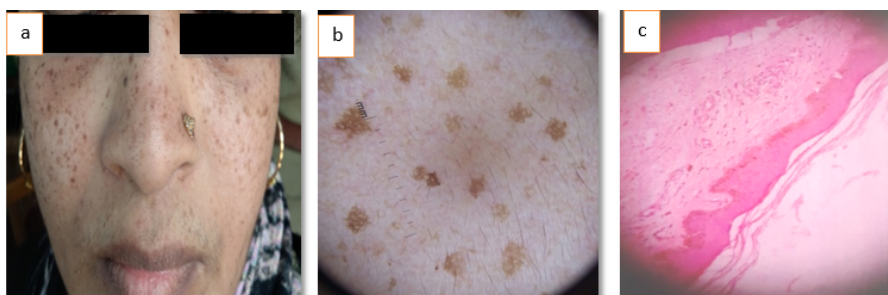


Figure 6: Freckles; **a:** Clinical picture of freckles; **b:** Uniform pigmentation with moth eaten border; **c:** Hyperpigmentation of basal layer

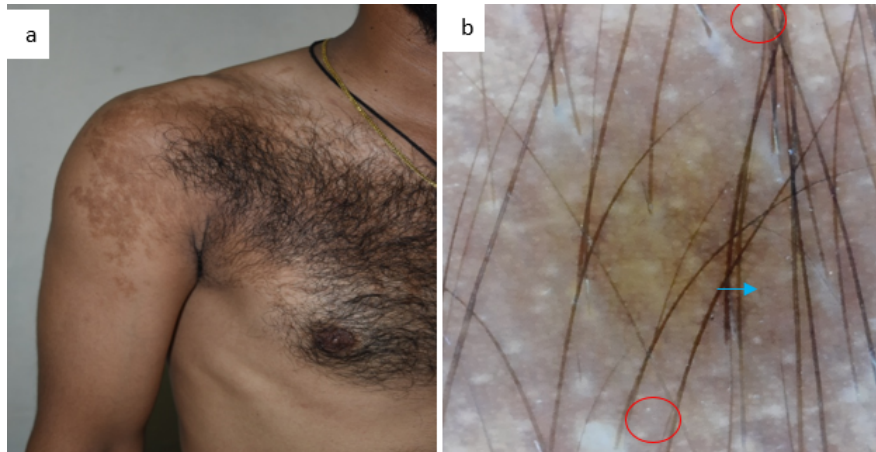


Figure 7: Becker's nevus; **a:** Clinical picture of Becker's nevus; **b:** Reticular pigment network with perifollicular hypo-pigmentation (red circle) & presence of terminal hair (blue arrow)

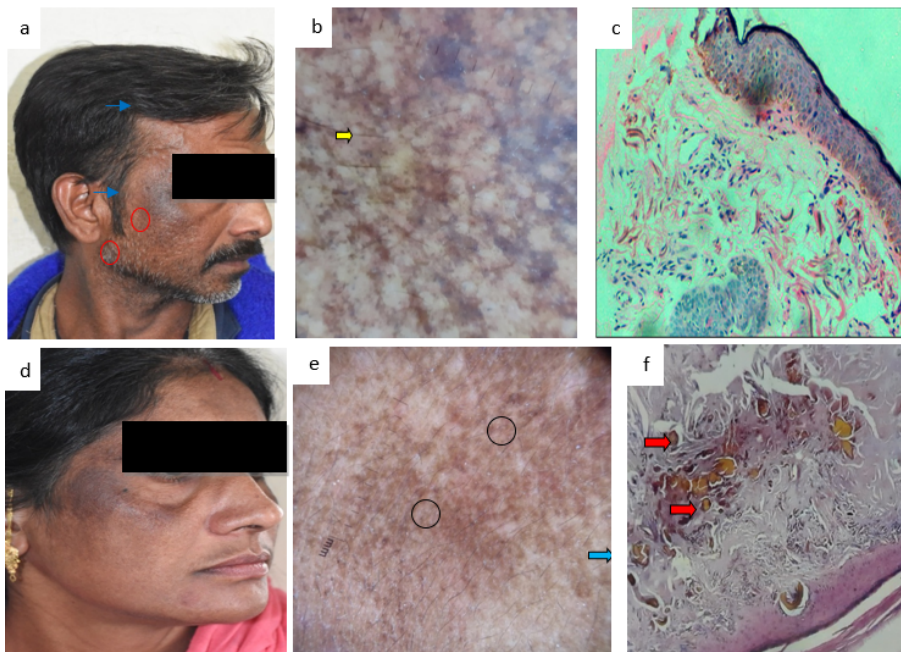


Figure 8: Exogenous ochronosis; **a:** Clinical picture of exogenous ochronosis; **b:** Perifollicular diffuse blue grey pigmentation with obliteration of few openings, arciform brown structures (blue arrow), curvilinear and globular structures (red circle); **c:** Histopathological picture of exogenous ochronosis with multiple yellowish exogenous material (banana shaped bodies) in papillary and middle dermis (yellow arrow); **d:** Clinical picture of exogenous ochronosis; **e:** Brown globules and dots in diffuse pattern (black circle), with perifollicular brown gray amorphous structures (blue arrow); **f:** Histopathological picture of exogenous ochronosis with yellow to brown coloured exogenous material (banana shaped bodies) in papillary and middle dermis (red arrow)

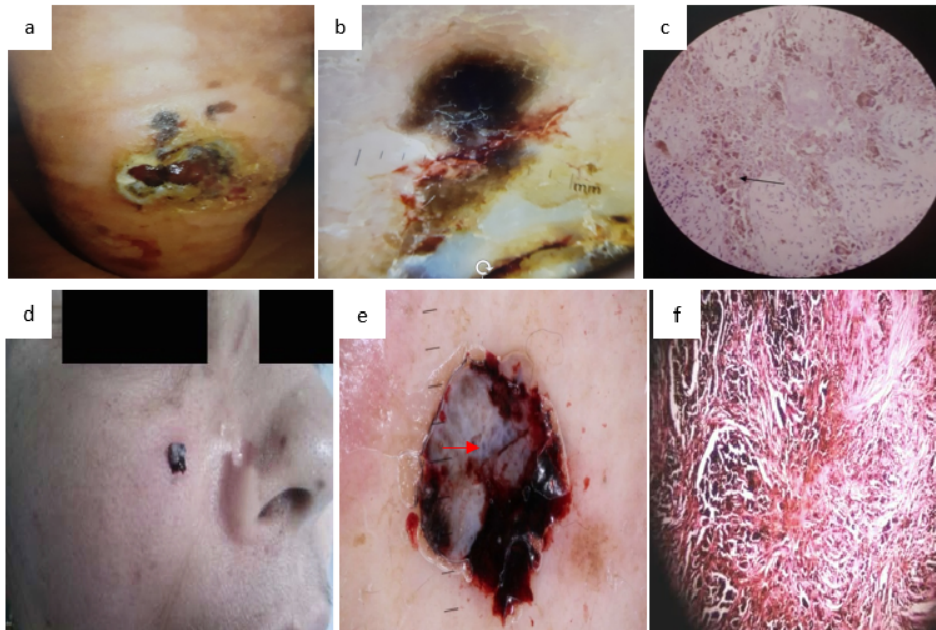


Figure 9: Melanoma; **a:** Clinical picture of acral melanoma; **b:** Dermoscopy shows ulceration and atypical pigment network; **c:** Histopathology shows melanoma cells in dermis; **d:** Clinical picture of melanoma; **e:** Dermoscopy shows blue-white veil (red arrow), ulceration and vascular structures, atypical pigment network in periphery; **f:** Histopathology shows multiple malignant melanocytes in clusters

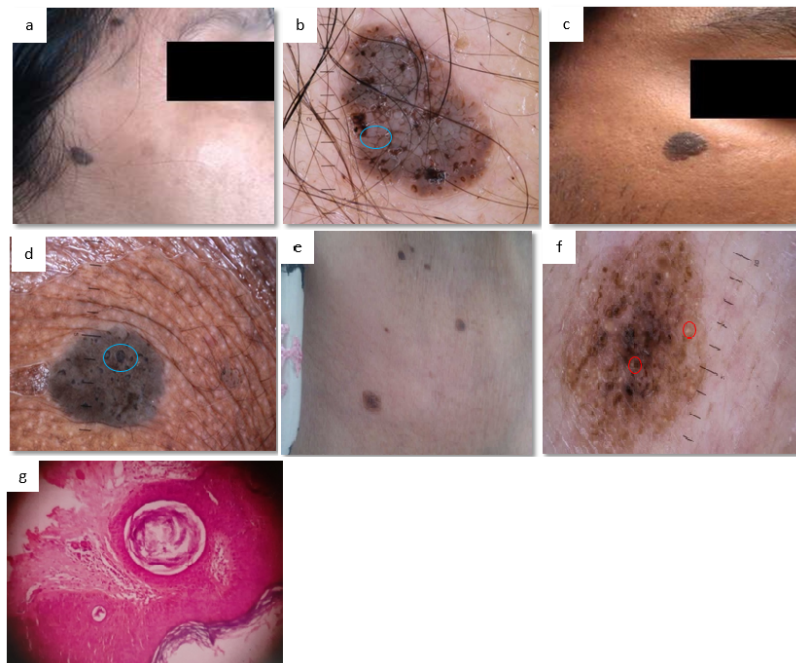


Figure 10: Seborrheic keratosis; **a:** Clinical picture of seborrheic keratosis; **b:** Dermoscopy shows sharply demarcated lesion with multiple milium like opening, multiple fissures and ridges giving an appearance of cerebriform pattern (blue circle); **c:** Clinical picture of seborrheic keratosis; **d:** Dermoscopy shows sharply demarcated lesion with multiple comedo like opening (blue arrow) and milium like opening; **e:** Clinical picture of seborrheic keratosis; **f:** Dermoscopy shows sharply demarcated lesion with multiple milium like opening (red circle), pseudofollicular opening, moth eaten border; **g:** Histopathology shows basket weave stratum corneum, basaloid proliferation in stratum malpighii, increase melanin pigment and keratin horn cyst

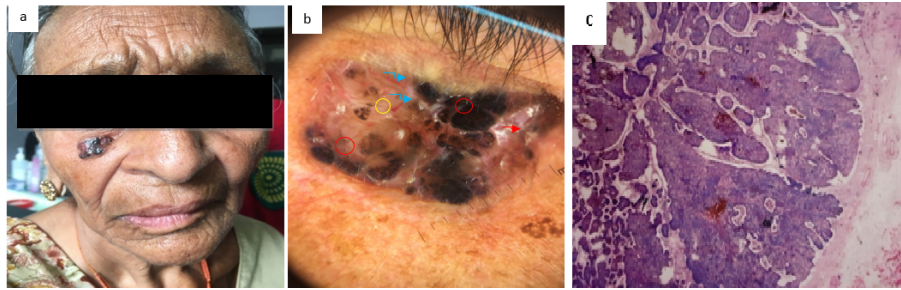


Figure 11: Basal cell carcinoma; **a:** Clinical picture of pigmented basal cell carcinoma (BCC); **b:** Dermoscopy shows multiple large black-grey ovoid nests (red circle), linear blood vessels (blue arrow), keratotic scale (red arrow), micro ulceration (yellow circle); **c:** Histopathology shows basaloid cells and melanin in the dermis

and comedo-like openings in 64% (69% in the present study).

Dermoscopic features of pigmented BCC were first reported by Puspok-Schwartz et al.⁸ In this report, findings from 25 BCC patients were compared with 25 melanomas. Arborizing vessels were found in 52% of pigmented BCC and described as the strongest model for diagnosing BCC. In our study we found 72.73% pigmented BCC with arborizing vessels. The basal cell carcinoma dermoscopically showed erosions/ulcerations in 81.81% of patients in the present study. These erosions were one of the defining features of BCC as shown by Menzies et al.⁹ In 2005, Menzies et al defined dermoscopic features of pigmented BCCs. According to them, diagnosis of pigmented BCC is based on the absence of a pigment network with the presence of at least one of the following features: arborizing vessels, large blue-grey ovoid nests, multiple grey-blue globules, ulceration, maple leaf-like areas, spoke wheel areas.

The present study included 50 patients of lichen planus pigmentosus, where dark brown pigment network was seen in 100 % of patients and pigment accentuation around acrosyringium was observed in 70%. Similar findings were seen in a study by Gungor S et al¹⁰ where the numbers for dark brown pigment network and pigment accentuation around acrosyringium were 100% and 53.3% respectively.

In the present study, in patients with ashy dermatosis, grey-blue dots with blue-black pigmentation were found in 60% of patients while 40% of cases had brownish dots. The findings corroborated with the study of Garg P. et al¹¹ where brownish dots were seen in 50% of cases and blue-grey dots in 25% of cases.

In patients with junctional nevi, the prevalent pattern of reticular pigmentation was associated with the presence of nevoid cells at the dermo-epidermal junction, whereas in patients with compound nevi, the common globular pigment pattern represented the presence of nevoid cells both in the basal layer and dermis. These findings were in accordance with the findings of Zalaudek I et al.¹² Reticular pattern was noted more frequently in the present study due to the rete ridge pattern of the epidermis,

in which relatively hypopigmented dots represent dermal papillae and overlying epidermis. The globular pattern was commonly seen in patients with compound nevi presenting as homogenous globules distributed throughout the lesion. These globules were more than 0.1mm in size and represent a nest of melanocytes. The cobblestone pattern is formed by a conglomeration of these globules,¹³ which was observed in 2% of cases of acquired melanocytic nevi.

In patients with melanoma, dermoscopic findings of irregular pigment network corresponded histologically to the presence of invasive melanoma cells in the epidermis/ upper dermis, whereas blue-white veil corresponded to lymphocytes or melanophages in the dermis. The vascular structures dermoscopically corresponded to intense vascularisation with different sizes of vessels. Similar correlations were described by Ungureanu et al.¹⁴ Even though melanoma incidence is relatively low in India, it was noted in 1.13% of patients (4 patients) in our study.

The present study showed 25 patients of Becker's nevus, with increased terminal hair follicles in the affected area (92%), pigment network (80%), and furrow hypopigmentation (52%) being the commonest findings. These results were in concordance with the study done by Ingordo V et al with 64 patients of Becker's nevus.¹⁵

Out of the total 52 melasma patients, 42 patients (84%) showed diffuse brown pigmentation with sparing of follicular opening and 10 patients (16%) had diffuse dark brown to greyish pseudoreticular pigmentation on dermoscopy. Our findings were in agreement with dermoscopic findings of melasma mentioned by Dr Sarkar R et al.¹⁶ All four patients of Exogenous oochronosis showed irregular brown/grey globular, annular and arciform streaks on dermoscopy as described similarly by Gil et al.¹⁷ Dermoscopy aided in differentiating melasma from exogenous oochronosis by the presence of dark brown or grey accentuated reticular pseudo network in the former versus arciform pattern in the later.

Both patients with Pigmented Bowen's disease showed glomerular vessels and one of them had homogeneous areas of greyish pigmentation on dermoscopy which is consistent

with findings described by Hernandez-Gil et al.¹⁸

In our study, dermoscopy could differentiate melanocytic versus non-melanocytic pigmented lesions. It also helped in diagnosis of clinical look-alike lesions such as melasma versus exogenous ochronosis, and lichen planus pigmentosus versus ashy dermatosis. The disappearance of dermoscopic disease-specific findings on follow-up also provided a clue for response to treatment.

6. Study Limitation

This was a retrospective single-centre study.

7. Conclusion

Our study provides valuable data for dermoscopic findings of various hyperpigmented lesions in clinical practice. It helps to bridge the gap between confirmatory biopsy findings and clinical observations. The use of dermatoscope on a routine basis may help to increase precision in hyperpigmented skin lesions without the need for invasive biopsy. Further large-scale multi-centric studies are required to compare findings of dermoscopy with confirmatory biopsy results.

8. Conflict of Interest

None.

9. Conflict of Interest


None.

References

1. Soyer HP, Argenziano G, Chimenti S, Ruocco V. Dermoscopy of pigmented skin lesions. *Eur J Dermatol*. 2001;11(3):270–6.
2. Saphier J. Die Dermatoskopie. *Arch f Dermat*. 1921;128:1–19. doi:10.1007/BF01991493.
3. Marghoob AA, Malvehy J, Braun RP. An Atlas of Dermoscopy. Baton Rouge, United states: CRC Press; 2004.
4. Kaliyadan F. The scope of the dermatoscope. *Indian Dermatol Online J*. 2016;7(5):359–63.
5. Malvehy J, Puig S, Argenziano G, Marghoob AA, Soyer HP. International Dermoscopy Society Board members. Dermoscopy report: proposal for standardization. Results of a consensus meeting of the International Dermoscopy Society. *J Am Acad Dermatol*. 2007;57(1):84–95.
6. Braun RP, Rabinovitz HS, Oliviero M, Kopf AW, Saurat JH. Dermoscopy of pigmented skin lesions. *J Am Acad Dermatol*. 2005;52(1):109–21.
7. Rajesh G, Thappa DM, Jaisankar TJ, Chandrashekar L. Spectrum of seborrheic keratoses in South Indians: a clinical and dermoscopic study. *Indian J Dermatol Venereol Leprol*. 2011;77(4):483–8.
8. Püspök-Schwarz M, Steiner A, Binder M, Partsch B, Wolff K, Pehamberger H, et al. Statistical evaluation of epiluminescence microscopy criteria in the differential diagnosis of malignant melanoma and pigmented basal cell carcinoma. *Melanoma Res*. 1997;7(4):307–11.
9. Menzies SW, Westerhoff K, Rabinovitz H, Kopf AW, Mccarthy WH, Katz B, et al. Surface microscopy of pigmented basal cell carcinoma.

10. Güngör Ş, Topal IO, Göncü EK. Dermoscopic patterns in active and regressive lichen planus and lichen planus variants: a morphological study. *Dermatol Pract Concept*. 2015;5(2):45–53.
11. Garg P, Kaur T, Malhotra SK, Singh A. Study of the Dermoscopic Findings and Their Correlation with Histopathological Findings in Various Lichenoid Dermatoses. *J Clin Exp Dermatol Res*. 2015;6:308–308.
12. Zalaudek I, Docimo G, Argenziano G. Using dermoscopic criteria and patient-related factors for the management of pigmented melanocytic nevi. *Arch Dermatol*. 2009;145(7):816–26.
13. Rao BK, Wang SQ, Murphy FP. Typical dermoscopic patterns of benign melanocytic nevi. *Dermatol Clin*. 2001;19(2):269–84.
14. Ungureanu L, Şenilă S, Dănescu S, Rogoian L, Cosgarea R. Correlation of dermatoscopy with the histopathological changes in the diagnosis of thin melanoma. *Rom J Morphol Embryol*. 2013;54(2):315–20.
15. Ingordo V, Iannazzone SS, Cusano F, Naldi L. Dermoscopic Features of Congenital Melanocytic Nevus and Becker Nevus in an Adult Male Population: An Analysis with a 10-Fold Magnification. *Dermatology*. 2006;212(4):354–60.
16. Sarkar R, Arora P, Garg VK, Sonthalia S, Gokhale N. Melasma update. *Indian Dermatol Online J*. 2014;5(4):426–35.
17. Gil I, Segura S, Martínez-Escala E, Lloreta J, Puig S, Vélez M, et al. Dermoscopic and reflectance confocal microscopic features of exogenous ochronosis. *Arch Dermatol*. 2010;146(9):1021–5.
18. Hernández-Gil J, Fernández-Pugnaire MA, Serrano-Falcón C, Serrano-Ortega S. Clínica y dermoscopia de la enfermedad de Bowen pigmentada. *Actas Dermosifiliogr*. 2008;99(5):419–20.

Author biography

Rutu Harsh Oza, Consultant Dermatologist  <https://orcid.org/0000-0002-4213-3202>

Shreya Agrwal, Consultant Dermatologist

Jaydipkumar Tank, Associate Professor

Amita Sutaria, Professor

Kirti S Parmar, Professor

Bela J Shah, Professor and Head

Navin R Chaudhary, Consultant Dermatologist

Kriteeka Saini, Consultant Dermatologist

Harshita Vyas, Senior Resident

Shikha R Shah, Senior Resident

Deval Mistry, Consultant Dermatologist

Cite this article: Oza RH, Agrwal S, Tank J, Sutaria A, Parmar KS, Shah BJ, Chaudhary NR, Saini K, Vyas H, Shah SR, Mistry D. Role of dermoscopy in hyperpigmented skin disorders: A tertiary care centre experience. *IP Indian J Clin Exp Dermatol* 2023;9(4):184–193.