

Content available at: <https://www.ipinnovative.com/open-access-journals>

IP Indian Journal of Clinical and Experimental Dermatology

Journal homepage: www.ijced.org/

Original Research Article

A clinico-epidemiological study of breast eczema sparing nipple and areola from a tertiary care hospital in western Rajasthan

Manjulata Verma¹, Swagat Waghmare², Dilip Kachhawa¹, Praneet Awake^{3*},
Deepak Sharma¹

¹Dept. of Dermatology, Dr. S. N. Medical College, Jodhpur, Rajasthan, India

²Dept. of Dermatology, Venereology and Leprosy, D Y Patil Medical College, Navi Mumbai, Maharashtra, India

³Dept. of Dermatology, Venereology and Leprosy, Symbiosis Medical College for Women & Symbiosis University Hospital and Research Centre, Symbiosis International (Deemed University), Pune, Maharashtra, India



ARTICLE INFO

Article history:

Received 17-11-2023

Accepted 05-12-2023

Available online 05-01-2023

Keywords:

contact dermatitis
patch test
anxiety severity score
cell phone
breast eczema

ABSTRACT

Background: Nipple eczema can be a local manifestation of atopic dermatitis/eczema when it arises with classic age-related patterns of eczema on other body sites, or it can occur in isolation. In our study, breast eczema sparing nipple and areola, was observed in females of western Rajasthan.

Aims: This study reports the demography, clinico-morphological patterns and factors causing it.

Materials and Methods: After due informed consent, thirty consecutive female patients of breast eczema were undergone a detailed history, clinical examination and patch testing. Hamilton Anxiety Rating Scale was used for anxiety severity assessment.

Results: Most common site of breast eczema was the upper-outer quadrant (15/30) followed by upper-inner quadrant (9/30). The cell-phone was the most common object which was kept in close contact with the breast followed by purse (26/30) and money (11/30). Total 20 positive patch tests were seen in 17 patients. Fifteen patch tests were relevant to the current dermatitis. Mild anxiety cases were significantly more in acute type whereas moderate-severe type was more with chronic type (p value=0.021).

Limitations: Larger study is required to establish the exact cause of this type of breast eczema.

Conclusion: Breast eczema seems to have diverse etiology, supplemented by various factors such as anxiety, perspiration in hot arid weather, traditional loosely-fit inner clothing of women in this region of western Rajasthan and friction produced by the objects (cell phones) that are kept in contact with breasts, work together to produce dermatitis.

This is an Open Access (OA) journal, and articles are distributed under the terms of the [Creative Commons Attribution-NonCommercial-ShareAlike 4.0 License](https://creativecommons.org/licenses/by-nc-sa/4.0/), which allows others to remix, tweak, and build upon the work non-commercially, as long as appropriate credit is given and the new creations are licensed under the identical terms.

For reprints contact: reprint@ipinnovative.com

1. Introduction:

Breast eczema is a dermatoses characterized by various clinical manifestations such as erythema, vesicles, erosions, scaling, crusting, fissures, and lichenification, alone or in combination. Nipple eczema usually presents de novo or as a part of breast eczema. The nipple and areola are affected by nipple eczema, a localised dermatitis that is defined by

erythema and scaling. It might hurt and itch. Nipple eczema can develop alone or in conjunction with other characteristic age-related patterns of eczema on other body sites. It is a local manifestation of atopic dermatitis/eczema. The exact incidence and etiology are unknown, although association with atopy and allergic contact dermatitis are commonly encountered.¹ The role of contact sensitization and irritation in causing breast eczema is understudied.² Anxiety and stress are common triggers that cause eczema to flare up and vice versa. The role of anxiety in increasing the severity

* Corresponding author.

E-mail address: awakepraneet@gmail.com (P. Awake).

of breast eczema has limited literature.

A new type of breast eczema sparing nipple and areola was observed in our dermatology out-patient department in the last two years which prompted us for this study. The present study aims to evaluate the demography, clinico-morphological pattern of breast eczema and its relationship with anxiety, friction and contact sensitivity to common allergens in western Rajasthan.

2. Materials and Methods

This hospital-based, observational study was conducted at a tertiary level referral teaching centre in western Rajasthan over a period of six months. Thirty consecutive female patients of eczema on breast, who reported to the Department of Dermatology, were included in this study. Patients with known etiologies such as psoriasis, lichen planus, scabies, seborrheic dermatitis, urticaria, cellulitis and dermatophytoses were excluded clinically. Also, patients with breast malignancy and abscess, pregnant and lactating females were not included in this study.

Ethical permission was duly obtained from the institutional ethics and research board, Dr. S. N. Medical College, Jodhpur (Approval number No: F.1/Acad/MC/JU/15/16566 Dated:22/9/15). After informed consent from the patient, a detailed history was recorded including demographic profile, history of present ailment, occupation history, the habit of wearing inner clothing (brassieres) history, history of keeping anything in contact with breasts or any application on the breasts, history of any discharge from the nipples, aggravating or relieving factors, and the personal and family history of atopy. The morphological classification was done into three categories (acute, subacute and chronic).

Further objective assessment of the severity of anxiety was done using the Hamilton Anxiety Rating Scale (HAM-A). All patients were patch tested using the Indian standard series of 20 allergens approved by the 'Contact and Occupational Dermatitis Forum of India (CODFI)'. We also used mild scrapings from the back of cell phones and pieces of patient's purse in patch test utilising dimethylglyoxime stick test. Patients with acute eczema on the breast were patch tested after subsiding the acute phase. Aluminium chambers were used for patch testing which was done on the upper back of patients. Readings were taken after 48 and 72 hours and interpreted according to the International Contact Dermatitis Research Group criteria.²

Statistical analysis was performed with the SPSS, version 23 for Windows. The Categorical data were presented as numbers and percentages and were compared among groups using Chi-square test. Probability P-value <0.05 was considered statistically significant.

3. Results

Total of 30 patients with breast eczema sparing nipple and areola were enrolled in this study. Out of them, 25 patients (76.67%) were in the age group of 21-60 years followed by 5 patients in more than 60 years of age group. Out of 30, 26(86.66%) females were house-wife whereas 4 were labourer.

According to duration, acute eczema (1-6 weeks) was noticed in 14 patients, whereas 16 patients had a history of more than 6 weeks. All patients had recurrence history. According to morphological classification, acute eczema was seen in 8 patients, subacute in 6 patients and chronic eczema in 16 patients. Histopathological examination of acute cases showed intraepidermal vesiculation with spongiosis, scale crust and parakeratosis. Variable superficial perivascular lymphocytic infiltrate with/without eosinophils seen in the dermis. Whereas subacute-chronic eczematous cases showed parakeratosis and scale crust with overlying acanthotic epidermis.

The most common site of eczema was upper-outer quadrant (15/30) sparing nipple [Figure 1] and eczema followed by upper-inner quadrant in 9 patients. [Figure 2] The lower half was involved in 6 patients. The involvement was predominantly bilateral, seen in 18 patients; which was symmetrical as well as asymmetrical. Unilateral involvement was observed in 12 patients with left-side predominance (9/12). (Table 1)

The cell phone was the most common object which was kept in close contact with the breast followed by purse (26/30), money (11/30) and betel nut pouch (6/30). (Table 2) The history of brassiere wearing was seen in only 5 patients; rest were with their traditional loosely fitted inner-wear. No-one gave a history of nickel or cobalt allergy. Personal and family history of atopy was also negative in all patients.

Total of 20 positive patch tests were seen in 17 (56.67%) patients with relevant patch tests in 14 (82.35%) and non-relevant patch tests in 3 (17.65%) patients. The maximum positivity of the patch test was for formaldehyde (10%) followed by thiuram mix, potassium dichromate, nickel, epoxy resin and neomycin in 2 patients each (6.66%). Mercaptobenzothiazole, cobalt, colophony, Paraphenylene diamine(PPD), black rubber mix, partheniumand fragrance mix positivity were seen in one patient each (3.33%) (Table 3).

According to the Hamilton Anxiety Rating Scale, 17 patients had mild anxiety, 3 patients had mild to moderate anxiety and 9 patients had moderate to severe anxiety. On cross-evaluating anxiety with morphology, acute eczema was significantly more associated with mild anxiety as compared to mild to moderate whereas moderate to severe type of anxiety was more associated with a chronic type of eczema (p value=0.021). On comparing anxiety severity with duration, moderate to severe type of anxiety was more common in patients with longer duration of eczema (22.89

weeks \pm 12.49) (p-value <0.001).

Table 1: Site of breast eczema

Site of breast eczema	No. of patients	Percentage
Upper-outer quadrant	15	50%
Upper-inner quadrant	9	30%
Lower-outer quadrant	4	13.33%
Lower-inner quadrant	2	6.67%

Table 2: List of objects kept in contact with breast

Object keeping in contact with breast	No. of patients	Percentage
Cell phone	30	100%
Purse	26	86.67%
Money (currency note & coins)	11	36.67%
Betel nut pouch	6	20%
Paper	2	6.67%
Edible thing pouch	1	3.33%

Table 3: Positive patch test of breast eczema cases

Name of allergen	Positive patch test	Percentage (%)
Formaldehyde	3	10
Thiuram mix	2	6.66
Nickel	2	6.66
Potassium dichromate	2	6.66
Epoxy resin	2	6.66
Neomycin	2	6.66
Mercaptobenzothiazole	1	3.33
Cobalt	1	3.33
Black rubber mix	1	3.33
Colophony	1	3.33
Paras-phenylenediamine	1	3.33
Parthenium	1	3.33
Fragrance mix	1	3.33

4. Discussion

Breast eczema may affect the nipple, areola, or surrounding skin, with various clinical presentations such as erythema, vesicles, erosions, scaling, crusting, fissures, and lichenification, alone or in combination. Eczema of the nipple and areola occurs mainly in women which may be unilateral or bilateral.^{3,4} The exact etiology, pathogenesis and incidence are not known. We recently encountered patients with breast eczema in the dermatology out-patient department, without the involvement of nipple and areola. This study was conducted to assess the prevalence and pattern of this breast eczema. To the best of our knowledge, this is the first study to record the breast eczema excluding the nipple and areola, in western Rajasthan. In our study,

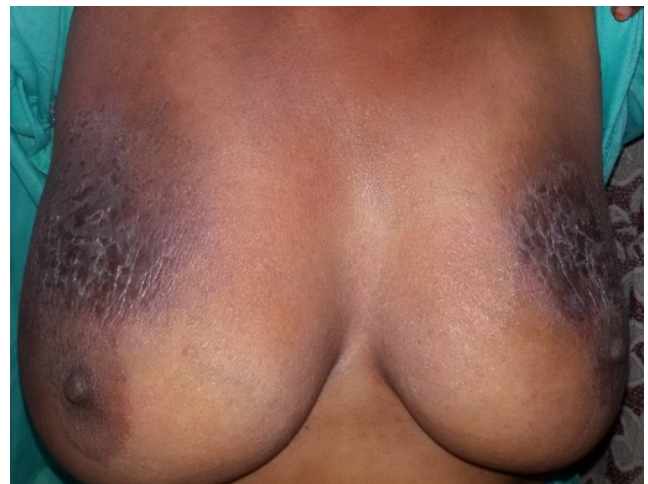


Figure 1: Lichenified plaque with erosions and post inflammatory hyperpigmentation involving upper inner and outer quadrant of both breasts with sparing of nipple and areola

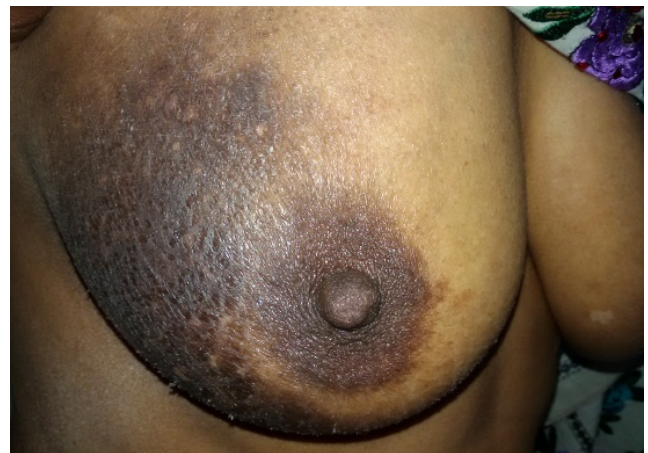

Figure 2: Ill-defined eczematous plaque involving upper-outer quadrant on right breast with sparing of nipple and areola

the majority of patients were between 21-60 years engaged mainly in household and labour work belonging to the upper lower socioeconomic class. A preponderance of breast eczema in this age group may be due to their more active lifestyles resulting in frequent exposure of breast to various objects (allergens/irritants) due to their habit of keeping objects in inner clothing in close contact with the breast. The upper-outer quadrant (50%) of the breast was the most commonly affected area in our study proving the usual site of keeping objects. 60% of patients had involvement on both breasts with more extensive involvement on one side. Cases with unilateral involvement showed left side predominant involvement, proving right-handedness of the patient. Irritation from friction must also be kept in mind. According to Kapur et al, unilateral nipple dermatitis in women with large asymmetrical breasts was attributed due

to friction between the larger breast and the seam of the brassière cup.⁵ In our study, the majority of women did not have a habit of wearing brassieres, instead of this they had a custom of wearing traditional loosely fit inner clothing as a part of blouse that predisposes to frequent friction. Although there is an association of nipple/areola eczema with atopy and it may occur during breastfeeding.^{6–8} But in our study, personal and family history of atopy was absent in all patients. History of nipple/areola eczema during the lactation period was also absent in all patients. Allergic contact dermatitis of nipples has been reported in a breastfeeding woman using a beeswax nipple protector, and applying Roman chamomile ointments.^{9,10} In our study, there was no history of such type of application. Whereas we found a history of keeping some objects in close contact with the breasts. The most common objects were cell phones and small purses followed by currency notes/coins, beetle nut pouch, paper, biscuit pouch, etc. The patch testing showed different types of positivity in all cases that indicate one particular type of the allergen is not responsible for breast eczema. Total of 20 positive patch tests were seen in 17 (56.67%) patients. After patch testing, patients were interviewed for the relevance of the patch test results. Thus the overall relevance was seen in 82.35% (14/17) patients for different types of allergens. Out of 20 positive patch tests, only 15 (75%) were relevant to current dermatitis, 2 were relevant to past dermatitis and 3 were non-relevant. The maximum positivity of the patch test was for formaldehyde (10%) which is used for tanning white leather, textile finishing and surface coating. Formaldehyde resin is also a common allergen present in currency notes and in rubber. Purses used by these females were commonly made up of rubber, leather and different type of clothing material. Thiuram mix, black rubber mix and mercaptobenzothiazole were present in rubber products and its derivatives. Potassium dichromate penetrates the skin readily due to its water solubility. However, the commonest cause of allergic contact dermatitis from chromate is cement but in our patient's sources are leather apparel (purse) and electroplating fluids (cell phone). Nickel is used in the making of alloys and its salts are used in electroplating fluids. Epoxy resins are used as plasticizers, polymer stabilizers and as a surface coating agent. The source of colophony may be a glossy paper which was kept in contact with the breast by few patients and patch test positivity to it was approximately 3.33%. Paraphenylenediamine is used in leather processing and rubber vulcanizing process, for which patch test was positive in 3.33%. These allergens by itself were not able to cross the skin barrier but prolonged contact of the breast with the cell phone, purse and other objects create a hot and humid environment which increases perspiration causing sensitization to these objects which may lead to allergic contact dermatitis. Among 30 patients, only 14(46.67%) showed relevant patch test positivity to

current dermatitis. In the remaining 16(53.33%) patients 13 with negative patch test and 3 with non-relevant patch test to current dermatitis], we presume that, objects that kept in contact with the breast act as a physical irritant leading to a physical irritant contact dermatitis(PICD). PICD is a less researched form of irritant contact dermatitis due to its various mechanisms of action and a lack of a test for its diagnosis.^{11,12} On correlating the morphology of eczema with anxiety levels, we found that mild anxiety was significantly more common in the acute type of eczema whereas moderate to severe type of anxiety was more associated with the chronic type (p-value=0.021). No significant difference was observed with other variables like distribution on the breast (side and site of eczematous lesion) and results of the patch test; although the maximum cases with positive patch test was observed in moderate to severe anxiety cases. The mean age was not significantly associated with the level of anxiety. Anxiety grade increases significantly with the duration of exposure. Higher duration (22.89 weeks \pm 12.49) was significantly more with the moderate to severe type of anxiety (p value<0.001). A complete patient history combined with negative allergic patch testing is usually necessary to reach a correct diagnosis of PICD.^{11,12} The simplest form of PICD results from prolonged rubbing, although the diversity of implicated irritants is far wider.^{13–15} In this part of north western India, the usual practice by females is keeping small objects (cell phones, small purses etc.) in close contact with the breast under the inner clothing (usually made up of polyester material). This habit provokes eczema and anxiety is responsible for its persistence. Eczema was managed with topical corticosteroid and emollient. Patients were explained about the probable cause and counselled to avoid their habit of keeping any objects in contact with the breast. Anxiolytics were also given to patients with higher anxiety scores. The majority of the patient significantly improved within a few weeks. We recommend patch testing to rule out the possibility of allergic contact dermatitis whenever suspected. The larger study is required to establish the exact cause of this type of breast eczema.

5. Limitations

We recommend patch testing to rule out the possibility of allergic contact dermatitis whenever suspected. The larger study is required to establish the exact cause of this type of breast eczema.

6. Conclusion

Breast eczema which spares nipple and eczema was recently reported in western Rajasthan. It is speculated that this variant of breast eczema is induced by persistent friction between breast, loosely fit polyester inner-wear and objects which females commonly keep in close contact

with the breast. The hot and humid environment of western Rajasthan aggravates the condition. Patch testing for common metal allergens and spot testing of the patient's phone may be helpful in establishing a diagnosis.

7. Source of Funding

None.

8. Conflict of Interest

None.

References

1. Kim SK, Won YH, Kim SJ. Nipple eczema: a diagnostic challenge of allergic contact dermatitis. *Ann Dermatol*. 2014;26(3):413–4.
2. Wilkinson DS, Fregert S, Magnusson B, Bandmann HJ, Calnan CD, Cronin E, et al. Terminology of contact dermatitis. *Acta Derm Venereol*. 1970;50(4):287–92.
3. Graham DF. Eczema of the nipple. *Hosp Dermatol Soc*. 1972;58:98–107.
4. Topham EJ, Mortimer PS. Nipple eczema: A systematic review and practical recommendations. *Br J Dermatol*. 2002;147:27.
5. Kapur N, Goldsmith PC. Nipple dermatitis – not all what it 'seams'. *Contact Dermatitis*. 2001;45(1):44–5.
6. Mevorah B, Frenk E, Wietlisbach V, Carrel CF. Minor clinical features of atopic dermatitis. Evaluation of their diagnostic significance. *Dermatologica*. 1988;177(6):360–4. doi:10.1159/000248607.
7. Amato L, Berti S, Chiarini C, Fabbri P. Atopic dermatitis exclusively localized on nipples and areolas. *Pediatr Dermatol*. 2005;22:64–70.
8. Barankin B, Gross MS. Nipple and areolar eczema in the breastfeeding woman. *J Cutan Med Surg*. 2004;8(2):126–30.
9. García M, Delpozo MD, Díez J, Muñoz D, de Corrés L. Allergic contact dermatitis from a beeswax nipple-protective. *Contact Dermatitis*. 1995;33(6):440–1.
10. McGeorge BC, Steele MC. Allergic contact dermatitis of the nipple from Roman chamomile ointment. *Contact Dermatitis*. 1991;24(2):139–40.
11. Morris-Jones R, Robertson SJ, Ross JS, White IR, McFadden JP, Rycroft RJG, et al. Dermatitis caused by physical irritants. *Br J Dermatol*. 2002;147(2):270–5.
12. Reynaert V, Gutermuth J, Wollenberg A. Nipple eczema: A systematic review and practical recommendation. *J Eur Acad Dermatol Venereol*. 2023;37(6):1149–59.
13. Wu C, Jia QN, Fang K, Zeng YP. Skin diseases of the nipple and areola complex: A case series study from China. *Front Med*. 2023;10:1136482. doi:10.3389/fmed.2023.1136482.
14. Waldman R, Finch J, Grant-Kels J, Stevenson C, Whitaker-Worth D. Skin diseases of the breast and nipple: Benign and malignant tumors. *J Am Acad Dermatol*. 2019;80(6):1467–81.
15. Costa DD, Taddese A, MLCure, Gerson D, Jr RP, Esserman LE, et al. Common and unusual diseases of the nipple-areolar complex. *Radiographics*. 2007;27(Suppl 1):S65–77.

Author biography

Manjulata Verma, Assistant Professor

Swagat Waghmare, Assistant Professor

Dilip Kachhawa, Professor

Praneet Awake, Assistant Professor

Deepak Sharma, Senior Resident

Cite this article: Verma M, Waghmare S, Kachhawa D, Awake P, Sharma D. A clinico-epidemiological study of breast eczema sparing nipple and areola from a tertiary care hospital in western Rajasthan. *IP Indian J Clin Exp Dermatol* 2023;9(4):194-198.