



## Original Research Article

## Correlation of photopatch positivity with clinical profile in patients with photoallergic dermatitis

V A Kayalvizhi<sup>1</sup>, P Sivayadevi<sup>1</sup>, P Kalyanakumar<sup>1</sup>, R Vidhya Sivasankari<sup>1</sup>, P Nirmaladevi<sup>1\*</sup><sup>1</sup>Dept. of DVL, Tirunelveli Medical College, Tirunelveli, Tamil Nadu, India

## ARTICLE INFO

## Article history:

Received 11-12-2023

Accepted 22-12-2023

Available online 05-01-2023

## Keywords:

Photoallergic contact

Dermatitis

Photopatch test

Parthenium

## ABSTRACT

**Introduction:** Photopatch test (PPT) is designed to diagnose Photoallergic Contact Dermatitis (PACD) using specific dose and wavelength of irradiation. This study is a retrospective analysis of patients with photosensitivity who have undergone photopatch testing.

**Aim and Objective:** To find the Correlation of photo patch positivity with clinical profile in patients with photoallergic dermatitis.

**Results and Discussion:** Photo patch testing helps in determining the sensitizing potentials of commonly used day to day agents containing the allergen. Thirty-seven patients who had patch tested between July 2022 and June 2023 were analyzed. The patch test antigens comprising 20 common photoallergens from Indian Standard Series were photopatch tested. Of all the patients tested the overall positivity rate was (67.56%). All patients had a characteristic clinical picture of photodermatitis for an variable duration. All patients were engaged in various occupations that involved working outdoors. The exacerbating factors were summer season in 15 (40.54%) patients, insecticides spraying in three (8.1%) and exposure to plant in ten (27%). History of contact with cement was present in six (16.21%) patients. The patients who showed positivity after irradiation was 5 (13.51 %), before and after irradiation was 7 (18.91%), and exacerbated grading after irradiation was 13 (35.13%). The common allergen showing positivity were parthenium (29.72%), potassium dichromate (13.51%), PPD (10.81%). Apart from these allergens' fragrance mix, paraben, neomycin sensitivity was also noted in few patients.

**Conclusion:** Significant number of cases belongs to photodermatitis, thereby, finding the cause and the measures to alleviate the symptoms are paramount important. For proper diagnosis, photopatch test is essential and our study emphasis the same which can aid in appropriate management. Cosmetics, sunscreens and drugs like NSAID are found to be the emerging cause for PACD and photopatch series with relevance to above allergen is the need of the hour.

This is an Open Access (OA) journal, and articles are distributed under the terms of the [Creative Commons Attribution-NonCommercial-ShareAlike 4.0 License](https://creativecommons.org/licenses/by-nc-sa/4.0/), which allows others to remix, tweak, and build upon the work non-commercially, as long as appropriate credit is given and the new creations are licensed under the identical terms.

For reprints contact: [reprint@ipinnovative.com](mailto:reprint@ipinnovative.com)

## 1. Introduction

Photoallergic contact dermatitis (PACD), a delayed-type hypersensitivity reaction is brought on by the application of an external substance (photoallergen) to the skin and exposure to ultraviolet (UV) and/or visible radiation subsequently. The UV light may be natural in the form

of sun or artificial. Wavelengths in the UVA band generally elicit a photoallergic contact reaction, because UVA radiation penetrates deeper into the layers of skin where the photoallergen is concentrated. Photopatch test (PPT) is designed to diagnose PACD using specific dose and wavelength of irradiation.<sup>1</sup> Photopatch testing is an effective approach for the diagnosis of suspected photodermatoses. Determining the sensitizing potentials of

\* Corresponding author.

E-mail address: [nirmaladevipalanivel@gmail.com](mailto:nirmaladevipalanivel@gmail.com) (P. Nirmaladevi).

commonly used agents is another benefit of photopatch test. In general, with standard or special photopatch series positive photopatch results are obtained in 4–20% of suspected photodermatoses cases, thereby aiding in the diagnosis of photoallergic contact dermatitis.<sup>1,2</sup>

## 2. Materials and Methods

This study is a retrospective analysis of patients with photodermatitis who have undergone photopatch testing. After getting approval from Institutional Ethics committee, data of patients who had been diagnosed clinically as a case of photodermatoses and then Photopatch tested between July 2022 and June 2023 were analyzed (n=37). All the demographic, clinical and aggravating factors along with photopatch test results were analyzed.

Indian Standard Series patch test (containing 20 allergens) was employed using the Finn Chamber method. The patch test had been applied in two sets and were kept covered with a radio-opaque sheet. After 48 h, the reading of both sets was taken and one set was again covered with a radio-opaque sheet and the other set exposed to 15 J/cm<sup>2</sup> of UVA (Philips TL/10R tubes). Then the irradiated site was covered again. After another 48 hours, reading from both irradiated and non-irradiated sites were observed and interpreted according to the ICDRG criteria.<sup>3</sup> The interpretation was as follows: If the irradiated site showed a positive reaction and the non-irradiated site showed a negative one, a diagnosis of photoallergy was made out. If the scoring was significantly stronger on the irradiated site than the other, then a diagnosis of photo aggravated PACD was made. If both sites show equally positive reactions, then a diagnosis of contact allergy was made. (Table 1)

## 3. Results

Of the thirty-seven patients, 27 patients were males and 10 patients were females and the age of the patients ranged from 20 to 75 years with maximum numbers of patients (n=15; 40.5%) in the range of 51-60 years (Figure 1). Out of the 37 patients. The duration of complaints was less than 5 years in Twenty-three (62.2%) patients and more than 5 years in remaining fourteen patients (37.8%) patients. While most of the patients had lesions over the photo exposed areas, only five (13.5%) patients presented with lesions all over the body.

All patients had history of exposure to sunlight before onset of symptoms. The duration between exposure to sun light and development of symptoms was between few minutes to four hours. The occupation of the patients were farmers (24.32%), daily wages working outdoors (21.62%), Masons (16.21%), housewives (16.21%) mostly and few others like wood worker, Teacher, painter, sanitary worker and Electrician (Figure 4). The most common exacerbating factors were hot weather which was seen in approximately

15 patients (40.54%) followed by contact with plants in ten (27%). History of contact with cement was present in six (16.21%) patients. Symptoms of aggravation following hair dye usage was seen in two (5.4%).

Of all the patients, 25 patients tested positive for photo patch test and the overall positivity rate was 67.56% (Figure 2). The patients who showed photo contact allergy was 5 (13.51%), contact allergy was 7 (18.91%), and photo aggravated contact allergy was 13 (35.13%). In our study no patients showed irritation after irradiation. The common allergens showing positivity were parthenium (29.72%), potassium dichromate (13.51%), Para-Phenylene-Diamine (10.81%), fragrance mix (5.40%), Neomycin (2.70%), colophony (2.70%), paraben mix (2.70%) (Figure 3). The comparison of occupation with photopatch test is given in the Figure 5, of which farmers had showed highest positivity. The clinical picture and photopatch tests are shown in Figures 6 and 7.

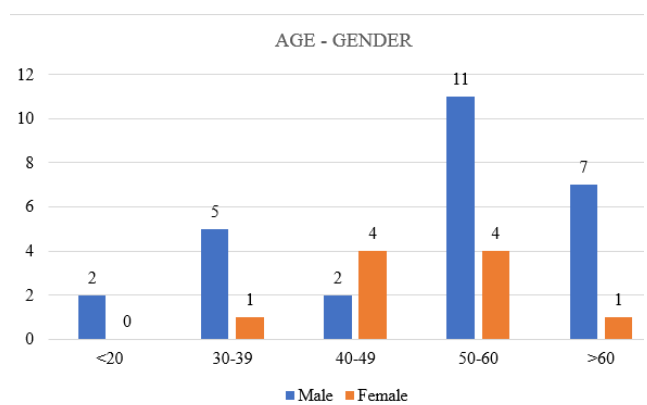


Figure 1: Clinicodemographic profile of patients

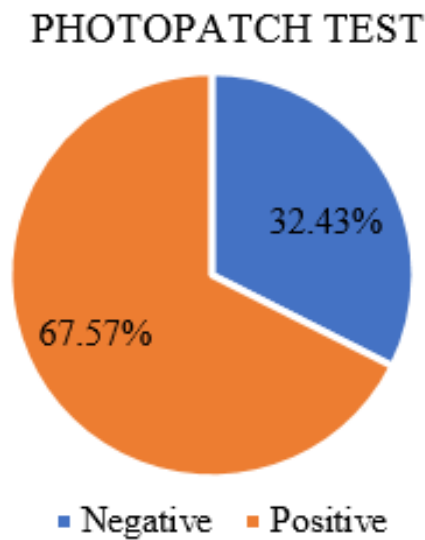
## 4. Discussion

Photoallergic contact dermatitis is brought on by exposure to UV light following contact with a photoallergen or absorption of a photosensitizer agent.<sup>3,4</sup> Photodermatitis may be induced by UV light (mainly UVA) or Visible light<sup>4</sup> and eczematous eruption to both UVB and UVA is termed Photosensitivity Dermatitis.<sup>5</sup>

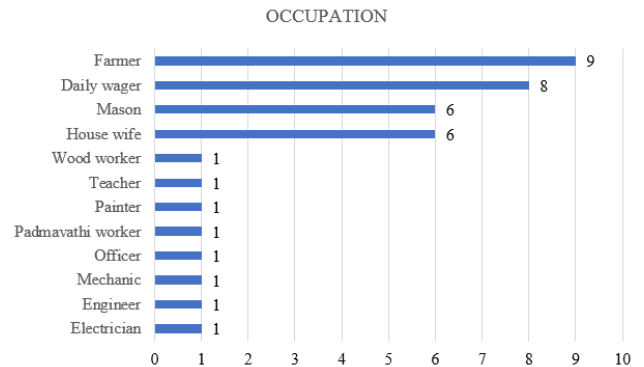
Photoallergic contact dermatitis is a common occupational skin disease and the risk factors include working outside and contact with certain plants or substances used in daily works or with cosmetic products. The main cause of photodermatitis in India resulting in photoallergy, contact dermatitis, and photoaggravation is parthenium.<sup>6</sup> It is characterised by a varied morphological pattern like eczematous or noneczematous lesions over sun-exposed sites mostly. Organic UV sunscreens, topical nonsteroidal anti-inflammatory drugs, cosmetics and fragrances are the other commonest agents causing PACD.<sup>7</sup>

**Table 1:** Interpretation of photopatch test at 48 hours:

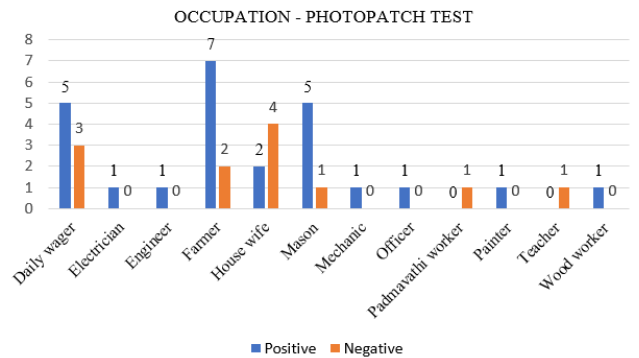
Reading at irradiated site	Reading at non-irradiated site	Interpretation	% of people showing positivity (n=25)	Morphological pattern encountered
0	0	No allergy		1. Airborne contact dermatitis like pattern
++	0	Photoallergy	13.51(n=5)	2. PMLE like exposed site involvement pattern
+	+	Contact allergy	18.91(n=7)	3. Lichenoid pattern
++	+	Contact dermatitis with photoaggravation	35.13(n=13)	4. Hand eczema like pattern



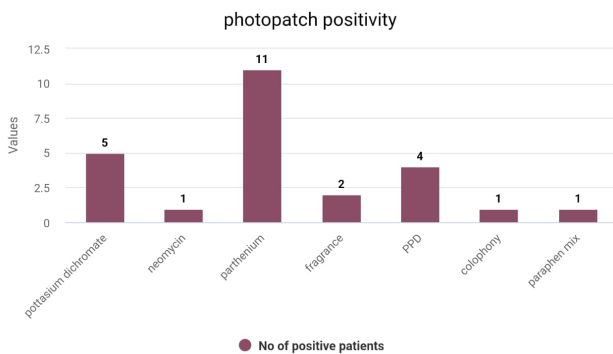
**Figure 2:** Total patients showing positivity



**Figure 4:** Common occupations encountered

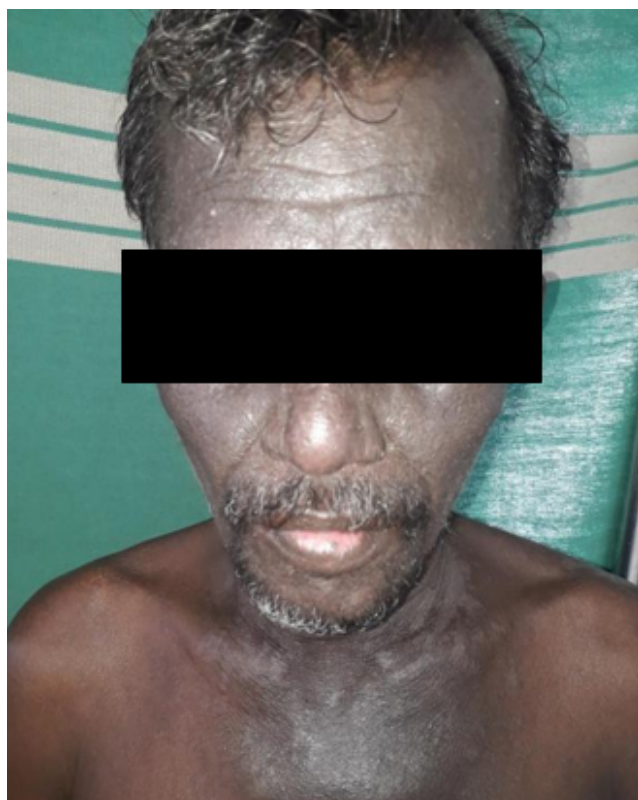

**Figure 5:** Occupation based photopatch positivity

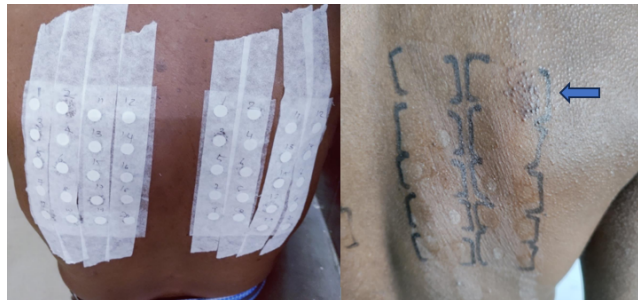

**Figure 3:** Common allergens showing positivity in our study

Patch testing combined with UV light exposure to create the photoallergen is known as photopatch testing (PPT). With the exception of the requirement for an adequate light source and opaque shielding, the application of allergens and scoring criteria are the same as those for general patch testing. The best diagnostic method currently available for PACD is photopatch testing.<sup>8</sup> At present the various photopatch series available are,<sup>8,9</sup> German, Austrian, and Swiss Photopatch Test series; The Scandinavian photopatch test series; European photopatch test series and North American standard photopatch test series. In our study we used the Indian Standard Series (ISS) for our photopatch tests.



**Figure 6:** lichenified plaques over photo exposed area



**Figure 7:** Photo patch test showing positivity for parthenium after irradiation.

In India, photopatch studies have employed either European or Scandinavian photopatch series. Given the high expense of these series and the differences in allergens that cause photodermatitis due to the environmental and occupational factors in India, this may not be appropriate for Indian patients. Additionally, there is no known Indian standard photopatch test series.<sup>4</sup> Some studies have used customized photoallergen based on their patient factors. In our department, the regular Indian standard patch test series was used for the photopatch test. This study is conducted retrospectively to analyze the utility of regular patch test series in diagnosing photo allergic contact dermatoses.

Our patients' clinicodemographic characteristics matched those previously documented in the literature. The various morphological patterns of PACD observed in our study were: ABCD pattern observed in most of patients (due to parthenium), followed by PMLE like exposed site involvement pattern, Lichenoid pattern and Hand eczema like pattern.

The photopatch test's overall positivity was 67%. Parthenium hysterophorus was the most common allergen in Rai et al.'s study, with 51% of participants exhibiting a positive response.<sup>4</sup> Parthenium produced photocontact allergy in four and photoaggravation in six of their patients and studies done by Sharma et al also showed parthenium to be the most common photo allergen.<sup>10,11</sup> Parthenium is the most frequent cause of photoallergic dermatitis in our study too with 30% of the patients testing positive for it. Additionally, the majority of these patients showed photo aggravated picture. Whereas studies done by Jindal et al<sup>2</sup> showed fragrance mix as the most common allergen followed by para phenylene diamine (PPD) and parthenium showed positivity in 17% of their patients. Potassium dichromate was the second common allergens in our study (14%) and were seen mostly in Masons. Other than cement, Leather industries, bleaching agents, detergents, match box heads also contain chromium. Similar to Masons, workers pertaining to these industries have similar risk. The third allergen which showed positivity was PPD with Six patients (20%) eliciting photocontact allergy. Photo patch test series was customized as per their patient need in the studies compared above.

Apart from these allergens fragrance mix, paraben, and neomycin were also noted in few patients. A Study conducted by Panja et al. showed fragrance mix with highest positivity but this was not observed in our study.<sup>12</sup> Allergens of importance in western studies are sunscreens and drugs like NSAID, chlorpromazine, promethazine and ketoprofen. In study conducted by Ghuse et al., photopatch test was found to be positive in 10-20% of facial melanosis.<sup>13</sup>

In brief, the overall positivity of photopatch is 67% which makes the ISS patch test series a reliable source for the diagnosis of photodermatoses in resource poor settings. Addition to ISS of specific agents proclaimed to cause photosensitivity can increase the accuracy of this tests, as the patients with negative photopatch test did have some form of contact with topical agents.

## 5. Conclusion

Now a days, significant number of patients belong to photodermatoses. Finding the cause and the measures to alleviate the symptoms and concerns of the patients are of paramount importance. For specific diagnosis, photopatch test series is essential and our study emphasize the same. The current Indian standard series seems good for photopatch test as  $2/3^{rd}$  of our patients tested positive

for photodermatoses. Moreover, further study regarding insecticides, air and water pollutants from industry is also essential. Cosmetics, sunscreens and drugs like NSAIDs are found to be the common cause for PACD. Photopatch series with relevance to above allergens and customized to the Indian environment is the need of the hour.

## 6. Limitation

1. Limited number of allergens were only photo patch tested.
2. Our study population is small.

## 7. Conflict of Interest

None.

## 8. Source of Funding

None.

## References

1. European Multicentre Photopatch Test Study (EMCPPTS) Taskforce. A European multicentre photopatch test study. *Br J Dermatol.* 2012;166(5):1002–9.
2. Jindal N, Sharma NL, Mahajan VK, Shanker V, Tegta GR, Verma GK, et al. Evaluation of photopatch test allergens for Indian patients of photodermatitis: Preliminary results. *Indian J Dermatol Venereol Leprol.* 2011;77:148–55. doi:10.4103/0378-6323.77453.
3. Johansen JD, Aalto-Korte K, Agner T, Andersen KE, Bircher A, Bruze M, et al. European Society of Contact Dermatitis guideline for diagnostic patch testing - recommendations on best practice. *Contact Dermatitis.* 2015;73(4):195–221.
4. Horio T. Photoallergic reaction. Classification and pathogenesis. *Int J Dermatol.* 1984;23(6):376–82.
5. Rai R, Thomas M. Photopatch and UV-irradiated patch testing in photosensitive dermatitis. *Indian Dermatol Online J.* 2016;7(1):12–6.
6. Lehmann P, Schwarz T. Photodermatoses: diagnosis and treatment. *Dtsch Arztebl Int.* 2011;108(9):135–41.
7. Verma KK, Sirka CS, Ramam M, Sharma VK. Parthenium dermatitis presenting as photosensitive lichenoid eruption. A new clinical variant. *Contact Dermatitis.* 2002;46(5):286–9.
8. Kerr AC, Ferguson J, Haylett AK, Rhodes LE, Adamski H, Alomar A, et al. A European multicentre photopatch test study: The European Multicentre Photopatch Test Study (EMCPPTS) taskforce. *Br J Dermatol.* 2012;166(5):1002–9.
9. Codeço C, Alves PB, Figueiredo AC, Flor D, Gonçalo M. Shedding a light on the importance of photopatch testing: A 12-year experience in a dermatology unit. *Contact Dermatitis.* 2023;88(6):438–45.
10. Kanchan PA, Shenoi SD, Balacharan C. Five Year Experience in photopatch test in 50 patients. *Indian J Dermatol Venereol Leprol.* 2002;68(2):86–7.
11. Sharma VK, Bhari N, Wadhvani AR, Bhatia R. Photo-patch and patch tests in patients with dermatitis over the photo-exposed areas: A study of 101 cases from a tertiary care centre in India. *Australas J Dermatol.* 2016;59(1):e1–5.
12. Panja A, Srinivas CR, Shenoy SD, Balachandran C. Patch photopatch test at Manipal. *Indian J Dermatol Venereol Leprol.* 1994;60(6):337–9.
13. Ghuse VM, Someshwar S. Patch Testing as a Corroborative and Diagnostic Tool in Patients Suspected of Contact Allergen Induced Facial Melanosis. *Indian J Dermatol.* 2021;66(4):337–42.

## Author biography

**V A Kayalvizhi**, Assistant Professor

**P Sivayadevi**, Associate Professor

**P Kalyanakumar**, Senior Resident

**R Vidhya Sivasankari**, Junior Resident

**P Nirmaladevi**, Professor and HOD

**Cite this article:** Kayalvizhi VA, Sivayadevi P, Kalyanakumar P, Sivasankari RV, Nirmaladevi P. Correlation of photopatch positivity with clinical profile in patients with photoallergic dermatitis. *IP Indian J Clin Exp Dermatol* 2023;9(4):211–215.