

Content available at: <https://www.ipinnovative.com/open-access-journals>

IP Indian Journal of Clinical and Experimental Dermatology

Journal homepage: [www.ijced.org/](http://www.ijced.org/)

## Original Research Article

## Dermatoscope as a tool to determine the stability of vitiligo

Gumma Sindhuri<sup>1\*</sup>, Shefa Karim<sup>1</sup>, Pooja Patel<sup>1</sup>, Nitin Nadkarni<sup>1</sup>, Sharmila Patil<sup>1</sup>, Kiran Godse<sup>1</sup><sup>1</sup>Dept. of Dermatology, D.R. DY Patil Medical College, Navi Mumbai, Maharashtra, India

## ARTICLE INFO

## Article history:

Received 14-02-2024

Accepted 12-03-2024

Available online 01-06-2024

## Keywords:

Vitiligo

Dermatoscopy

Disease activity

Hyperpigmentation

## ABSTRACT

**Background:** Vitiligo is characterised by depigmentation of the skin that occurs without any prior inflammation. In vitiligo, dermatoscopy acts as an auxiliary technique for confirming the diagnosis and also assists in the assessment of disease activity.

**Objective:** Present study was done to characterise the deratmoscopic characteristics of vitiligo and to assess the diagnostic utility of dermatoscopy in vitiligo patients.

**Materials and Methods:** It was cross-sectional observational study conducted over a period of eighteen months from July 2021 to December 2022 in Department of Dermatology, Venereology and Leprosy of tertiary care teaching hospital in Mumbai, India. 50 adults of either sex or age more than 18 years of age attending dermatology outpatient department with a clinical diagnosis of vitiligo constituted the study population.

**Results:** Based on dermatoscopy, 36% of the lesions were unstable and rest 64% were stable. Perilesional and perifollicular hyperpigmentation was significantly associated with stability, while trichome border, satellite lesions and mikrokoebner phenomenon were found to be significantly associated with instability of vitiligo.

**Conclusion:** Dermatoscopy is an excellent method for diagnosing vitiligo and assessing disease activity. Since the stability of vitiligo necessitates surgical intervention, dermatoscopic examination may be of great assistance in determining disease activity.

This is an Open Access (OA) journal, and articles are distributed under the terms of the [Creative Commons Attribution-NonCommercial-ShareAlike 4.0 License](https://creativecommons.org/licenses/by-nc-sa/4.0/), which allows others to remix, tweak, and build upon the work non-commercially, as long as appropriate credit is given and the new creations are licensed under the identical terms.

For reprints contact: [reprint@ipinnovative.com](mailto:reprint@ipinnovative.com)

## 1. Introduction

Vitiligo is characterised by depigmentation of the skin that occurs without any prior inflammation. The related stigma and significant psychological distress have been seen in people with this pigmentary disorder, which affects around 1% of the general population.<sup>1</sup> The Vitiligo European Task Force (VETF) has provided consensus illness classifications, but a larger worldwide agreement was thought to be necessary. Recent proposals include the work of seven regional working groups: North and

South Africa, North and South/Central America, Europe, the Middle East, Continental Asia/Singapore, Japan/Taiwan, and the Pacific.<sup>2</sup>

Clinical, histopathological, and molecular techniques, each with its own limitations, have been explored to discover indicators for predicting the likely course in particular individuals. In the majority of instances, however, the assessment of the stable status of vitiligo was a requirement. Existing clinical approaches to determining the status of vitiligo include the following: first, taking a history on the onset of new lesions and on the extension of preexisting lesions from 1 to 2 years;<sup>3</sup> second, at the time of examination, on the presence of the Koebner phenomenon;

\* Corresponding author.

E-mail address: [drsindhuri95@gmail.com](mailto:drsindhuri95@gmail.com) (G. Sindhuri).

third, on a high VIDAScore (Vitiligo Disease Activity Score)<sup>4</sup>; and fourth, on the absence of repigmentation following a negative minigrafting test. However, these assessments of the activity state of vitiligo are inaccurate (patients often forget the date lesions first appeared), delayed, and time-consuming.

In vitiligo, dermoscopy acts as an auxiliary technique for confirming the diagnosis and also assists in the assessment of disease activity. Dermoscopy reveals marginal and perifollicular hyperpigmentation, reticular pigmentation, and marginal reticular pigmentation in vitiligo patients with stable disease and repigmentation.<sup>5</sup> In order to separate early emerging lesions from other hypopigmented skin illnesses, specific examinations such as histology and dermoscopy are required. As a non-invasive diagnostic tool, dermoscopy has vast uses for diagnosing vitiligo lesions and determining their activity. Therefore, the current research was done to characterise the dermoscopic characteristics of vitiligo and to assess the diagnostic utility of dermoscopy in vitiligo patients.

## 2. Materials and Methods

### 2.1. Study design, settings and participants

It was a hospital based Single centre cross-sectional observational study conducted over a period of eighteen months from July 2021 to December 2022 in Department of Dermatology, Venereology and Leprosy of tertiary care teaching hospital in Mumbai, India. All adults of either sex and age more than 18 years of age attending dermatology outpatient department with a clinical diagnosis of vitiligo constituted the study population. Patients with other causes of hypopigmentation and depigmentation were excluded from the study. A total of 50 cases, were finally included in the study.

### 2.2. Data collection

Data were collected using a pre-designed semi-structured study proforma. Demographic information like age, gender; Clinical information like past medical history, family history, risk factors for vitiligo, history of present illness, general physical examination were collected. The included patients provided a comprehensive medical history, and a clinical examination was conducted using a Wood's light. Four Wood's lamp results were used, including achromic with a well-defined border, hypopigmented with a fuzzy border, trichrome, and inflammatory. The achromic vitiligo with a clearly defined border was deemed stable, whereas the other three features were indicative of unstable vitiligo. Wood's lamp examination was regarded conventional since its results were supported by prior research. Dermoscopic evaluation was done utilizing a portable VEOS HD2 polarised and nonpolarized light dermatoscope, a dermatoscopy was conducted

(Canfield). Images were captured using the camera of an Android Smart Phone. Border, pigment network inside the patch, perilesional hyperpigmentation, perifollicular hyperpigmentation, satellite lesion, and micro-Koebner phenomenon were the dermoscopic characteristics observed.

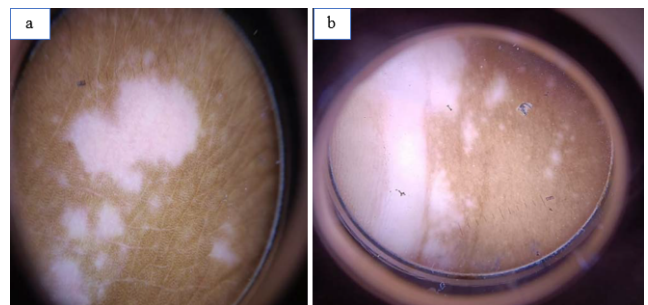
Stability of lesion was determined by the lack of advancement of previous lesions during the last two years, the absence of new lesions over the same time, the absence of a recent history of Koebner phenomenon, and the repigmentation of afflicted regions by medical therapy

### 2.3. Statistical analysis

Data were analyzed and statistically evaluated using SPSS software, version 25 (Chicago II, USA).<sup>6</sup> Quantitative data was expressed in mean, standard deviation while qualitative data were expressed in percentage. Statistical differences between the proportions were tested by chi square test or Fisher's exact test. 'p' value less than 0.05 was considered statistically significant.

### 2.4. Ethical issues

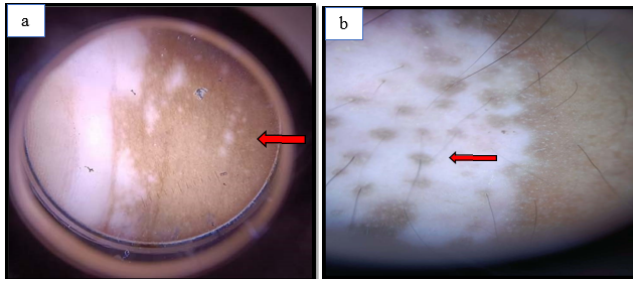
All participants were explained about the purpose of the study. Confidentiality was assured to them along with informed written consent. The study was approved by the Institutional Ethical Committee.



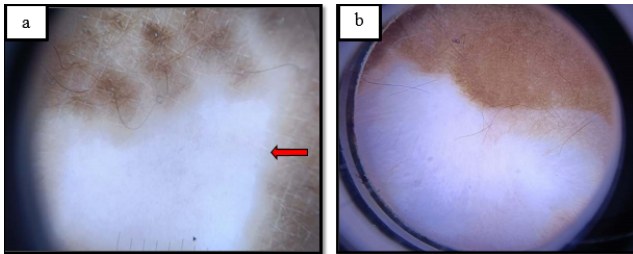
**Figure 1:** a: Presence of Satellite lesion; b: Presence of Micro-koebnerization

## 3. Observation & Results

Based on dermoscopy, we observed that 18 (36%) out of 50 of the lesions were unstable and rest 32 (64%) were stable. It was observed that 59.4% of the patients in the stable group and 55.6% of the patients in the unstable group were aged 21 to 40 years. Most common site of vitiligo was legs (n=13) followed by abdomen (n=10), chest (n=9), arms (n=9), face (n=9), hands (n=8), feet (n=8), back (n=4), palm (n=3), scalp (n=3), wrist (n=2) and breast (n=1). Other baseline characteristics of vitiligo patients are given in Table 1. We observed that 59.4% of the patients in the stable group previously took treatment, while in the unstable group



**Figure 2:** **a:** Absence of pigment network with Koebner phenomenon in a vitiligo early lesion (red arrow); **b :** Perifollicular hyperpigmentation in a case of stable repigmenting vitiligo (red arrow)



**Figure 3:** **a:** Marginal reticular hyperpigmentation in a stable vitiligo (red arrow); **b :** Absent pigmentary network

only 22.2% had previously taken treatment.

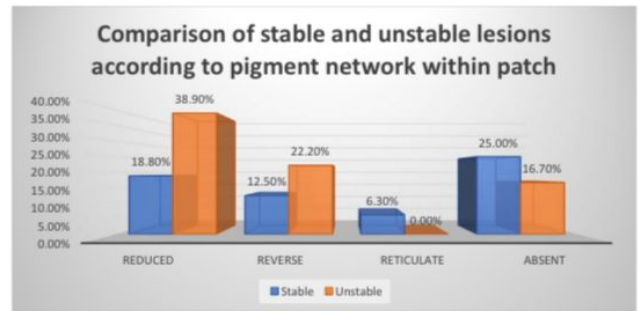
**Table 1:** Baseline characteristics of study subjects (n=50)

	No.	%
<b>Gender</b>		
Male	16	32.0
Female	34	68.0
<b>Duration of vitiligo</b>		
<5 years	30	60.0
5-10 years	20	40.0
<b>Past medical history</b>		
Thyroid disorders	17	34.0
Hypertension	13	26.0
DM	12	24.0
None	18	36.0
<b>Family history</b>		
No	30	60.0
Yes	20	40.0

The most common type of vitiligo was vulgaris in stable patients (87.5%). Rest of the stable patients had facial type (9.4%). In the unstable patients, 33.3% had vulgaris, 27.8% had acral type, 27.8% had acrofacial type and 11.1% had facial type. It was observed that acrofacial and acral types were significantly more common among unstable patients (p value <0.01). (table 2) We did not find any significant association between mucosal involvement, leukotrichia, or pigment network inside the patch and the durability of vitiligo lesions. While perilesional and perifollicular

hyperpigmentation was shown to be strongly linked with vitiligo's stable course, satellite lesions and the micro-koebner phenomenon were discovered to be considerably connected with the condition's unstable course (Table 2).

We observed that pigment network was reticular, reduced, reverse, reticulate and absent in 37.5%, 18.8%, 12.5%, 6.3% and 25% respectively in stable patients. On the other hand, pigment network was reticular, reduced, reverse, reticulate and absent in 22.2%, 38.9%, 22.2%, 0% and 16.7% respectively in unstable patients. There was no significant association between pigment patch and stability of lesions (p value = 0.31) (Figure 4).



**Figure 4:** Comparison of stable and unstable group with respect to pigment network within patch

#### 4. Discussion

In this study, we aimed to describe the various dermoscopic findings in vitiligo and to assess the diagnostic utility of dermatoscope to determine the stability of vitiligo. Using a portable VEOS HD2 polarised and non-polarized light dermatoscope, all patients had a dermoscopic examination. Border, pigment network inside the patch, perilesional hyperpigmentation, perifollicular hyperpigmentation, satellite lesion, and micro-Koebner phenomenon were the dermoscopic characteristics observed.

It was observed that 59.4% of the patients in the stable group and 55.6% of the patients in the unstable group were aged 21 to 40 years. We observed no significant difference between the patients in the stable and unstable group with respect to age group (p value = 0.51). Females comprised 78.1% of the stable group and 50% of the unstable group, with a significant difference between them (p value < 0.05). In study of Awal G et al, out of 50 vitiligo patients, 28 were female and 22 were male.<sup>7</sup> In Varma K et al study the most prevalent age range being 15 to 30 years.<sup>8</sup> Nirmal B et al. investigated the importance of dermoscopic findings in vitiligo activity in their research.<sup>9</sup> The research included a total of 85 individuals with a clinical diagnosis of vitiligo, including 45 men (52,9%) and 40 females (47.1%). They were between the ages of 16 and 64.

**Table 2:** Comparison of different finding between stable and unstable group

Type of vitiligo	Stable (n=32)	Unstable (n=18)	p value
Vulgaris	28 (87.5%)	6 (33.3%)	<0.01
Acral	1 (3.1%)	5 (27.8%)	
Facial	3 (9.4%)	2 (11.1%)	
Acrofacial	0	5 (27.8%)	0.06
Mucosal involvement	6 (18.8%)	8 (44.4%)	
Leukotrichia	16 (50%)	8 (44.4%)	0.71
Perilesional hyperpigmentation	27 (84.4%)	10 (55.6%)	0.02
Perifollicular hyperpigmentation	20 (62.5%)	3 (16.7%)	<0.01
Satellite lesions	7 (21.9%)	10 (55.6%)	0.01
Micro Koebner phenomenon	0	11 (61.1%)	<0.001

The most common type of vitiligo was vulgaris in stable patients (87.5%). Rest of the stable patients had facial type (9.4%). In the unstable patients, 33.3% had vulgaris, 27.8% had acral type, 27.8% had acrofacial type and 11.1% had facial type. It was observed that acrofacial and acral types were significantly more common among unstable patients (p value <0.01).

Within the scope of the research conducted by Awal G et al., there were a total of 25 patients diagnosed with unstable vitiligo, 13 patients receiving therapy for vitiligo, and 12 patients diagnosed with stable vitiligo.<sup>7</sup> According to the findings of the research conducted by Varma et al. (2020), out of the 50 individuals with vitiligo who participated in the study, only 17 had stable vitiligo while the remaining 33 had unstable vitiligo.<sup>8</sup> Badad AS et al. investigated a total of 120 lesions on the bodies of 50 individuals, 88 of which were clinically progressing while the other 32 were quiescent.<sup>10</sup> Vitiligo vulgaris was seen in 18 of their patients, acral type vitiligo in 13, focal variant vitiligo in 9, mixed vitiligo in 8, and segmental vitiligo in 2 of their patients.

The current research did not find any significant association between mucosal involvement, leukotrichia, or pigment network inside the patch and the durability of vitiligo lesions. While perilesional and perifollicular hyperpigmentation was shown to be strongly linked with vitiligo's stable course, satellite lesions and the micro-koebner phenomenon were discovered to be considerably connected with the condition's unstable course.

Perifollicular pigmentation (PFP), reticular hyperpigmentation (RH), marginal hyperpigmentation (MH), and an altered pigment network were some of the dermoscopic findings that were seen in all phases of the illness in the research that was conducted by Awal and colleagues.<sup>7</sup> Leukotrichia, polka spots, starburst appearance, micro-Koebner phenomenon, erythema, and telangiectasia were some of the dermatoscopic characteristics that were unique to disease activity.

In a study conducted by Varma et al.<sup>8</sup> (2020), similar dermoscopic patterns were observed. 72 These patterns included perifollicular pigmentation (22 cases),

perilesional/marginal hyperpigmentation (25 cases), intra/perilesional erythema with telangiectasia (43 cases), perifollicular depigmentation (32 cases), trichrome pattern (25 cases), leukotrichia (23 cases), starburst appearance (12 cases). In patients with clinically stable vitiligo (n = 17), perilesional/ marginal hyperpigmentation was the most prevalent significant result that was detected (p = 0.016). In another research conducted by Badad AS et al., marginal pigmentation was seen in 48% of participants, perifollicular pigmentation was observed in 32% of participants, both patterns were observed in 12% of participants, and 8% of participants exhibited none of the patterns.<sup>10</sup> According to the findings of Nirmal and colleagues, the lack of satellite lesions and the absence of the micro-Koebner phenomenon are the most sensitive indicators of stable vitiligo, each with a sensitivity of 99.6% and 100%, respectively.<sup>9</sup> The most specific indicators, with a specificity of 100% and 96.8%, respectively, are the presence of a sharp border and an absence or reticulate pigment network inside the vitiligo patch.

It was reported by Varma and colleagues (2021) that clinically, leukotrichia was noted in 46% of individuals with vitiligo.<sup>6</sup> However, it was discovered that the stability of illness is not connected to the presence or absence of leukotrichia in vitiligo. According to the findings of Thatte et al., the pigmentary network was impaired in 12 (40%) of 30 patients, completely missing in 9 (30%) patients, and restored in 6 (20%) patients.<sup>49</sup> Two of the patients, or 6.7%, had perifollicular hyperpigmentation, while one of the patients, or 3.3%, had perilesional hyperpigmentation. Upon evaluation with UV light, 27 out of 30 patients showed evidence of a diffuse white glow in 90% of cases.

Thatte et al. (2014) correlate histopathologically the dermoscopic findings of progressive lesions in diagnosed instances of vitiligo.<sup>11</sup>

The purpose of Varma et al (2020)'s study was to evaluate the morphological dermatoscopic patterns in vitiligo and identify their link with disease stability.<sup>12</sup>

Jha et al. conducted yet another research in which they investigated the dermoscopic characteristics of vitiligo and

attempted to establish a link between those characteristics and the disease's severity.<sup>13</sup>

Nirmal et al. (2019) investigated the importance of dermatoscopic findings in the activity of vitiligo and developed a cut-off score for stable vitiligo. Six dermatoscopic criteria, including border, pigment network, perilesional hyperpigmentation, perifollicular pigmentation, satellite lesions, and micro-Koebner phenomenon (abbreviation: BPLeFoSK), were compared to Wood's lamp results as the gold standard. 131 vitiligo lesions were evaluated using dermatoscopy. The most sensitive indicators were the lack of satellite lesions and micro-Koebner phenomenon (96.7% and 100%, respectively). The most particular characteristics of vitiligo patches were a sharp border and a pigment network that was either missing or reticulated (91.5%).<sup>9</sup>

Badad et al. (2019) performed an observational research of Dermascopy on 50 vitiligo patients. The majority of vitiligo patients are between the ages of 15 and 50, with a female predominance.<sup>10</sup>

## 5. Conclusion

Histopathology is the gold standard procedure for diagnosing vitiligo, but since it is invasive, it is not often accepted by patients.<sup>14</sup> Therefore, dermatoscopy is emerging as a unique diagnostic method for vitiligo that eliminates the necessity for a skin sample. Based on the finding it can be concluded that dermatoscopy is an excellent method for diagnosing vitiligo and assessing disease activity. Since the stability of vitiligo necessitates surgical intervention, dermatoscopic examination may be of great assistance in determining disease activity. The link between clinical, dermatoscopic, and histologic criteria for disease stability must be evaluated in larger research.<sup>15</sup>

## 6. Patient Consent Statement

The patients in this study have provided written informed consent for the publication of their case information.

## 7. Conflict of Interest

The Authors declare no conflict of interest

## 8. Source of Funding

None.

## References

1. Barman S. Switra and its treatment in Veda. *Anc Sci Life*. 1995;15(1):71–4.

2. Howitz J, Brodthagen H, Schwartz M, Thomsen K. Prevalence of vitiligo. Epidemiological survey on the Isle of Bornholm, Denmark. *Arch Dermatol*. 1977;113(1):47–52.
3. Sahni K, Parsad D. Stability in vitiligo: is there a perfect way to predict it. *J Cutan Aesthet Surg*. 2013;6(2):75–82.
4. Kohli L, Veenstra J, Hamzavi I. Vitiligo assessment methods - Vitiligo Area Scoring Index and Vitiligo European Task Force assessment. *Br J Dermatol*. 2015;172(2):318–9.
5. Purnima G, Gudivada NT, Narasimharao. Dermoscopy - a tool to assess stability in vitiligo. *Int J Contemp Med Res*. 2017;4(10):2066–8.
6. Varma K, Kumar U, Sethi S. A study to compare clinico-histopathological and dermoscopic findings in patients of vitiligo. *Int J Res Dermatol*. 2021;7(2):195–200.
7. Awal G, Kaur J, Kaur K. Dermoscopy in Vitiligo: An emerging armamentarium in diagnosis and activity assessment. *Pigment Int*. 2021;9(1):25–32.
8. Varma K, Kumar U, Sethi S. Significance of dermoscopy in vitiligo. *IP Indian J Clin Exp Dermatol*. 2020;6(4):356–60.
9. Nirmal B, Antonisamy B, Peter D, George L, George AA, Mahabal G, et al. Cross-sectional study of dermatoscopic findings in relation to activity in vitiligo: BPLeFoSK criteria for stability. *J Cutan Aesthet Surg*. 2019;12(1):36–41.
10. Badad AS, Chowdry A, Hogade A. A Study of Role of Dermoscopy In Disease Activity of Vitiligo Patients. *Int J Recent Sci Res*. 2019;10(7):34000–3.
11. Thatte SS, Khopkar US. The utility of dermoscopy in the diagnosis of evolving lesions of vitiligo. *Indian J Dermatol Venereol Leprol*. 2014;80(6):505–8.
12. Varma K, Kumar U, Sethi S. Significance of dermoscopy in vitiligo. *IP Indian J Clin Exp Dermatol*. 2020;6(4):356–60.
13. Jha AK, Sonthalia S, Lallas A, Chaudhary RKP. Dermoscopy in vitiligo: diagnosis and beyond. *Int J Dermatol*. 2018;57(1):50–4.
14. Abdi P, Anthony MR, Farkouh C, Chan AR, Kooner A, Qureshi S, et al. Non-invasive skin measurement methods and diagnostics for vitiligo: a systematic review. *Front Med (Lausanne)*. 2023;10:1200963. doi:10.3389/fmed.2023.1200963.
15. Yang Y, Morriss S, Rodrigues M. Dermoscopy in vitiligo, diagnostic clues and markers of disease activity: a review of the literature. *Clin Exp Dermatol*. 2024;p. llad365. doi:10.1093/ced/llad365.

## Author biography

**Gumma Sindhuri**, Junior Resident

**Shefa Karim**, Junior Resident

**Pooja Patel**, Junior Resident

**Nitin Nadkarni**, Professor

**Sharmila Patil**, HOD

**Kiran Godse**, Professor

**Cite this article:** Sindhuri G, Karim S, Patel P, Nadkarni N, Patil S, Godse K. Dermoscope as a tool to determine the stability of vitiligo. *IP Indian J Clin Exp Dermatol* 2024;10(2):187-191.