



Case Series

A case series on fixed drug eruptions: Benign yet notorious

Prabhat Agrawal¹, Ashish Gautam¹, Aqsa Jafri¹, Nikhil Pursnani^{1*}, Sahil Vij¹

¹Dept. of Medicine, S.N. Medical College, Agra, Uttar Pradesh, India



ARTICLE INFO

Article history:

Received 19-01-2024

Accepted 20-05-2024

Available online 01-06-2024

Keywords:

Cutaneous adverse drug reactions

Drug rash

Fixed-drug eruptions

Dermatological manifestation

Drug-reaction

ABSTRACT

Fixed Drug Eruption (FDE), is a mucocutaneous eruption occurring as a part of adverse drug reaction. They are often localised, well defined, and reoccur on the same sites upon restarting the drug. Here, we are reporting a case series of four patients who developed FDE after consuming these commonly used drugs.

This is an Open Access (OA) journal, and articles are distributed under the terms of the [Creative Commons Attribution-NonCommercial-ShareAlike 4.0 License](https://creativecommons.org/licenses/by-nc-sa/4.0/), which allows others to remix, tweak, and build upon the work non-commercially, as long as appropriate credit is given and the new creations are licensed under the identical terms.

For reprints contact: reprint@ipinnovative.com

1. Introduction

Fixed drug eruption (FDE) or “*éruption érythémato-pigmentée fixe*” was first introduced by Bourns in 1889, and this term was coined by Brocq in 1894.¹ Mucocutaneous eruptions on the skin can be caused by any drug as an adverse effect. Fixed Drug Eruption (FDE) can be localised or generalised, bullous or non bullous and are mostly self-limiting. Identification and withholding of the offending agent are the mainstay of treatment.² Here we are presenting a case series of four commonly prescribed drug causing FDE.

2. Case 1

A 37-year-old female diagnosed as case of Rheumatoid Arthritis presented to our outdoor with appearance of lesions on second and third toe of right foot after taking first dose of Etoricoxib 90 mg (Figure 1). It was nonpruritic, non-tender and she noticed it only while bathing. She had no previous history of any similar lesion in the past. The lesion

started to fade upon removing the drug.

3. Case 2

A 58-year-old male, known case Chronic obstructive pulmonary disease revisited our outdoor department after one day of adding tablet doxofylline 400 mg twice a day as a part of his treatment. He presented with sudden appearance of bullous, non-pruritic, non-tender lesions on dorsal side of left hand (Figure 2). He had a history of taking same medicine in the past followed by appearance of similar lesions. However, after withholding the drug, the lesions gradually faded and disappeared after four weeks.

4. Case 3

A 46-year-old male was prescribed tablet pantoprazole for Gastroesophageal reflux disease. He revisited next day with erythematous and mild pruritic lesions on his left upper and lower lips (Figure 3). These lesions gradually started disappearing after stopping Pantoprazole and completely resolved in four weeks.

* Corresponding author.

E-mail address: drnikhilpursnani@yahoo.co.in (N. Pursnani).

5. Case 4

A 62-year-old female was prescribed B complex capsule for post viral weakness. Next day she came back with erythematous, non-bullous, non-tender lesions on dorsal side of her hands (Figure 4). The tablet was withheld and lesions gradually subsided.

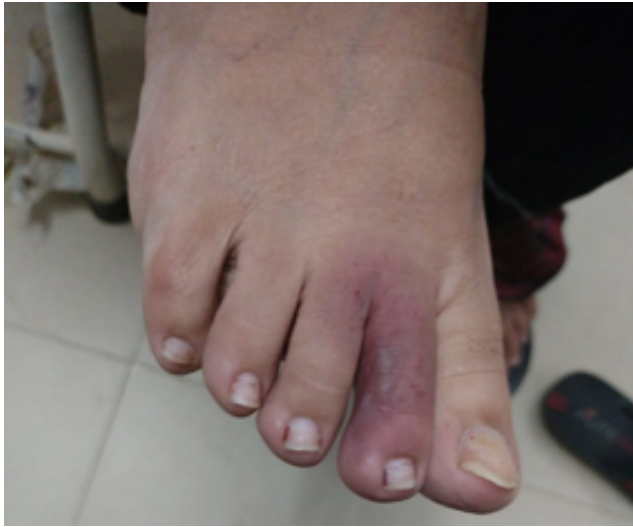

Figure 1: A 37-year-old female diagnosed as case of Rheumatoid Arthritis presented FDE associated with Etoricoxib on 2nd and 3rd toe of right foot.

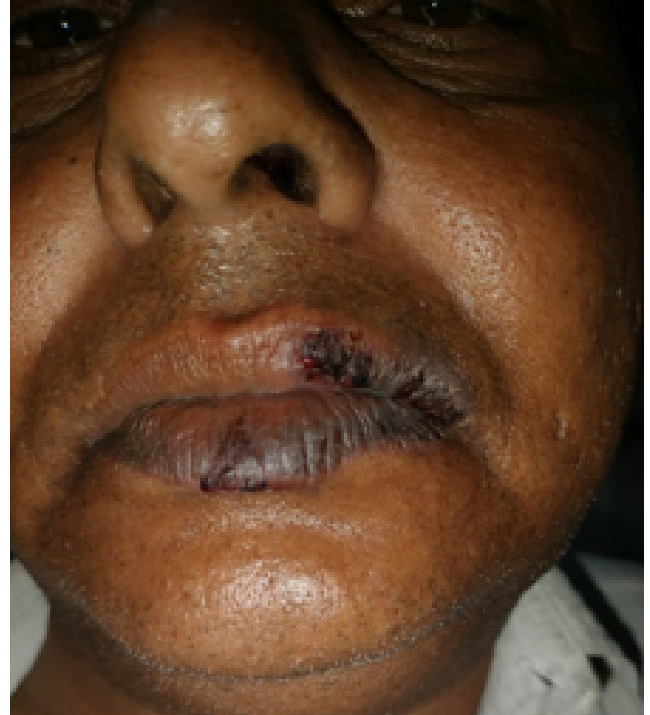

Figure 3: A 46-year-old male known case of GERD presented with FDE associated with Pantoprazole on his left upper and lower lips.

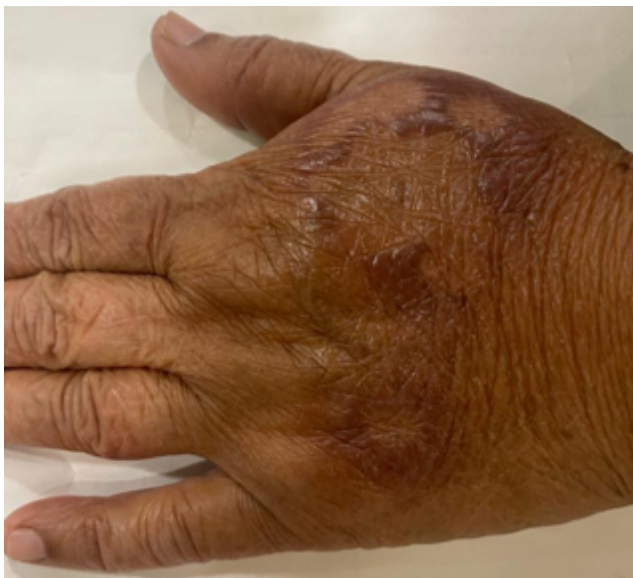

Figure 2: A 58-year-old male, known case COPD presented with FDE associated with doxofylline on dorsal side of left hand.

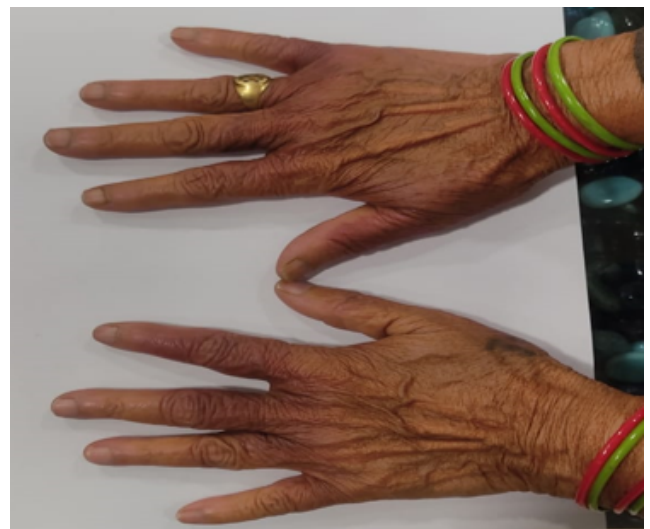

Figure 4: A 62-year-old female diagnosed as post viral illness presented with FDE associated with B complex on dorsal side of her both hands.

6. Discussion

A fixed-drug eruption (FDE) is mediated by immunological processes since it occurs primarily after the use of offending drugs. It is not infective or spontaneously occurring. It is characterized by well demarcated often violaceous lesions which reappears at the same location every time there is exposure to the causative agent. The eruptions sometimes fade whenever medication is discontinued, but it can also result in permanent pigmentation. Type IV hypersensitivity reaction and skin resident T cells are believed to be the key pathogenesis behind FDE. Therefore, even after the initial episode subsides, dormant FDE lesions contain effector/memory CD8+ T cells. These cells are present at the dermal–epidermal junction and remain silent until reexposure with the offending drug. There is reactivation and proliferation of these CD8+ lymphocytes with the production of (IFN)- γ in the local milieu which causes keratinocyte apoptosis. Towards the last phase regulatory T cells are recruited into the lesions and they contain further damage. Cytotoxic T cells undergo apoptosis but a small fraction evades apoptosis by producing keratinocyte derived interleukin (IL)-15 and they persist as skin-resident memory T cells until the next cycle.³

Genitals, Lips, and extremities are the common site of involvement.⁴ Identifying the offending one causing FDE when multiple drugs are prescribed is important to continue treatment. Also, re-exposure may sometimes increase the disease severity. So, knowledge of frequently prescribed drugs associated with FDE is imperative. Fluoroquinolones, metronidazole group, sulfa-containing antibiotics, tetracycline group, penicillin and aminopenicillin, anticonvulsants, non-narcotic NSAIDS are commonly associated with FDE.^{5,6} Removal of offending drug relieves the lesions. Rarely antihistaminic and topical corticosteroids may be needed for aggressive disease.⁷ While it can be safely said, that FDE occur after exposure to an offending antigen due to “molecular mimicry”, but why do they recur on the same very site is still unknown.⁸

7. Conclusion

Fixed Drug Eruptions continues to be an emerging problem and the list of offending drugs is still expanding. Sometimes cross reactivity between similar group of drugs can still elicit an eruption and therefore the physician needs to be ever so cautious while prescribing such drugs.⁷ Although most episodes are benign, however sometimes these lesions can involve large surface areas, can be bullous and therefore sometimes be a serious health hazard.^{1,8} Hence it is imperative for the management of FDE to identify the causative drug or antigen behind it. And these causative

drugs and irritants should be avoided to prevent any recurrence. Even today, the most reliable method to confirm the antigen is still a rechallenge test, but as we advent further the use of skin tests for diagnosis confirmation is gaining momentum.⁸

8. Source of Funding

None.


9. Conflict of Interest

None.


References


1. Anderson HJ, Lee JB. A Review of Fixed Drug Eruption with a Special Focus on Generalized Bullous Fixed Drug Eruption. *Medicina (Kaunas)*. 2021;57(9):925. doi:10.3390/medicina57090925.
2. Lee AY. Fixed drug eruptions. Incidence, recognition, and avoidance. *Am J Clin Dermatol*. 2000;1(5):277–85.
3. Shaker G, Mehendale T, Rosa CDL, C. Fixed Drug Eruption: An Underrecognized Cutaneous Manifestation of a Drug Reaction in the Primary Care Setting. *Cureus*. 2022;14(8):28299. doi:10.7759/cureus.28299.
4. Fadhel NB, Chaabane A, Ammar H, Romdhane HB, Soua Y, Chadli Z, et al. Clinical features culprit drugs and allergology workup in 41 cases of fixed drug eruption. *Contact Dermatitis*. 2019;81(5):336–40.
5. Pai VV, Kikkeri NN, Athanikar SB, Shukla P, Bhandari P, Rai V, et al. Retrospective analysis of fixed drug eruptions among patients attending a tertiary care center in Southern India. *Indian J Dermatol Venereol Leprol*. 2014;80(2):194. doi:10.4103/0378-6323.129435.
6. Mahboob A, Haroon TS. Drugs causing fixed eruptions: a study of 450 cases. *Int J Dermatol*. 1998;37(11):833–8.
7. Jhaj R, Chaudhary D, Asati D, Sadasivam B. Fixed-drug Eruptions: What can we Learn from a Case Series. *Indian J Dermatol*. 2018;63(4):332–7.
8. Ozkaya E. Fixed drug eruption: state of the art. *J Dtsch Dermatol Ges*. 2008;6(3):181–8.

Author biography

Prabhat Agrawal, Professor  <https://orcid.org/0000-0001-5416-3612>

Ashish Gautam, Professor  <https://orcid.org/0000-0002-1837-9851>

Aqsa Jafri, Junior Resident  <https://orcid.org/0009-0006-3317-0884>

Nikhil Pursnani, Associate Professor  <https://orcid.org/0000-0002-0420-6693>

Sahil Vij, Junior Resident  <https://orcid.org/0009-0000-5268-1950>

Cite this article: Agrawal P, Gautam A, Jafri A, Pursnani N, Vij S. A case series on fixed drug eruptions: Benign yet notorious. *IP Indian J Clin Exp Dermatol* 2024;10(2):235-237.