

Congenital vulval syringoma: An uncommon entity

Sarkar Somenath^{1,*}, Tanusree Sarkar², Aparesh Chandra Patra³, Kapildeb Das⁴

^{1,3}Associate Professor, BS Medical College, Bankura, ²Assistant Professor, Burdwan Medical College, Burdwan, ⁴Assistant Professor, Dept. of Dermatology, Malda Medical College, Malda

***Corresponding Author:**

Email: dr.somenathsarkar@gmail.com

Introduction

Syringoma is a common benign appendageal neoplasm of eccrine acrosyringium. Females are twice more commonly affected. Age at onset is usually during adolescence.¹ However further lesions can develop later in the life, may be in the 5th or 6th decade. Clinically, syringoma presents as skin to yellowish or mauve coloured round or flat topped angulated dermal papules size ranging from 1 to 5 mm, with bilateral symmetrical distribution.² Most frequent site of involvement is around the eyelids. Other common sites are other parts of the face, chest, neck with predilection to upper half of the body.^{3,4} Vulval syringoma is very rare with less than fifty cases published in indexed journals till date.

Case Report

A five year old girl was brought to the skin OPD of School of Tropical Medicine, Kolkata with complaints of gradually progressing asymptomatic eruptions around the vulva since birth. Her mother noticed some skin coloured elevated lesions at the time of birth which gradually increased in size as well as in number with increasing age. On examination, multiple brownish dome-shaped to flat-topped shiny papules were seen symmetrically distributed on the either side of the vulva (Fig. 1). Some of the lesions were discrete. But most of the lesions were conglomerated together. Margins of some of the lesions are slightly angulated. No punctum or significant surface change was noted. No similar lesions were noted in other parts of the body. No keratinous material was expressed on pressure and no comedones were found. Darier sign was negative. Examination of hair, nail and mucosa revealed no abnormality. Systemic examination was unremarkable.

Histopathological examination on low power view (10x10x) showed hyperkeratosis, mild acanthosis, follicular plugging. The dermis revealed convoluted and cystic ductular structures (Fig. 2). The high power image showed some of the ducts showed tail like projection from one side of the duct to the stroma giving rise to tadpole like appearance (Fig. 3). The ducts are surrounded by fibrous stroma. The ductular structures are lined by two layers of uninterrupted cells. The ductal lumina contained amorphous debris. Based on the above findings, the case was diagnosed as syringoma. Due to lack of logistic support, immunological tests could not be carried out.

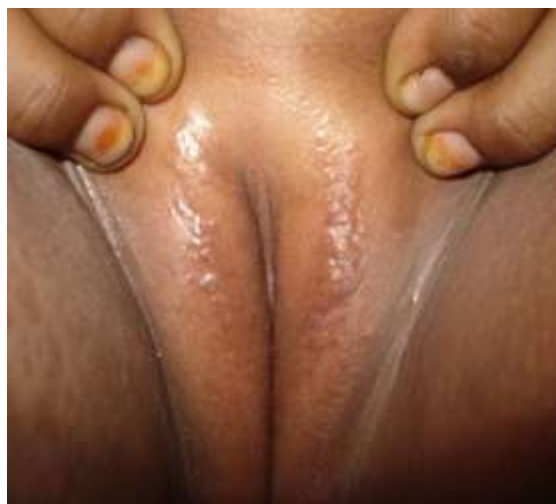

Fig. 1: Multiple flat topped and dome shaped smooth surface brown colour papules on either side of the vulva

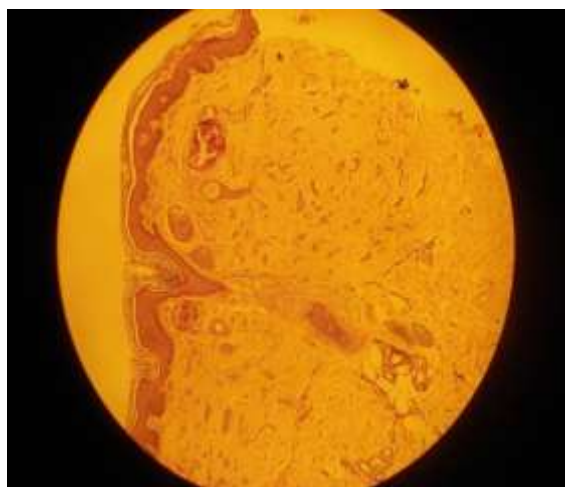

Fig. 2: Convoluted and cystic structures with some epithelial cords with comma-like tails in fibrous stroma (H&E, 10x10)

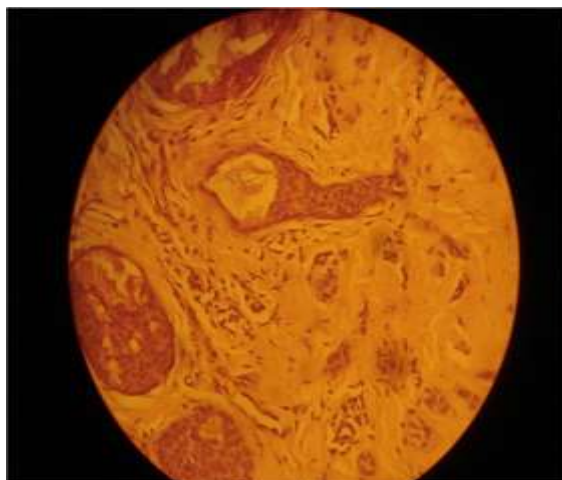


Fig. 3: Epithelial cords with comma-like tails giving tadpole appearance with amorphous material in the lumen (H&E, 10x40)

Discussion

Syringoma is derived from Greek word *syrinx*, which means pipe or tube. It was first described by Kaposi and Biesiadeki as lymphangioma tuberosum multiplex in 1872. Syringoma is a common appendageal tumour of eccrine sweat duct. Clinically syringoma presents with multiple skin to yellowish coloured flat to dome shaped papules with bilaterally symmetrical distribution and usually confined to upper half of the body.^{3,4} Females are twice more commonly affected compared to males. According to Friedman and Butler's classification, there are four principal clinical variants of syringoma: a localised form, a familial form, a form associated with Down syndrome and a generalised form that encompasses multiple and eruptive syringoma.⁵ Syringoma commonly appears during puberty or during third or fourth decade.^{6,7} Syringoma had been reported to be associated with diabetes mellitus, melanocytic nevus, sarcoidosis, elevated carcinoembryonic antigen (CEA), and psychiatric disorders. Increased frequency of syringoma was noted with Ehler-Danlos syndrome.

Most of the cases is asymptomatic and aggravates during summer. Uncommonly vulval syringoma may produce pruritus.⁸ Most frequent site of involvement is around the eyelids. Other common sites are other parts of the face, chest neck with predilection to upper half of the body.^{3,4} Rarely occult syringoma of the scalp are associated with diffuse thinning of hair. In rare instances the lesion may be unilateral and linearly arranged.

Vulval syringoma is an unusual clinical variant. Aggravation of vulval syringoma during menstruation and pregnancy indicates probability of hormonal influence.^{1,9}

Corneino et al were the first to report a case of vulval syringoma in 1971 and subsequently they reported three cases of vulval syringoma in the year

1972.^{10,11} Only forty two cases of vulval syringoma have been found through 'Pubmed' search. With thorough search of English publications, no report of congenital syringoma is found.

The differential diagnosis in our case were verrucous epidermal naevus, lymphangioma circumscriptum, Fox-Fordyce disease, milia, condyloma acuminata, steatocystoma, idiopathic vulvar calcinosis, angiokeratoma, etc. Verrucous epidermal naevus is usually unilateral and having an irregular and verrucous surface. Lymphangioma circumscriptum is having a frog's paw appearance. Milium is a keratin cyst having a dome shaped surface. Steatocystoma are few yellowish firm central papules with central punctum, vulvar calcinosis presents with stony hard lesions on vulva, angiokeratomas are actually telangiectasia with overlying hyperkeratotic surface, comedones though rare on vulva but may present there with a black core. When pruritus vulvae is the presenting complaint vulval syringoma should be differentiated with fox Fordyce disease which presents with yellowish brown papule with itching. Our case presented with multiple brownish flat-topped shiny papules which were symmetrically distributed on the either side of the vulva. The histological features of dilated and cystic eccrine sweat ducts in the dermis within the fibrous stroma with some of these dilated ducts having small comma-like tails, which produced a distinctive picture that resembled tadpoles, clinched the diagnosis of syringoma in our case. We presented the case due to rarity of the topology and the age of onset.

References

- Wallace ML, Smoller BR. Progesterone receptor positivity supports hormonal control of syringomas. *J Cutan Pathol* 1995;22:442-5.
- Thomas J, Majmudar B, Gorelkin L. Syringoma localized to the vulva. *Arch Dermatol* 1979;115:95-6.
- Turan C, Ugur M, Kutluay L, Kükner S, Dabakoglu T, Aydogdu T, Ergün Y, Cobanoglu O. Vulvar syringoma exacerbated during pregnancy. *Eur J Obstet Gynecol Reprod Biol* 1996;64:141-2.
- Belardi MG, Maglione MA, Vighi S, Di Paola GR. Syringoma of the vulva. A case report. *J Reprod Med* 1994;39:957-9.
- Friedman SJ, Butler DF. Syringoma presenting as milia. *J Am Acad Dermatol* 1987;16:310-4.
- Neri I, Marzaduri S, Varotti E, Passarini B. Syringoma: a review of twenty-nine cases. *Acta Derm Venereol (Stockh)* 1998;78:460-2.
- Soler-Carrilo J, Estrach T, Mascaró JM. Eruptive syringoma: 27 new cases and review of the literature. *J Eur Acad Dermatol Venereol*. 2001;15:242-6.
- Gerdson R, Wenzel J, Uerlich M, Bieber T, Petrow W. Periodic genital pruritus caused by syringoma of the vulva. *Acta Obstet Gynecol Scand* 2002;81:369-70.
- Bal N, Aslan E, Kayaselcuk F, Tarim E, Tuncer I. Vulval syringoma aggravated by pregnancy. *Pathol Oncol Res* 2003;9:196-7.
- Carneiro SJ, Gardner HL, Knox JM. Syringoma of the vulva. *Arch Dermatol* 1971;103:494-6.

11. Carneiro SJ, Gardner HL, Knox JM. Syringoma: Three cases with vulval Involvement. *Obstet Gynecol* 1972;39:95-9.