



## Case Series

# Application of microneedling radio frequency in treatment of acne scars- A case series

Sharone Paulprince<sup>1</sup>, Nithiyaa Pavadai<sup>1</sup>, Trishna Vaishali<sup>1\*</sup>

<sup>1</sup>Dept. of DVL, Pondicherry Institute of Medical Sciences, Kalapet, Puducherry, India



## ARTICLE INFO

### Article history:

Received 14-03-2024

Accepted 27-06-2024

Available online 04-09-2024

### Keywords:

Acne scar

MNRF

Laser

## ABSTRACT

Acne vulgaris is a chronic inflammatory disorder commonly seen in adolescents and is often self-limiting. However, post-sequae of inflammation in acne can lead to scarring and severely affects the quality of life of patients. Herein, we describe four cases that showed satisfactory cosmetic results after the treatment of acne scars on the forehead and malar area using a Micro-needling radiofrequency. They were treated with 3 sessions of MNRF 4 weeks apart, showing drastic improvement. Fractional microneedling radiofrequency (MNRF) uses selective RF thermal zone creation without any epidermal or adnexal damage and causes neocollagenesis. MNRF is a recent advancement with superior efficacy with better compliance and lesser side effects.

This is an Open Access (OA) journal, and articles are distributed under the terms of the [Creative Commons Attribution-NonCommercial-ShareAlike 4.0 License](https://creativecommons.org/licenses/by-nc-sa/4.0/), which allows others to remix, tweak, and build upon the work non-commercially, as long as appropriate credit is given and the new creations are licensed under the identical terms.

For reprints contact: [reprint@ipinnovative.com](mailto:reprint@ipinnovative.com)

## 1. Introduction

Acne vulgaris is a chronic inflammatory disorder commonly seen in adolescents and is often self-limiting. However, post-sequae of inflammation in acne can lead to scarring and severely affects the quality of life of patients.<sup>1</sup> There are numerous modalities of treatment for acne scars such as subcision, microneedling, punch excision, chemical peeling and fillers with variable outcomes. Advanced laser techniques such as fractional carbon dioxide (FCO<sub>2</sub>) and fractional microneedling radiofrequency (MNRF) which uses neocollagenesis principle are used nowadays.<sup>2</sup> MNRF is a recent advancement with superior efficacy with better compliance. In this case series, we report 4 patients with acne scars who had significant response to MNRF.

## 2. Materials and Methods

### 2.1. Case 1

A 24-year-old female presented to us with multiple box scars, icepick and rolling scars. She had grade 3 (moderate) of Goodman and Baron global grading system.

### 2.2. Case 2

A 28-year-old male, who was treated for acne one year back and now developed multiple boxcar and rolling scars in the forehead and malar area with grade 2.

### 2.3. Case 3

A 26-year-old woman presented to us with grade 3 scarring, predominantly with icepick, boxcars and rolling scars. She has already undergone fractional carbon dioxide laser 2 years back with minimal improvement.

\* Corresponding author.

E-mail address: [princysarone26@gmail.com](mailto:princysarone26@gmail.com) (T. Vaishali).

#### 2.4. Case 4

A 22 years old female with grade 2 of Goodman and Baron had multiple ice pick, boxcar and rolling scars in malar area.

All these patients were in their second decade with Fitzpatrick skin type IV-V who attended a private dermatology centre from 2021-2023. They were all treated for acne few years back with topical, systemic antibiotics and retinoids. Exclusion criteria included pregnancy, keloidal tendency, active inflammatory lesions, herpes infection, bleeding disorders, undergone any skin resurfacing techniques in 12 months and on retinoids.

#### 2.5. Methodology

Informed and written consent from all patients obtained prior to procedure. They were primed with sunscreen two weeks prior to the procedure. The affected area was cleaned with mild cleanser and then disinfected with 70 % isopropyl alcohol. We did not use any local anesthesia as pain was very minimal.

We used Fractional microneedling radiofrequency machine, Vivace (FDA approved) with 30-61 W bipolar radio frequency, 2 MHz mode and radio-frequency intensity levels from 1 to 10. An insulated cartridge having 36 needles with 0.3mm diameter was used. We did three passes with needles measuring 2.5,1.5 and 0.5 mm over each pass with a variable pulse duration of 400–500ms at level 5 of radio-frequency intensity in rotational stamping method. Needles with 1.5 mm was used in bony areas and superficial scars, whereas patients with predominant ice pick scars received needles with 2.5 mm. After three passes, using monopolar RF mode, with varying depth we did 2 passes all over the face (Woyset vital technique).

Post procedure, ice packs was given to reduce inflammation and liberal use of broad-spectrum sunscreen was advised. Patients did not get any erythema or post inflammatory hyperpigmentation.

### 3. Results

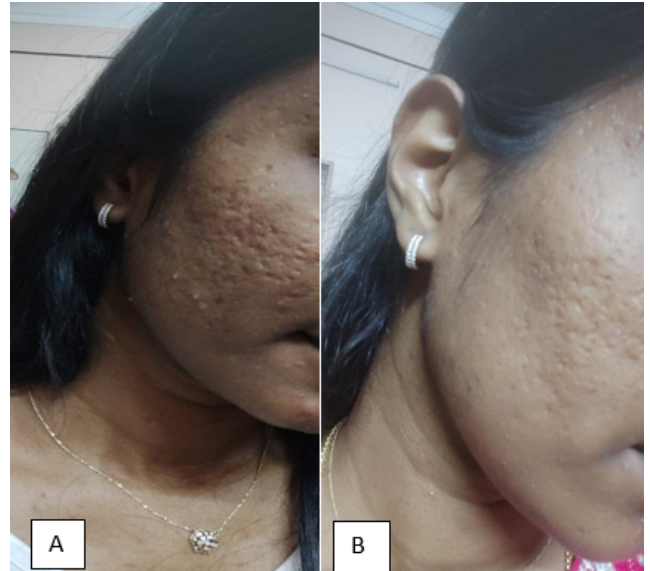All patients received 4 sessions at 4 weeks interval. Baseline and post treatment photographs were taken for all patients. Among 4 patients, all were in their second decade, and we had 3 females and 1 male. Their mean grading of acne scars at baseline was grade 3 by Goodman and Baron qualitative grading.

Goodman and baron quantitative grading showed improvement from 65.30 to 10.12 (80.62%) (Figure 1), Figure 2 showed the improvement from 24.22 to 12.02 (75.23%), in Figure 3 the score improved from 45.06 to 15.04(68.12%), in figure 4 it showed improvement from 54.08 to 12.12 (70.12%). Line diagram comparing the qualitative grades of all patients is shown in Figure 4. On average all patients noticed 60-80 % improvement in scars through visual analog scale, comparison of VAS in each

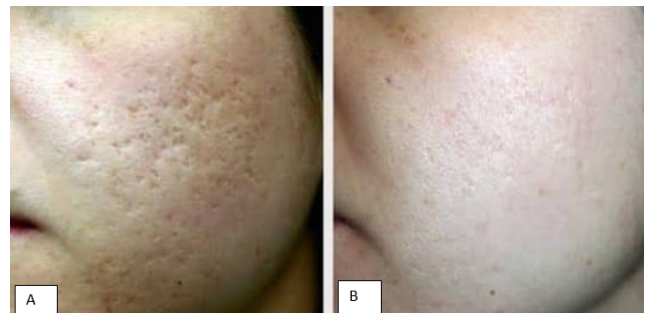patient.

All patients felt significant improvement (76.3%) in reduction of acne scars at end of 3 months after last session. Patients with ice pick scars felt comparatively more improvement than those with boxcar and rolling scars. 50 % of them felt reduction in wrinkling and sebum production along with acne scars. So overall improvement in texture, skin tightening and scarring was seen in them.

None of the patients had any side effects except for mild post procedure erythema. So MNRF had good compliance, lesser complications, less downtime in our patients.



**Figure 1:** a: Grade 3 acne scars; b: Improvement in acne scars from grade 3 to 1 after treatment



**Figure 2:** a: Grade 3 acne scars; b: Improvement in acne scars from grade 3 to 1 after treatment

### 4. Discussion

Acne vulgaris is a chronic inflammatory disorder of pilosebaceous unit. It commonly presents as comedones, papules, pustules and nodules in adolescents. However inflammatory acne progresses to scarring which

**Table 1:** Goodman and baron global scoring criteria -quantitative grading

Grade		Number of lesions		
		1-10	11 -20	>20
A	Milder scarring-macular erythematous, pigmented, mildly atrophic dish like	1	2	3
B	Moderate scarring-moderately atrophic dish like ,punched out small scars with, shallow bases but atrophic area <5mm	2	4	6
C	Severe scarring-punched out with deep but normal bases, punched out with deep abnormal bases, linear or troughed dermal scarring, deep and broad atrophic areas	3	6	9
D	Hyperplastic papular scars	2	4	6
E	Hyperplastic keloidal or hypertrophic scar	Area less than 5, 6 points	AREA 5-20 CM <sup>2</sup> , 12 Points	Area more than 20 CM <sup>2</sup> , 18 Points

**Table 2:** Goodman global scoring criteria -qualitative grading

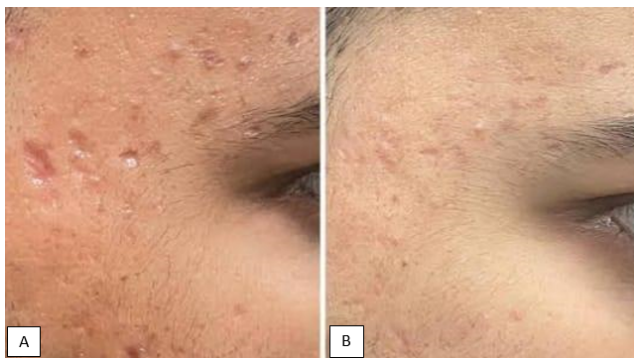
Grade	Level of disease	Characteristics	Examples of scars
1	Macular disease	Erythematous, hyper or hypopigmented flat marks visible to patient or observer irrespective of distance	Erythematous ,hyper or hypopigmented flat marks
2	Mild disease	Mild atrophy or hypertrophy that may not be obvious at social distances of 50 cm or greater and may be covered adequately by make up or normal shadow of shaved beard hair in males or normal body hair if extra-facial	Mild rolling ,small soft papular
3	Moderate disease	Moderate atrophic or hypertrophic scarring that is obvious at social distances of 50 cm or greater and is not covered easily by make up or the normal shadow of shaved beard hair if extra-facial ,but is still able to be flattened by manual stretching of the skin	More significant rolling shallow 'box car' mild to moderate hypertrophic or papular scars
4	Severe disease	Severe atrophic or hypertrophic scarring that is obvious at social distance of 50cm or greater and is not covered easily by makeup or the normal shadow of shaved beard hair in males or normal body hair if extra-facial and is not able to be flattened by manual stretching of the skin	Punched out atrophic (deep box car ), ice pick, bridges and tunnels ,gross atrophy ,dystrophic scars significant hypertrophy or keloid

**Table 3:** Patient and observer scar assessment scale

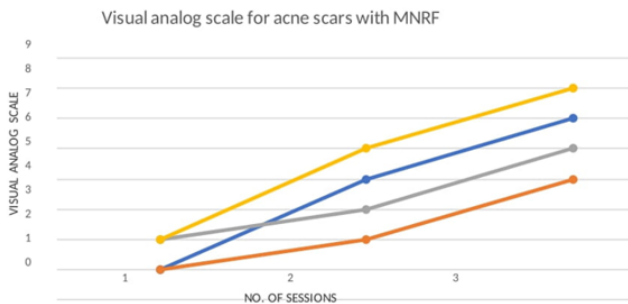
	1	2	3	4	5	6	7	8	9	10
Vascularization										
Pigmentation										
Thickness										
Relief										
Pliability										
Observer scar rating										
Total score: (Minimum 5: Maximum 50)										
1: Normal skin 10: Worst scar imaginable										

**Table 4:** Patient scar assessment scale

	1	2	3	4	5	6	7	8	9	10
Is the scar itching?										
Is the scar painful?										
1:No,No complaints 10: Yes,worst imaginable										
Is the color of the scar different ?										
Is the scar more stiff?										
Is the thickness of the scar different ?										
Is the scar irregular ?										
Overall patient scar satisfaction:										
Total scar: (Minimum :6,Maximum 60)										
1:NO , As normal skin 10: Yes , Very different										



**Figure 3:** a: Grade 4 acne scars; b: Improvement in acne scars from grade 4 to 1 after treatment



**Figure 4:** This graph represents improvement in each patient in 3 sessions

causes severe distress in patients. Scar formation following inflammatory acne takes place in three stages- inflammatory, healing and remodelling phase. Inflammatory phase occurs as erythema with neutrophilic exudation and resolves in 2-4 days. Following that healing phase occurs, where collagen deposition and granulation tissue formation happens. It takes about 2-6 weeks to complete. Last phase is remodelling, where maturation of scar and fibrosis occurs. So complete scar formation may take about few months to a year.<sup>1</sup>

Acne scars are of three types- pigmented, atrophic and hypertrophic scars. Among atrophic scars, there are boxcar

scars, rolling scars and ice pick scars. Atrophic scars are common forms seen in patients affected by acne. Icepick scars are the most common type of scars noted in post acne scenario.

Treatment of acne scars are numerous, which mainly depends on site, depth and type of scars. Chemical peeling (TCA chemical reconstruction of skin scars) are commonly used in icepick scars. Surgical techniques viz subcision, microneedling, punch excision, punch elevation, scar revision and dermabrasion are used for boxcar and rolling scars. Autologous fat transfer and fillers used to treat atrophic scars and intralesional steroids for hypertrophic scars. Laser techniques plays important part in neo collagenesis. Erbium YAG laser and carbon dioxide laser are used which produces fractional photothermolysis and healing. But has higher chance of pigmentation and erythema. Recent advances include microneedling radiofrequency application, which has less downtime and better results compared with routine lasers.<sup>3</sup>

MNRF works by delivering radiofrequency energy through electric current. MNRF machine works in bipolar and monopolar modes. For treatment of acne scars bipolar mode is used where energy is conducted between positive and negative electrodes, whereas in monopolar mode energy is delivered to deeper tissues causing tightening and lifting. Principle of MNRF is selective RF thermal zone creation which causes neocollagenesis and neo elastogenesis. It also increases growth factors and fibroblast proliferation which results in collagen production.<sup>2</sup>

In our study, we It did not produce any significant side effects and had less downtime. Few patients also noticed improvised facial contouring.

There are few studies analysing the efficacy of MNRF. Chandrashekar et al showed 20-80% improvement in acne scars among 31 patients with 80.64% among grade 4 acne scars.<sup>3</sup>Pall et al conducted study among 32 patients and found 61.88 % improvement in scars with MNRF.<sup>2</sup> Rajput et al conducted a study among 50 patients comparing FCO2 and MNRF showed good improvement in both procedures , but side effects and downtime was less in MNRF.<sup>4-8</sup>

## 5. Conclusion

Among various modalities of treatment for acne scars, MNRF is newer and has better improvement and less downtime when compared with other methods. As it does not involve the epidermis or adnexa and causes RF thermal zone in selective areas, the possibilities of pigmentation, scarring and erythema is very less. More further studies in regards with the comparison of MNRF and other lasers should be done to find the exact effectiveness of the procedure.

## 6. Source of Funding

None.

## 7. Conflict of Interest


None.


## References

1. Chilicka K, Rusztowicz M, Szyguła R, Nowicka D. Methods for the improvement of acne scars used in dermatology and cosmetology: a review. *J Clin Med*. 2022;11(10):2744. doi:10.3390/jcm11102744.
2. Pall A, Pall S. An innovative approach of treating acne scars using bipolar rotational stamping and monopolar criss-cross technique with insulated microneedling radiofrequency in Asians. *J Cutan Aesthet Surg*. 2021;14(2):191–191.
3. Chandrashekar BS, Sriram R, Mysore R, Bhaskar S, Shetty A. Evaluation of microneedling fractional radiofrequency device for treatment of acne scars. *J Cutan Aesthet Surg*. 2014;7(2):93–7.
4. Rajput CD, Gore SB, Ansari MK, Shah SM. A prospective, nonrandomized, open-label study, comparing the efficacy, safety, and tolerability of fractional CO2 laser versus fractional microneedling radio frequency in acne scars. *J Cutan Aesthet Surg*. 2021;14(2):177–83.
5. Ochi H, Tan L, Tan WP, Goh CL. Treatment of Facial Acne Scarring With Fractional Carbon Dioxide Laser in Asians, a Retrospective Analysis of Efficacy and Complications. *Dermatol Surg*. 2017;43(9):1137–43.
6. Faghihi G, Poostiyan N, Asilian A, Abtahi-Naeini B, Shahbazi M, Iraj F, et al. Efficacy of fractionated microneedle radiofrequency with and without adding subcision for the treatment of atrophic facial acne scars: a randomized split-face clinical study. *J Cosmet Dermatol*. 2017;16(2):223–9.
7. Majid I, Imran S. Fractional CO2 Laser Resurfacing as Monotherapy in the Treatment of Atrophic Facial Acne Scars. *J Cutan Aesthet Surg*. 2014;7(2):87–92.
8. Ong MW, Bashir SJ. Fractional laser resurfacing for acne scars: a review. *Br J Dermatol*. 2012;166(6):1160–9.

## Author biography

**Sharone Paulprince**, Post Graduate  <https://orcid.org/0009-0008-7801-4783>

**Nithiyaa Pavadai**, Assistant Professor  <https://orcid.org/0009-0006-8911-4937>

**Trishna Vaishali**, Associate Professor  <https://orcid.org/0009-0006-6372-354X>

**Cite this article:** Paulprince S, Pavadai N, Vaishali T. Application of microneedling radio frequency in treatment of acne scars- A case series. *IP Indian J Clin Exp Dermatol* 2024;10(3):348-352.