

A rare case of systemic sarcoidosis with cutaneous and sublingual salivary gland involvement

Shahul Hameed G^{1*}, Jeevan Malaiyan², Chittambalam PC³, Selvam MD⁴, Pradeep Raj⁵

¹Assistant Professor, ³Professor & Head, Dept. of Dermatology, Venereology & Leprosy, ²Assistant Professor, Dept. of Microbiology, ⁴Professor, ⁵Assistant Professor, Dept. of Medicine, Sri Mutukumaran Medical College, Hospital & Research Institute, Chennai

***Corresponding Author:**
Email: shahulg86@gmail.com

Abstract

Sarcoidosis is a systemic granulomatous disorder of unidentified etiology and pathologically characterized by non-caseating granulomas. Majority of patients (~30%) have cutaneous lesions, exhibit different manifestations depending on diverse races whereas some patients develop systemic involvement. Diagnosis is based on a compatible clinical and radiological presentation and evidence of non-caseating granulomas. Here, we report a rare case of cutaneous sarcoidosis with a nodulocystic swelling on the floor of the mouth, which upon biopsy revealed a dense, non-caseating granulomatous infiltrate in the dermis. Identification of systemic involvement was based on laboratory investigations, slit skin smear, sputum smear for acid-fast bacilli (AFB), chest X-ray, pulmonary function tests, computerized tomography (CT), ultrasound of abdomen and radiological examination. The patient was treated successfully and is being reviewed once every two weeks till date.

Keywords: Cutaneous, Granuloma, Papules, Sarcoidosis, Systemic.

Access this article online

Website:

www.innovativepublication.com

DOI:

10.5958/2455-6769.2016.00011.9

Case History

A 45 year old male, a handloom garment trader by occupation presented with a 6 month history of multiple, well defined, erythematous to violaceous papules and plaques over the forehead, scalp, cheek, lower lip, ears and upper arms and a nodulocystic swelling over the floor of the mouth. The erythematous plaque over the forehead was annular in shape and showed central atrophy with surface telangiectasia [Fig. 1]. The erythematous papules were firm in consistency with size ranging from 2 mm to 6 mm. The lesions were asymptomatic and gradually increasing in size and number. He had history of dyspnea on exertion and mild chest discomfort and productive cough with scanty thick mucoid expectoration for 2 years. There was no history of evening rise in temperature, chills, arthralgia, abdominal pain, weight loss, visual disturbances or sensory neural deficit; insect bites, trauma or any other systemic complaint. There was no significant past, personal or family history or drug history. General and systemic examinations were normal. Blood investigation reports revealed elevated erythrocyte sedimentation rate (44mm/90mm) and elevated serum levels of angiotensin converting enzyme (395U/L). Slit skin smear, gram staining, sputum smear for AFB,

Montoux test and fungal culture all were negative. Serum calcium levels were within normal range.

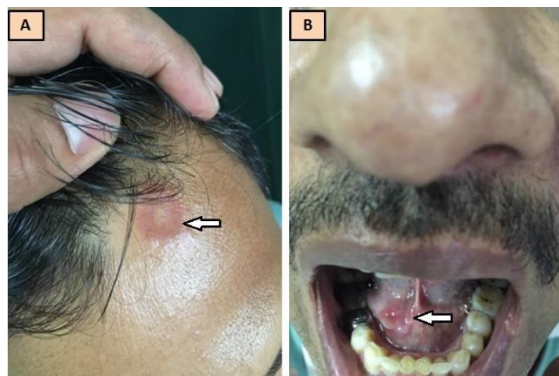


Fig. 1: (A) Multiple, well defined, erythematous to violaceous papules and plaques over the forehead, scalp, cheek, lower lip, ears and upper arms. The erythematous plaque over the forehead was annular in shape and showed central atrophy with surface telangiectasia (B) Nodulocystic swelling over the floor of the mouth

The anteroposterior chest X-ray revealed reticulo-nodular opacities in both lung fields with relative sparing of both apices with bilateral hilar lymphadenopathy and pulmonary function tests showed restrictive lung changes. High resolution computerized tomography of chest revealed scattered miliary nodules, left apical consolidation, left lingular segment, right middle lobe fibrotic scars, subcarinal and bilateral hilar lymphadenopathy and few tiny left perigastric adenopathies [Fig. 2]. Abdominal ultrasound revealed mild splenomegaly. Radiological examination of the

hands and feet and ophthalmologic examination revealed no abnormalities.

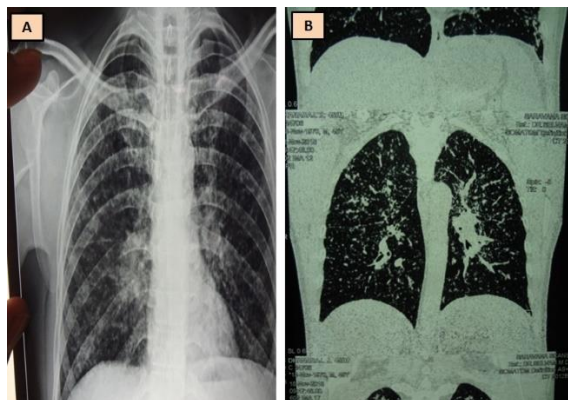


Fig. 2: (A) Chest X-ray showing reticulo-nodular opacities in both lung fields with relative sparing of both apices with bilateral hilar lymphadenopathy. (B) CT scan of chest revealed scattered miliary nodules, left apical consolidation, left lingular segment, right middle lobe fibrotic scars, subcarinal and bilateral hilar lymphadenopathy and few tiny left perigastric adenopathies

Hematoxylin and eosin (H-E) stained sections of the skin biopsy showed variable parakeratosis and focal erosion of the epidermis. The presence of dense, non-caseating granulomatous infiltrates in the dermis was observed. These granulomas were composed of epithelioid histiocytes with abundant eosinophilic cytoplasm and oval nuclei containing a small central nucleolus. Few Langhans giant cells, scattered lymphocytes admixed with few plasma cells were also seen. Excision biopsy of the nodulocystic lesion from the floor of the mouth revealed hyperplastic squamous epithelium with a cyst lined by columnar epithelium enclosing mucinous material, cyst macrophages with islands of mucous glands with proliferation of duct and ductules. In addition, intervening hemorrhagic stroma showing numerous granulomas composed of histiocytes, epithelioid cells; multinucleate giant cells of foreign body type and occasional Langhans giant cells and fibroblasts were present. Few asteroid bodies, which are small, intracytoplasmic, eosinophilic star shaped structures, were observed. Reticulum stain showed intact black reticulin fibres [Fig. 3].

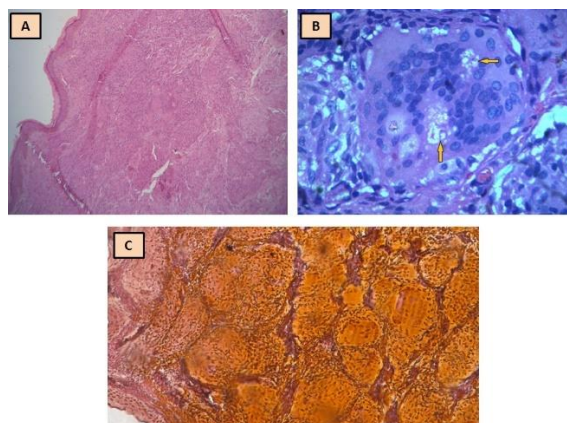


Fig. 3: (A) H-E stain showing epidermis with variable parakeratosis and focal erosion. There is presence of dense, non-caseating granulomatous infiltrate in the dermis. These granulomas are composed of epithelioid histiocytes with abundant eosinophilic cytoplasm and oval nuclei containing a small central nucleolus. (B) Few asteroid bodies, which are small, intracytoplasmic, eosinophilic star shaped structures. (C) Reticulum stains showing intact black reticulin fibres

With the view of all the above observations, a final diagnosis of systemic sarcoidosis with cutaneous and mucosal sublingual salivary gland involvement was made. The patient was started on topical midpotency corticosteroid, oral prednisolone 20mg/day and oral hydroxychloroquine 200mg/day with subsequent improvement of his ailments and is currently under follow up.

Sarcoidosis is a systemic, granulomatous disease of unidentified etiology that can affect the skin, pulmonary, gastrointestinal, cardiac, musculoskeletal, endocrine, and central nervous system^[1,2]. Cutaneous lesions are mainly maculopapules (32.6%) and plaques (36%). In India, the facial lesions accounted as high as 65%^[2]. In the present case, erythematous to violaceous papules and plaques lesions were seen in forehead, scalp, cheek, lower lip, ears and upper arms with systemic involvement which gave a diagnosis of sarcoidosis. Sarcoidosis with extreme variation in site and tissue involvement has been reported in literature. Oral involvement of sarcoidosis is quite unusual. In the review of literature, oral involvement usually appeared in patients with chronic multisystem sarcoidosis. Oral sites have further been described in patients with sarcoidosis, involving the buccal mucosa (18.3%), the gingiva, in form gingivitis and gingival hyperplasia (16.9%), the floor of the mouth (8.5%), the lips (8.5%), the tongue (7%), the palate (4.2%) and the submandibular glands (2.8%). Clinical presentation of sarcoidosis in major salivary glands is usually as painless firm swellings, which do not show variation in the size during meal time^[3]. In this present case we report systemic sarcoidosis with painless sublingual

salivary gland involvement. Recently published data show that, diagnosis is based on compatible clinical and radiological presentation and an evidence of non-caseating granulomas^[4]. In this case, a final diagnosis of systemic sarcoidosis was made based on clinical, radiological and histopathology evidence. In conclusion, sarcoidosis is a relatively common disease but its oral manifestations are fairly uncommon.

Acknowledgement

We sincerely thank the Medical Superintendent, Department of Pulmonology, Pathology, Radiology, Ophthalmology and Dentistry, Sri Muthukumaran Medical College Hospital and Research Institute, Chikkarayapuram, Chennai-600 069, India, for the help rendered.

Reference

1. Ohashi T, Yamamoto T. Subcutaneous sarcoidosis with underlying intramuscular granuloma. *Indian J Dermatol* 2015;60(1):107.
2. Tong C, Zhang X, Dong J, He Y. Comparison of cutaneous sarcoidosis with systemic sarcoidosis: a retrospective analysis. *Int J Clin Exp Pathol* 2014;7(1):372-377.
3. Heera Raveendran, Beena Valappil Thannikunnath, Kanaram Choudhary, Rency Simon. Oral sub lingual sarcoidosis: Report of a rare case and review of literature. *International Journal of Oral & Maxillofacial Pathology*; 2011;2(1):29-32.
4. Uzunhan Y, Jeny F, Crockett F, Piver D, Kambouchner M, Valeyre D, et al. Lung sarcoidosis: Clinical features and therapeutic issues. *Rev Med Interne*. 2016; 37(9):594-607.