

A study of shape of ulnar nerve in leprosy patients

Krishnendra Varma¹, Prashant Harit^{2,*}

¹HOD, ²Junior Resident, Dept. of Dermatology, Venereology & Leprosy, RD Gardi Medical College, Ujjain, Madhya Pradesh

***Corresponding Author:**

Email: prashantharit@gmail.com

Abstract

Background: The most common nerve affected in leprosy is ulnar nerve, which show enlargement and inflammation.

Aims: To study shape of ulnar nerve (UN) in the cubital tunnel and to evaluate the role of high-resolution ultrasonography (HRUSG) in the diagnosis of ulnar nerve changes in leprosy.

Methods: A total of 45 cases of clinically diagnosed leprosy patients with ulnar nerve involvement in the age group of 15-80 years constituted the subject material for present study. This was a cross sectional observational study with 90 arms from 45 patients (90 at cubital tunnel, 90 two centimetres above cubital tunnel). The ulnar nerves were evaluated with 12 MHz small footprint linear array transducer. The ulnar nerve shape was noted. Data analysis was done by using statistical package for social sciences (SPSS) Software.

Results: The shape of ulnar nerve overall (including right and left) shows that majority of patient had oval shape ulnar nerve followed by round and other types. The shape of ulnar nerve is not changed statistically compared to normal. In some of patient due to trauma and other causes of nerve damage, shape had changed to flat or sometime triangular.

Limitations: The authors required 1 year to complete 45 consecutive leprosy patient but the patient has mean disease duration of 15 years.

Conclusion: In 180 ulnar nerves which including ulnar nerve at ulnar notch and two centimetres above ulnar notch, 152 were oval while 14 were round, 7 were triangular and 7 were flattened.

Keywords: Leprosy, Hansen's Disease, Shape, Ulnar Nerve, High Resolution Ultrasonography.

Key Messages: The purpose of this study was to evaluate the morphologic changes in the shape of ulnar nerve in leprosy with HRUSG.

Introduction

Leprosy known as Hansen's disease, hanseniasis, *kushtrog*, *kod* etc is a chronic granulomatous disease caused by *Mycobacterium lepre*, principally affecting peripheral nerves and skin.⁽¹⁾

Apart from clinical palpation, which is subjective, nerve thickening can be assessed objectively by ultrasonography. Present study was conducted to find shape of ulnar nerve changes in leprosy patients. Since one of the hallmarks of leprosy is nerve enlargement. The findings will definitely help in formulating management and in preventing deformities and disabilities.

Clinico-radiological correlation has been attempted by very few investigators: Jain et al. 2009, in her study on sonographical changes of nerves, found increased vascularity, distorted echo-texture and nerve enlargement in leprosy patients.⁽²⁾ They concluded that clinical examination of enlarged nerves is subjective and inaccurate, whereas sonography provides an objective measure of the nerve dimensions and reveals structural changes over a longer length of the nerve.

In a study by Elias Jr et al. (2009), the sonographic examination of three patients showed ulnar nerve thickening without electrophysiological nerve abnormalities, indicating that an affected peripheral nerve may function normally.⁽³⁾ If a sonographic finding is highly suggestive of leprosy neuropathy, it may play an important role in detecting neuropathy.

Leite et al. (2010) study, showed that, compared with other nerves, the ulnar nerve was the most frequently involved.⁽⁴⁾

Suman Jain et al (2009), conclude that sonography is a better diagnostic tool to predict nerve damage as compared to clinical assessment. Nerve damage was sonographically more extensive and was observed in nerves considered clinically normal.⁽²⁾

Methods

In this study over a period of one year, one expert ultrasonographer (radiologist) in our centre examined both elbows of 45 consecutive volunteers. Individuals with elbow pain, infection and any past history of elbow injury or ulnar tunnel syndrome were not included in study. The particulars of each leprosy participant were noted. Real-time sonographic evaluation of the ulnar nerve was performed by the same operator using General Electric Logiq 12 MHz P6 Probe for study. The elbow was studied in the posterior projection with the elbow flexed at 90° and the palm of the hand placed flat on a hard surface, as usually recommended.^(5,6) This position helps in some degree of nerve tension and was preferred over elbow extension. The ulnar nerve is usually seen as a hypoechoic ovoid image that may be in close contact with the medial epicondyle^(5,6) and occasionally seems divided. The shape of ulnar nerve is studied by measuring two maximum diameter of ulnar nerve one at ulnar groove and other two cm above the ulnar groove.

The shape of ulnar nerve is divided into four shapes that is round, oval, flattened and triangular for study purpose.

Likely causes of bias in the study are other peripheral nerve disease and USG is operator dependent. These bias were removed by proper history, clinical examination and investigation to rule out other causes of peripheral nerve disease; while a single expert ultrasonography (USG) operator examined all patients.

Results

A total of 45 patients were consecutively recruited and gave their informed consent to participate in the ultrasound study of their elbows. The total included arms for analysis were 90, which consisted of 180 points that is first point at ulnar notch and second point two cm proximal to ulnar notch.

Shape of ulnar nerve overall (including right and left) at ulnar notch and two cm above ulnar notch shows that majority of patient had oval shape (84.44%) ulnar nerve followed by round (7.78%), Triangular and Flattened were equal (3.89% each).

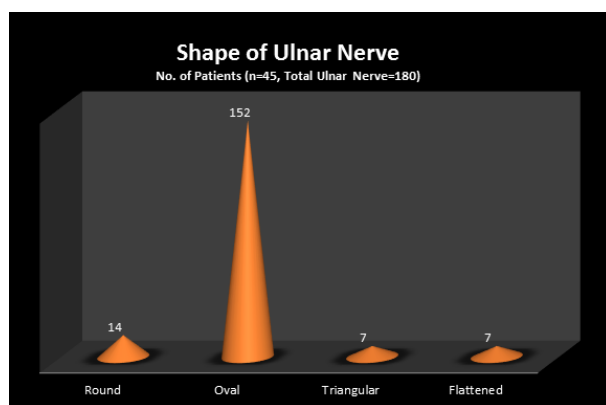


Fig. 1: Shape of Ulnar nerve

Discussion

The understanding of the basic anatomy and the course of the ulnar nerve in the elbow helps in identifying the nerve during ultrasonography. At the cubital tunnel of the elbow, the ulnar nerve lies posterior to the medial epicondyle. The cross section of the ulnar nerve appears as a hypoechoic oval to round structure, which is surrounded by hyperechoic rim of perineurium. It is slightly hyperechoic in comparison to muscle.⁽⁷⁾

The pathophysiology of the nerve enlargement in ulnar neuropathy seems to be a biological response after compression. It results in inflammation, endoneurial oedema, leading to demyelination and axonal degeneration and subsequently fibrosis, growth of new axons, remyelination and thickening of the perineurium.⁽⁸⁾

Thickening of nerve in turn makes the nerves more vulnerable to injury by entrapment or external pressure, for instance, in cases of habitual elbow leaning.^(9,10)

The maximum number of patients had round ulnar nerve (84.44%) at ulnar notch and two cm above ulnar

notch, which is consistent with previous studies.⁽¹¹⁾ As described by Peeters et al. the ulnar nerve at Guyon's canal were visualized more easily using compound imaging ultrasound than using other techniques. The ulnar nerve presented with a circular, oval, or elliptic shape. McCartney et al. also determined the feasibility of visualization of the ulnar nerve with ultrasound.⁽¹²⁾ Heinemeyer et al found ultrasonography allows reliable imaging of the major arm nerves in healthy subjects. Nerve size and structure did not differ significantly between patients with neuropathies and healthy subjects.⁽¹⁴⁾ Cartwright et al studied variation in the shape of the nerve, from a flat oval at the wrist to a circle at the mid-humerus level.⁽¹³⁾

Current technological developments leading to improved image quality, reduced US device sizes and reductions in price will make it possible for US to become a tool that can be used in countries in which leprosy is endemic (Jain et al. 2009).⁽²⁾

Nowadays, HRUSG is not routinely used for ulnar nerve abnormalities because many radiologists and clinicians are unaware of its potential to demonstrate nerve enlargement accurately.

Conclusion

As per our knowledge, this is the first study of its kind in India. In this study we have found there is no statistically significant change in shape of ulnar nerve in leprosy as compared to healthy individual. In the present study only nerve enlargement is seen without any change in shape of ulnar nerve. Limitations of this study include the small sample size and the lack of any clinical data confirming the usefulness of the shape of ulnar nerve in leprosy. From this study we cannot differentiate cause of ulnar nerve enlargement and shape changes from physiological and other pathological cause. We are currently assessing the results of performing these techniques in clinical practice. In this study we did not attempt to visualize other nerve affected in leprosy.

However, we found that the ulnar nerve can be consistently seen in the ulnar notch using ultrasound imaging. The ease of visualizing ulnar nerves in ulnar notch will be helpful as a quick assessment tool for the diagnosis of leprosy.

References

1. Hansen GH. Investigations on the etiology of leprosy. *Norsk Mag Lægevidens* 1874;4:1-88.
2. Jain S, Visser LH, Praveen TLN, Rao PN, Surekha T, Ellanti R et al. High-resolution sonography: A new technique to detect nerve damage in leprosy. *PLoS Negl Trop Dis*. 2009; 3(8):e498.
3. Elias J Jr, Nogueira-Barbosa MH, Feltrin LT, Furini RB, Foss NT, Marques W Jr, dos Santos AC. Role of ulnar nerve sonography in leprosy neuropathy with electrophysiologic correlation. *J Ultrasound Med*. 2009;28(9):1201-9.
4. Leite SN, Barros ARSB, Fonseca MCR, Andrade TAMA, Foss NT, Frade MAC. Effectiveness of Semmes-

- Weinstein monofilaments in leprosy neuropathy in physiotherapy tertiary service. *Hansen Int.* 2010; 35: 9-16.
5. Barr LL, Babcock DS. Sonography of the normal elbow. *Am J Roentgenol.* 1991;157:793-798.
 6. Brasseur JL, Tardieu M. Echographie du système locomoteur. *Imagerie medicale diagnostic.* Masson, Paris: Elsevier; 1999.
 7. Chiou HJ, Chou YH, Cheng SP, *et al.* Cubital tunnel syndrome: diagnosis by high-resolution ultrasonography. *J Ultrasound Med.* 1998;17:643-8.
 8. Beekman R, Visser LH. Sonography in the diagnosis of carpal tunnel syndrome: a critical review of the literature. *Muscle Nerve.* 2003;27(1):26-33.
 9. Beekman R, Wokke JH, Schoemaker MC, Lee ML, Visser LH. Ulnar neuropathy at the elbow: follow-up and prognostic factors determining outcome. *Neurology.* 2004;63(9):1675-80.
 10. Martinoli C, Bianchi S, Derchi LE (2000) Ultrasonography of peripheral nerves. *Semin US CT MR.* 2000;21(3):205-213.
 11. Peeters EY, Nieboer KH, Osteaux MM. Sonography of the normal ulnar nerve at Guyon's canal and of the common peroneal nerve dorsal to the fibular head. *J Clin Ultrasound.* 2004;32(8):375-380.
 12. MCCARTNEY CJ, XU D, CONSTANTINESCU C, ABBAS S, CHAN VW. Ultrasound examination of peripheral nerves in the forearm. *Reg Anesth and Pain Medicine.* 2007;32(5):434-439.
 13. Cartwright MS, Shin HW, Passmore LV, Walker FO. Ultrasonographic findings of the normal ulnar nerve in adults. *Arch of Physl Med Rehabi.* 2007;88(3):394-396.
 14. Heinemeyer O, Reimers CD. Ultrasound of radial, ulnar, median, and sciatic nerves in healthy subjects and patients with hereditary motor and sensory neuropathies. *Ultrasound Med Biol.* 1999;25(3):481-485.