

Efficacy and safety of 10% topical minoxidil, oral finasteride and microneedling in Male Pattern Baldness

Sanjiv Choudhary^{1,*}, Isha Verma², Adarsh Lata Singh³

^{1,3}Professor, ²Resident, Dept. of Dermatology, JNMC, Datta Meghe Institute of Medical Sciences, Wardha, Maharashtra

***Corresponding Author:**

Email: sanjiv_choudhary26@yahoo.com

Abstract

Introduction: There are only few studies with combined treatment for Male Pattern Baldness (MPB) and all of them showed superior efficacy as compared to monotherapies. To the best of our knowledge, no study has been done in past using 10% topical minoxidil as a part of combination therapy.

Aims: To study the safety and efficacy of topical 10% minoxidil, oral finasteride and microneedling in male pattern baldness.

Materials and Method: In this non randomized uncontrolled trial, 25 patients of MPB with age ranged between 20 to 35 years with Hamilton grade II to VII were included. Patients were treated with tab finasteride 1mg once daily + 10% topical minoxidil 1ml twice daily for 6 months. Microneedling was done once in 15 days for 6 months. Assessment of treatment response was done by using patient's satisfactory grading scale of 0- 4. Physician assessment of hair growth was done by using 5 point scale with pre & post clinical photographs, and Trichoscan for assessment of hair shaft diameter and density was done at baseline and at the end of 6 months. Patients were monitored for possible side effects of this combine therapy. Statistical analysis was done using chi-square test.

Results: Patient satisfactory grade revealed that out of 25 patients who completed the study duration 12 patients had grade 4 satisfaction, 10 patients had grade 3 satisfaction and 3 patients had grade 2 satisfactions. On physician assessment scale, excellent improvement was seen in 9 patients, 12 patients showed moderate improvement and in 4 patients mild improvement was noted. Major side effects were not noted in any patient.

Limitation: Further studies with large sample size are needed.

Conclusions: This combination therapy was effective with moderate to excellent response in majority of patients with high patient satisfactory grade at the end of 6 months without any side effects.

Keywords: 10% Minoxidil, Finasteride, Microneedling, combination therapy and Male Pattern Baldness

Introduction

Male pattern baldness (MPB) is characterized by gradual miniaturization of scalp hairs due to inhibitory effect of dihydrotestosterone on hair follicles in a genetically predisposed male patient leading to patterned hair loss. In present clinical practice there has been increase in the number of patients with clinically significant grade of MPB at an early age between 18 to 29 years.⁽¹⁾ MPB may reduce self esteem or confidence leading to negative impact on personality.

Role of oral finasteride and 2-5% topical minoxidil in MPB is well established. Combination therapies have better efficacy compared to monotherapy in the management of MPB. Topical 2% minoxidil in combination with oral finasteride has been proved to be more effective as compared to monotherapies.⁽²⁾ Likewise microneedling in combination with topical 5% minoxidil have shown better efficacy than topical 5% minoxidil monotherapy.⁽³⁾

There is demand of early and faster hair growth in patients with MPB especially in the younger ones. Significant hair growth can be achieved in the initial period of treatment by using combination of treatment modalities with synergistic effect on hair growth leading to better treatment compliance and outcome.

Till date the established combination therapies are 2% topical minoxidil with finasteride⁽²⁾ and 5% topical

minoxidil with microneedling⁽³⁾ and PRP with microneedling.⁽¹⁰⁾

5% topical minoxidil was found to be superior to 2% topical minoxidil.^(4,5) 10% topical minoxidil is available in India since 2007, but there are no reports or studies in literature regarding efficacy and safety of 10% topical minoxidil either as monotherapy or combination therapy. In present nonrandomized uncontrolled trial, combination of 10% topical minoxidil, oral finasteride and microneedling was used to study the response on hair growth in MPB at the end of 6 months.

Materials and Method

This nonrandomized uncontrolled study was conducted at Acharya Vinoba Bhave Rural Hospital attached to Jawaharlal Nehru Medical College Sawangi, Wardha, India during the period January 2013 to December 2013. The ethical clearance was taken from institutional ethics committee. Written informed consent was taken from all the patients. In this study, 25 patients of MPB with age ranged between 20 to 35 years with Hamilton grade II to VII were included. Detailed history regarding the age of onset of hair loss was noted. Patients of MPB between 20-35 years of age without past history of topical and systemic medications for baldness in past 3 months were

included. Patients with history of bleeding disorders, migraine, hypertension and keloidal tendency were excluded. Patients were treated with tab finasteride 1mg once daily + 10% topical minoxidil 1ml twice daily for 6 months. Microneedling was done once in 15 days for 6 months. Needle length of 2mm was used for microneedling under aseptic precautions. Topical anesthesia (topical EMLA cream for half an hour) followed by cold packs for 15 minutes was used before doing microneedling.

Assessment of treatment response was done by using patients satisfactory grading scale of 0-4 for hair growth (0: No improvement; 1: 1-25% improvement; 2: 26-50% improvement; 3: 51-75% improvement; 4: 76-100% improvement). Physician assessment of hair growth was done by the dermatologist not involved in the study (blind) by comparing the clinical photographs taken at baseline and at the end of six months by using 5 point scale (+1-mild improvement; +2-moderate improvement; +3-excellent improvement; 0-no change; -1-deterioration). Photographs of the vertex and crown areas of the scalp were taken in each case. During each photographic session, patients positioning, photographic distance and light exposure was constantly maintained. Patient's satisfactory grading and physician assessment of hair growth was done at the baseline and at the end of 6 months. The pre and post treatment assessment of hair density and diameter was done at baseline and at the end of 6 months using trichoscan. All the patients were monitored for blood pressure at baseline and at every visit. Patients were also asked for side the effects like irritation, headache, excessive facial hairs growth and loss of libido and were counselled to stop the medication if they

experience these side effects during treatment. All the patients complied with the treatment schedules with no drop outs. Statistical analysis was done using chi-square test.

Results

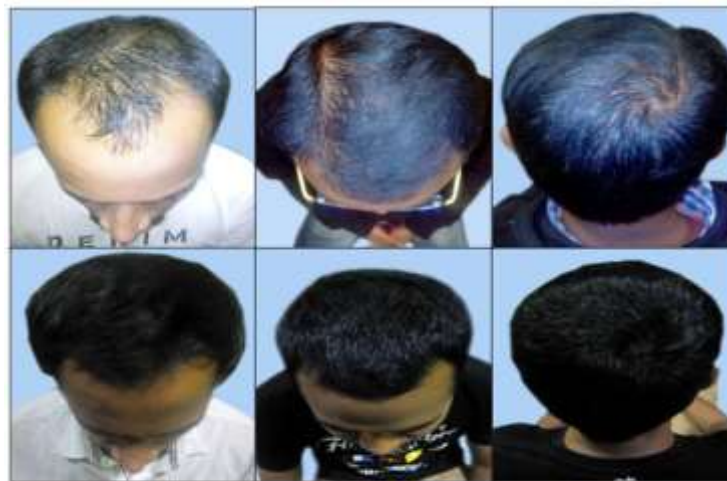After assessment of hair growth by using patient satisfactory grade, out of 25 patients under treatment 12 patients had grade 4 satisfaction, 10 patients had grade 3 satisfaction and 3 patients had grade 2 satisfactions.

By comparing the clinical photographs of patients taken at baseline and at the end of six months using physician assessment scale, excellent improvement (+3) was seen in 9 patients i.e. 36% (Fig. 1), 12 patients showed moderate improvement (+2) i.e. 48% (Fig. 2) and in 4 patients mild improvement (+1) was noted i.e. 16% (Fig. 3). The results of pre and post treatment trichoscan showed significant improvement in hair density (pretreatment mean hair density =5.6 and post treatment mean hair density=11.26) and diameter (pretreatment mean hair diameter =0.033 and post treatment mean hair diameter=0.075) at the end of 6 months showed improvement with significant p value (diameter: p value=0.0001 and density: p value=0.004). Therapeutic outcome assessment in relation to age and grade of MPB was tabulated (Table 1). Mild hair fall was experienced by all the patients during the initial treatment period of two to three months which got gradually stabilized. Some of the patients experienced whitish deposition of crystals due to topical application of minoxidil. Mild pain was experienced by all the patients during micro needling.

Table 1: Therapeutic outcome assessment in relation to age and grade of MPB

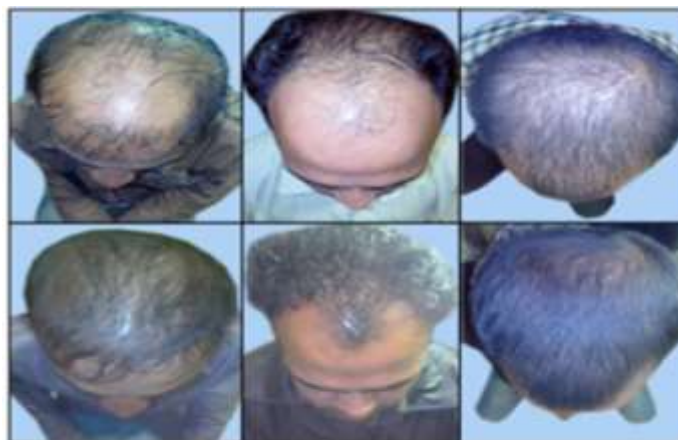Therapeutic outcome assessment in relation to age and grade of MPB				
Patient	Age of pt. (yrs)	Hamilton grade of MPB	Physician assessment of hair growth	Patient satisfactory grading
1	24	IV	+ 3 (excellent)	4
2	22	IV	+ 3 (excellent)	4
3	23	IV	+ 3 (excellent)	4
4	25	V	+ 3 (excellent)	4
5	23	VI	+ 3 (excellent)	4
6	25	IV	+ 2 (moderate)	4
7	22	IV	+3 (excellent)	4
8	24	IV	+3 (excellent)	4
9	25	V	+3 (excellent)	4
10	22	IV	+3 (excellent)	4
11	26	IV	+ 2 (moderate)	4
12	28	IV	+ 2 (moderate)	3
13	32	VI	+ 2 (moderate)	3
14	26	IV	+2(moderate)	3
15	28	V	+2 (moderate)	3
16	29	VI	+2(moderate)	3

17	28	IV	+2 (moderate)	3
18	27	V	+2(moderate)	3
19	30	V	+ 2 (moderate)	4
20	31	VII	+ 2 (moderate)	3
21	26	VII	+ 2 (moderate)	3
22	35	VII	+ 1 (mild)	2
23	28	VII	+ 1 (mild)	3
24	34	VII	+1 (mild)	2
25	35	VII	+ 1 (mild)	2



EXCELLENT RESPONSE

Fig. 1: Excellent response at the end of 6 months



MODERATE RESPONSE

Fig. 2: Moderate response at the end of 6 months

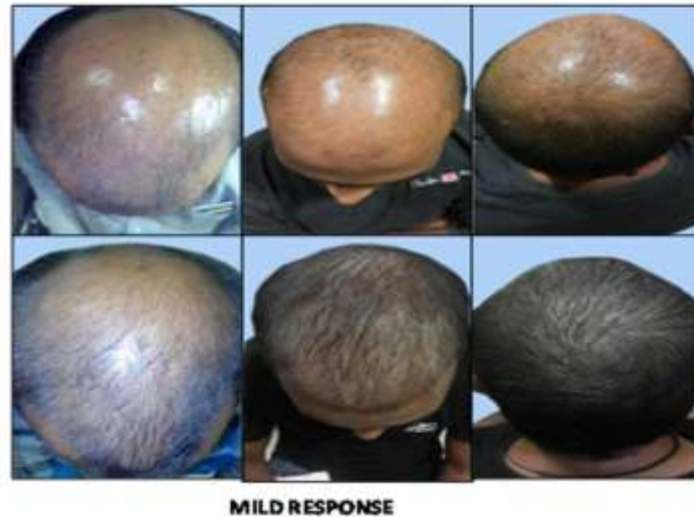

Fig. 3: Mild response at the end of 6 months

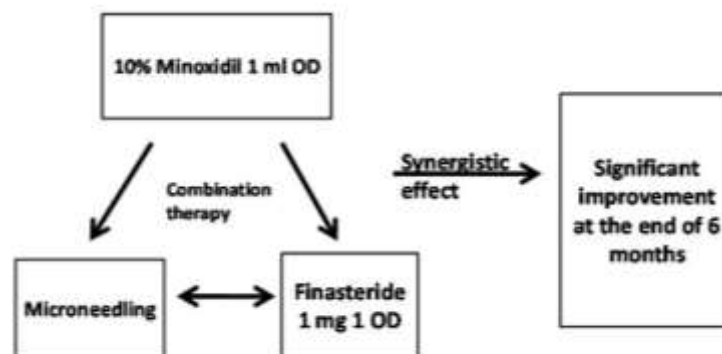


Fig. 4: Synergistic effect

Discussion

Finasteride halts or prevent the miniaturisation of hair follicles by inhibiting type II 5 α reductase isoenzyme. Minoxidil, a potassium channel blocker stimulate hair growth mainly by increasing the blood supply to hair follicle. Microneedling works by releasing various growth factors for hair like platelet derived growth factor, epidermal growth factor and also by activation of stem cells in hair bulge area during the process of wounding the scalp skin.

Schweiger E S et al⁽⁶⁾ in their review reported that efficacy of minoxidil varies from 20% to 40% as per various studies and patients using minoxidil monotherapy continue to go bald in spite of therapy. Price et al 1999⁽⁴⁾ and Olsen et al 2002⁽⁵⁾ in their studies concluded that 5% topical minoxidil was superior to 2% topical minoxidil.

There are evidences in the literature which revealed that combination therapy works better compared to monotherapy in management of MPB. **Khandpur et al.**⁽²⁾ (2002) showed that the combination of minoxidil 2% and finasteride 1 mg was statistically superior to finasteride or minoxidil monotherapies. **Uebel et al** (2006)⁽⁷⁾ reported significant increase (3-52%) in yield

of follicular units pretreated with PRP compared to follicular units alone in hair transplant surgery for MPB. **Greco et al** (2009)⁽⁸⁾ in their comparative study of PRP with microneedling versus microneedling alone observed that combination therapy has better therapeutic outcome than microneedling alone. **Dhurat et al** (2013)⁽³⁾ showed that Microneedling with Minoxidil (5%) treated group was statistically superior to Minoxidil treated group in promoting hair growth in men with AGA.

As far as duration of therapy to show moderate to good response in hair growth is concerned, **Khandpur et al**, in their study showed moderate response in hair growth that too at the end of 1 year using combination of 2% topical minoxidil and finasteride.

Although only 5% topical minoxidil is approved by US FDA, higher 10% minoxidil is available in India since 2007. But there has been no studies done regarding 10% minoxidil either alone or in combination. With this background, we undertook this preliminary uncontrolled non randomized trial. The rationale behind the use of this combined approach with 10% topical minoxidil, oral finasteride and microneedling was to promote early, faster and better

hair growth by synergistic effect in the initial period of treatment to boost up the self confidence in patient leading to better treatment compliance. Results of this preliminary trial with combination treatment approach showed moderate to excellent response using physician assessment scale at the end of six months of therapy. Such an early and fast response has not been reported in previous studies using combination therapy.^(2,3) Early, faster and excellent response in hair growth as observed in present study could be explained on the basis of synergistic effect of the combined treatment modalities with different hair growth promoting mechanisms (Fig. 4). In this study, it was also observed that younger patient responded better than older ones. In patients with extensive grade of MPB (VII) response was also not encouraging (Table 1). Subsequent maintenance of hair growth can be done with lower concentration of minoxidil. During therapy none of the patients showed major side effects like hypotension, headache and loss of libido. Mild irritation due to crystal deposition was noted by 3 patients.

The therapeutic outcome of the various treatment options available for the management of MPB depends upon compliance of the patient which in turn depends upon the duration and efficacy of treatment offered.

References

1. Messenger A, Berker D, Sinclair R. Disorders of Hair. In: Burns T, Breathnach S, Cox N, Griffiths C, editors. Rook's textbook of Dermatology, 8th edn. Oxford: Wiley-Blackwell; 2010.p.66.1-66.100.
2. Khandpur S, Suman M, Reddy BS. Comparative efficacy of various treatment regimens for androgenetic alopecia in men. *J Dermatol* 2002;29:489-98.
3. Dhurat R, Sukesh M, Avhad G, Dandale A, Pal A, Pund P. Randomized evaluator blinded study of effect of microneedling in Androgenetic Alopecia: A pilot study. *Int J Trichol* 2013;5:6-11.
4. Price V, Menefee E, Strauss P. Changes in hair weight and hair count in men with androgenetic alopecia, after application of 5% and 2% topical minoxidil, placebo, or no treatment. *J Am Acad Dermatol* 1999;41:717-21.
5. Olsen E, Dunlap F, Funicella T. A randomized clinical trial of 5% topical minoxidil versus 2% topical minoxidil and placebo in the treatment of androgenetic alopecia in men. *J Am Acad Dermatol* 2002;47:377-85.
6. Schweiger ES, Boychenko O, Bernstein RM. Update on the pathogenesis, genetics and medical treatment of patterned hair loss. *J Drugs Dermatol* 2010;9:1412-9.
7. Uebel CO, da Silva JB, Cantarelli D, Martins P. The role of platelet plasma growth factors in male pattern baldness surgery. *Plast Reconstr Surg* 2006;118:1458-66.
8. Greco J, Brandt R. The effects of autologous platelet rich plasma and various growth factors on non-transplanted miniaturized hair. *Hair Transplant Forum Int* 2009;19:49-50.