

Porphyria cutanea tarda induced by alcohol abuse: A case report

Krishnendra Varma¹, Ujjwal Kumar², Pawan Kumar Khairwar^{3,*}

¹Professor, ²Associate Professor, ³Junior Resident, Dept. of Dermatology, R D Gardi Medical College, Ujjain, Madhya Pradesh, India

***Corresponding Author:**
Email: pk198400@gmail.com

Abstract

Porphyrias are group of inherited and acquired disorders resulting from enzyme deficiency in the metabolic pathway of haem biosynthesis. Among all types of porphyria, the most common type is porphyria cutanea tarda in adults, occurring due to deficiency of enzyme uroporphyrinogen decarboxylase in the metabolic pathway of heme biosynthesis. A 35-year old man presented in opd with chief complaints of recurrent episodes of vesicles, blisters, erosions, raw areas on dorsum of hand and face for 2 years. Local examination revealed multiple erosions with adherent crusting, atrophic plaques of healed lesions over the face and multiple hyperpigmented macules with scarring, erosion and raw areas present over dorsum of the hands. Laboratory findings showed abnormal liver profile and elevated zinc protoporphyrin and coproporphyrin levels. Urine revealed coral pink fluorescence under woods lamp. Histology of the skin showed epidermal spongiosis, subepidermal blister with minimal inflammatory cell infiltrate in the dermis. Treatment given were sun screen lotions, hydroxy-chloroquine, avoidance of triggering factors and alcohol discontinuation. Patient showed marked improvement in skin lesions.

Keywords: Porphyria, Gunther's disease, Uroporphyrinogen III synthase deficiency.

Introduction

Porphyrias are group of inherited and acquired disorders resulting from enzyme deficiency in the metabolic pathway of haem biosynthesis. There is excessive accumulation of porphyrin or its precursor in the sun-exposed areas. Among all types of porphyria, the most common type is porphyria cutanea tarda in adults, occurring due to deficiency of enzyme uroporphyrinogen decarboxylase in the metabolic pathway of heme biosynthesis, resulting in accumulation of uroporphyrinogen which leads to blistering, increased skin fragility, pigmentation and sclerodermoid changes, hypertrichosis and scarring alopecia.¹ Rarely patient may present with ocular manifestations such as conjunctivitis, photophobia and excessive tearing. Constitutional features such as insomnia, anorexia, constipation or diarrhoea can also reported. Alcohol, smoking, estrogen, polychlorinated hydrocarbons, iron overload are aggravating factors for PCT. Some viral infections such as HIV and hepatitis C and various liver diseases are also reported to aggravate PCT.²

Case Report

A 35-year old man presented in opd with chief complaints of recurrent episodes of vesicles, blisters, erosions, raw areas on photoexposed body part (face, dorsum of hand, V of chest and feet) since last 2 years. Lesions healed with scarring, hypopigmented and hyperpigmentation macules. The patient reported that he had not developed any new blister for a few weeks. There was no history of any medications and no history of similar complaints in any family members. The patient had a history of alcohol intake (100-200ml/day) from last 8 years. Local examination revealed some

erosions with adherent crusting, atrophic plaques of healed lesions over the face (Fig. No. 1, 2) and multiple hyperpigmented macules with areas of shallow scarring, erosions and raw areas present on dorsum of the hands. (Fig. No. 3) Hypertrichosis over face was marked and digital resorption was present in both hands. Laboratory findings showed abnormal liver profile and elevated zinc protoporphyrin and coproporphyrin levels. Urine revealed pink fluorescence under woods lamp. Histology of skin showed epidermal spongiosis, subepidermal blister with minimal inflammatory cell infiltrate in the dermis (Fig. No. 4). Patient was started on oral hydroxy-chloroquine (200 mg), sunscreen, alcohol discontinuation. Marked improvement was noticed over duration of 10 months in skin lesions.

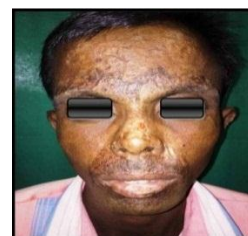

Fig. 1:

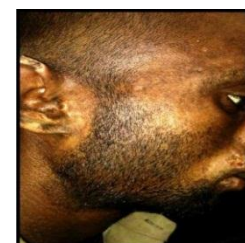


Fig. 2:

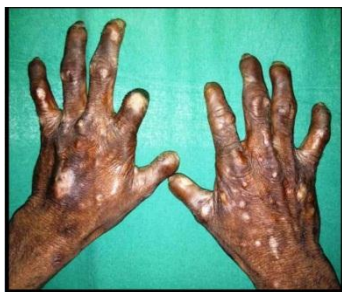

Fig. 3:

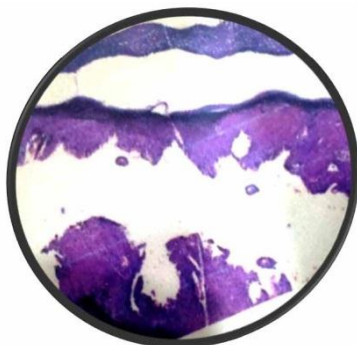


Fig. 4:

Discussion

Porphyria cutanea tarda (PCT) is the most common type of porphyria in adult age group. There is accumulation of photosensitive porphyrins in the photoexposed body parts as a result of defect in heme biosynthesis, in fourth or fifth decades of life. It is clinically characterized by skin fragility, pigmentation and blisters on sun-exposed parts such as the dorsal hands, forearms and face. Blisters rupture to form erosions and shallow ulcers that heal slowly with scarring, hypopigmentation and hyperpigmentation. Sclerodermatous changes can be found in up to 30% of patients.³ PCT has been classified into four types. Uroporphyrinogen decarboxylase level are reduced in both acquired and inheritance types of PCT. Type I is commonest type with non-familial inheritance. The acquired or sporadic form accounts for 75% of PCT cases.⁴ The enzymatic defect is restricted to the liver. Factors like smoking, alcohol, estrogen, iron overload, hepatic siderosis, hydantoin and viral infections (HIV and HCV) aggravate symptoms. Type II is inherited as autosomal-dominant form in this type enzyme deficiency is present in all tissues. Mutation in the UROD gene is seen in 20%-30% of patients with familial PCT. Clinical presentation and risk factor similar to sporadic type, but usually earlier in life. Type III is rare form of hereditary PCT with decrease activity of enzyme only in liver.⁵ Type IV also known as toxic PCT due to toxic chemicals such as chlorinated hydrocarbons, hexachlorobenzene etc. Use of alcohol was a common precipitating factor in patients of PCT, but all alcohol users do not found to have this disease. It causes increase iron absorption and stimulates ALA synthase.

There is production of free radicals, reactive oxygen species, leading to oxidative changes and inhibition of UROD.⁶ The urine sample under Wood's light examination fluoresce with pink or coral-red. Complete blood count (CBC), urea, creatinine, serum ferritin, serum bilirubin, prothrombin time and hepatic enzymes, should be performed. Histopathology of PCT reveals a epidermal spongiosis, subepidermal blister with minimal inflammatory cell infiltrate in the dermis. Few treatment modalities for PCT has been used like avoidance of all possible precipitating factors (alcohol and estrogen etc), avoidance of sun exposure, use sun screen lotions, avoiding skin trauma, antimalarial medications (chloroquine and hydroxychloroquine) and phlebotomy. In present case we prescribed sun screen lotions and hydroxychloroquine (200 mg) given twice a week. We observed marked improvement in skin lesions.

Conclusion

Porphyrias have varied clinical presentation, severity, prognosis and pose a diagnostic and therapeutic challenge. Porphyria cutanea tarda needs high degree of suspicion in patients presenting with hypertrichosis, multiple bullae, erosions, skin fragility, hypopigmentation and hyperpigmentation on sun-exposed parts of body. Screening test for urinary porphyrins (uroporphyrins and coproporphyrins) may help in diagnosis of porphyria. Other relevant investigations may include CBC, serum ferritin, liver function test and gene screening should be done. The patient should be monitored closely, for treatment response and relapse.

References

1. Sassa S. Modern diagnosis and management of the porphyrias. *Br J Haematol.* 2006;135:281-92.
2. Tarwater K, Misra S, Misra M. Type I (sporadic) porphyria cutanea tarda in a hemodialysis patient: A case report. *Hemodial Int.* 2008;12:38-42.
3. Stevens HP, Ostlere LS, Black CM, Rustin MHA. Generalized morphea secondary to porphyria cutanea tarda. *Br J Dermatol.* 1993;129:455-7.
4. James WD, Berger TG, Elston DM, eds. *Andrews' Diseases of the Skin: Clinical Dermatology.* 11th ed. Philadelphia: Saunders/Elsevier; 2011. Chapter 26, Errors in Metabolism; p.511-512.
5. Caballes FR, Sendi H, Bonkovsky HL. Hepatitis C, porphyria cutanea tarda and liver iron: an update. *Liver Int.* 2012 Jul;32(6):880-93.
6. Bleasel NR, Varigos GA. Porphyria cutanea tarda. *Aust J Dermatol.* 2000;197-208.