

Bowen's disease: Case report

Krishnendra Varma¹, Harsh Vardhan Shesha^{2,*}, Ujjawal Kumar³

¹Professor and Head, ²Junior Resident, ³Associate Professor, Dept. of Dermatology, R.D. Gardi Medical College, Ujjain, Madhya Pradesh, India

***Corresponding Author:**

Email: singingshesha05@gmail.com

Abstract

Bowen's disease also known as squamous cell carcinoma in situ, a rare form of progressive, intraepidermal carcinoma, first described by John T. Bowen in 1912. We report a case of 62-year-old elderly male, retired teacher who presented with history of gradually expanding, asymptomatic, Pinkish-reddish raised lesion present on right thigh and left lumbar region since five years. Examination revealed sharply-demarcated, slightly elevated, erythematous, scaly and crusted plaque with dry and rough surface. Histological examination showed Hyperkeratosis, parakeratosis, with moderate lymphocytic infiltrate in upper dermis. There was full Thickness anaplasia of the epidermis and atypical keratinocytes which are disorderly arranged.

Keywords: Squamous cell carcinoma in situ, Erythroplasia of Queyrat, Solar damage, Arsenic, Caucasian.

Introduction

Bowen's disease also known as squamous cell carcinoma in situ, is a rare, progressive, intraepidermal carcinoma was first described by John T. Bowen in 1912. The disease affects both skin and the mucosa, if remain untreated, about 8% of such cases can progress to develop malignancy. Bowen's disease mostly occurs after the age of 60 years but may occur at any age. It occurs predominantly in women (70–85% and more in whites).¹ It usually presents as a persistent, progressively growing, well-demarcated, erythematous patch or plaque, having scaly or crusted surface. The incidence of disease is 1.42/1000 among caucasian population.² Solar damage, arsenic, immunosuppression, viral infection and chronic skin injury are the precipitating causes. The risk of progression into invasive SCC is 3–5% in extragenital lesions and about 10% in genital lesion disease (Erythroplasia of Queyrat) (10%).³

Case Report

We report a case of 62-year-old elderly male, retired teacher who presented with history of gradually expanding, asymptomatic, pinkish-reddish wavy raised lesion present over right thigh and left lumbar region since 5 years. There was no history of pain, often associated with itching. Physical examination revealed sharply-demarcated, slightly elevated, erythematous, scaly and crusted plaque measuring about 3cm x 4 cm in size on anterior aspect of upper 1/3 rd of right thigh and 3 cm x 3 cm in left lumbar region. The surface of lesion was dry and had well-defined borders. The lesion was non tender, non-indurated and with no local rise of temperature. There was no history of trauma preceding the lesions, history of drug intake or associated systemic illness, exposure to chemicals or toxins or application. All routine investigations including hemogram, biochemical test, liver function test, kidney function test were in normal limits. HIV and VDRL were non-reactive. Histological examination showed

Hyperkeratosis, parakeratosis, and upper dermis with moderate lymphocytic infiltrate. There was full thickness anaplasia of the epidermis and atypical keratinocytes which are disorderly arranged.

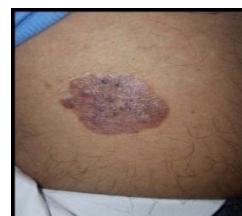

Fig. 1: Shows a solitary plaque over right thigh, erythematous, sharply-demarcated, dry, rough, scaly and crusted plaque approx. 3cm x 4 cm in size

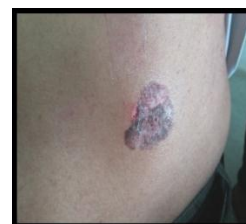

Fig. 2: Shows a single erythematous of about 3 cm x 3 cm in left lumbar region

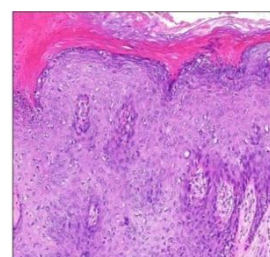


Fig. 3: Skin biopsy shows hyperkeratosis, parakeratosis, with moderate lymphocytic infiltrate in upper dermis. There was full Thickness anaplasia of the epidermis and atypical keratinocytes which are disorderly arranged.

Discussion

Bowen's disease is a form of squamous cell carcinoma in situ. It typically presents as asymptomatic, discrete, progressively enlarging, erythematous, scaly, crusted plaque having well-defined irregular border. Lesion may have various atypical presentations, hyperkeratotic, verrucous, psoriasiform, atrophic, irregular and pigmented variants have been reported.⁴ The lesion may present on sun-exposed and non-sun-exposed areas of skin. The disease predominantly affects older people and occurs on sun-exposed sites. Differential diagnosis of Bowen's disease include: Psoriasis, basal cell carcinoma, lupus vulgaris, benign lichenoid keratosis, leishmaniasis. The disease has good prognosis. The chances of progression into invasive squamous cell carcinoma is 5%, of them one-third may metastasize.

Multiple treatment modalities are available including medical and surgical. Medical management includes topical therapy with 5-fluorouracil and imiquimod 5% cream.⁵ Cryodestructive procedure includes, cryotherapy, radiotherapy and photodynamic therapy. Surgical options include simple excision with 4 to 5mm margin around well-defined tumors or less than 2cm in diameter and wide excision with atleast 6mm margin for large tumors. Other surgical modalities include Mohs micrographic surgery, curettage, electrodesiccation and laser ablation. Because most treatments have a recurrence risk, patient is follow for 6 to 12 months. Our patient was referred to surgery department where excision was done. There was no recurrence in last 6 month.

References

1. Gupta S, Nutan, Dogra S, Kanwar AJ. Bowen Disease over photoprotected site in an Indian male. *Dermatol Online J.* 2009 Oct 15.15(10):16.
2. Reizner GT, Chuang TY, Elpern DJ, Stone JL, Farmer ER. Bowen's disease (squamous cell carcinoma in situ) in Kauai, Hawaii. A population-based incidence report. *J Am Acad Dermatol* 1994;31:596-600.
3. Morton CA, Birnie AJ, Eedy DJ. British Association of Dermatologists' guidelines for the management of squamous cell carcinoma in situ (Bowen's disease) 2014. *Br J Dermatol.* 2014 Feb. 170(2):245-60.
4. Ragi G, Turner MS, Klein LE, Stoll HL Jr. Pigmented Bowen's disease and review of 420 Bowen's disease lesions. *J Dermatol Surg Oncol* 1988;14:765-9.
5. Moreno G, Chia AL, Lim A, Shumack S. Therapeutic options for Bowen's disease. *Australas J Dermatol* 2007;48:1-8.