

Efficacy of long pulsed Nd:YAG laser in the treatment of hirsutism

Rajasekar Jansy¹, Navakumar Manickam^{2,*}, Muthusamy Kandasamy³, Kannan Gopalan⁴, Dinesh Revathi⁵

¹Post Graduate Student, ²Assistant Professor, ³Professor and HOD, ⁴Professor, ⁵Consultant, Dept. of Skin & STD, Vinayaka Mission's Kirupananda Variyar Medical College, Salem, Tamil Nadu, India

***Corresponding Author:**

Email: drnava2k3@gmail.com

Abstract

Introduction: Hirsutism is a psychologically distressing problem. Laser, do not provide permanent hair removal; but they are popular due to selective hair damage, decreased pain feeling, lesser time consumption, longer hair free interval and fewer side effects.

Aim: The aim of our study was to evaluate efficacy and safety profile of Nd:YAG laser in the treatment of hirsutism.

Materials and Methods: Forty females of age 18-35 with hirsutism were included in our study. Each patient was examined and their skin type noted and hirsutism graded according to Ferriman-Galleway score. Four sessions with Nd:YAG laser were delivered to all patients at 4 to 6 week intervals. Photographic evaluations and percentage of hair reduction was done before each session and final assessment noted at 6th month.

Results: Thirty two patients completed all treatment sessions. Good hair reduction (50-75%) was seen in 28 patients after first treatment session. After 3 sessions, excellent hair reduction (>75%) was noted in 10 patients and good hair reduction in 18 patients. At 6th month, excellent hair reduction was seen in 12 patients and good response was noted in 16 patients. Side effects noted in our study were post procedure erythema and perifollicular edema (50%).

Conclusion: The results of this study support safe and effective use of long-pulsed, 1064 nm Nd:YAG laser for hair removal in Indian patients.

Keywords: Hirsutism, Nd:YAG laser, Chin, Lip, Hair reduction.

Introduction

Hirsutism is a disorder of excess growth of terminal hair in an androgen-dependent male distribution in women, including the chin, upper lip, breasts, upper back and abdomen.¹

Various medical and dermatocosmetic treatment options are available for hirsutism. Dermatoscosmetic options are hair bleaching, shaving, depilation with tweezers and waxing. Electrolysis as well as laser and light source epilation are the available methods for definite depilation. Alexandrite, Nd:YAG and diode are the types of lasers used for this purpose.²

Hair removal lasers generally work on the principle of selective photothermolysis, based on selective absorption of laser energy by the components of the hair follicle. The target chromophore is melanin contained by the follicle, which has a broad absorption spectrum. Wavelengths between 700 and 1000 nanometers (nm) are selectively absorbed by melanin.³

The long pulse Neodymium-yttrium aluminium — garnet laser (Nd:YAG laser) can be safely used in all skin types, including tanned patients. Large coverage areas and fast repetition rates allow large areas to be treated quickly.⁴ It is less effective for fine and light hair. Due to longer wavelength, Nd:YAG (1064 nm) lasers partially absorb melanin but deeper penetrance is achieved. It is safely utilized in dark-skinned patients.

Objectives

The present study was to evaluate the efficacy and safety profile of Nd:YAG laser in the treatment of hirsutism.

Materials and Methods

A prospective study to evaluate the efficacy and safety profile of Nd:YAG laser in the treatment of hirsutism was planned and carried out during the period of January 2016 to September 2017 in a specialised laser centre, Salem. The study group composed of 40 females with hirsutism.

Female patients of age 18-35yrs and patients who were willing for investigations were included in the study. Patients who were not willing for regular follow-ups, patients with active herpes infection, keloidal tendencies, pregnant and lactating women, patients with unrealistic expectations were excluded.

Information regarding demographic features, site affected, duration of the complaints, treatment history, associated disorders and family history were obtained. Each patient was examined and their skin type noted and hirsutism graded according to Ferriman – Galleway score. Patients were treated with a long-pulsed Nd:YAG laser (1064 nm, 5 mm spot size, fluence 40-50 J/cm²). Four consecutive treatments with Nd:YAG laser were delivered to all patients at 4 to 6 week intervals. Photographic evaluations were obtained at baseline, before each session and final assessment was done at 6th month. Percentage of hair reduction was noted before each session and final assessment was done at 6th month. The percentage of hair reduction was determined by subjective assessment of hair counts. Efficacy was graded according to a 4-point scale from excellent to poor. Excellent: >75%

reduction; good: 50-75% reduction; fair: 25-50% reduction and poor: <25% reduction in hair density.

Results

Our study included 40 females with facial hirsutism in the age group of 18-35 years. Maximum number of patients were in the age group of 18- 25 years.

Eighteen patients (45%) had lip, chin and body hair involvement (Table 1); 14 patients (35%) had increased hair growth in both lip and chin; 5 patients (12%) had lip involvement exclusively; 2 patients (5%) had chin involvement and 1 patient (3%) had lip and body hair involvement. Among 40 patients, 23 patients had complaints for 1- 5 years, 16 patients had complaints for 5-10 years and 1 patient had the complaint for less than a year.

Table 1: Site involved in the study population

Site	No. of Patients
Lip	5
Chin	2
Lip, chin	14
Lip, body hair	1
Lip, chin, body hair	18

Among 40 patients, 28 patients had no history of drug intake, 6 patients were on oral hypoglycemic agents, 4 were on hormones and 3 were on antiandrogens. Out of 40 patients, 24 patients had positive family history.

Associated disorders noted were PCOD in 12 patients (Table 2), obesity, thyroid dysfunction, and dyslipidemia in 1 patient each. Out of forty patients, 25 had skin type V and 15 patients had skin type IV.

Table 3: Percentage of hair reduction in the study population

	At 4 weeks	At 8 weeks	At 12 weeks	At 6th month
Excellent (>75% reduction)	-	2	10	12
Good (50-75% reduction)	28	26	18	16
Fair (25-50% reduction)	12	9	4	4
Poor (< 25% reduction)	-	-	-	-
Lost to follow up	-	3	3+5	Total -8

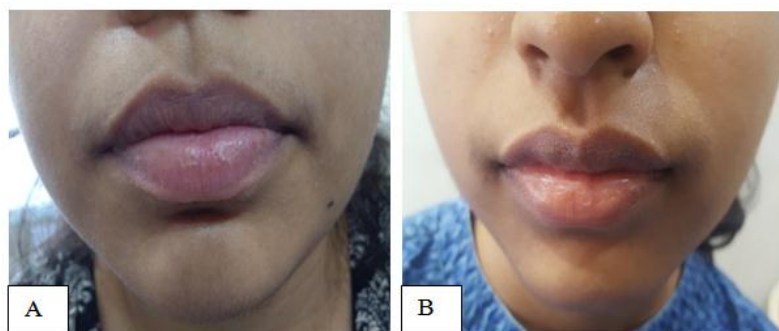

Fig. 1A: Upper lip and chin at first visit; Fig. 1B: Upper lip and chin at 6th month with almost complete hair reduction

Table 2: Associated disorders in the study population

Associated Disorders	No. of Patients
PCOD	12
Obesity	1
Thyroid dysfunction	1
Dyslipidemia	1
Nil	25

Among 40 patients, 28 patients had good hair reduction (50-75%) and 12 patients had fair hair reduction (25-50%) at the end of 4 weeks (Table 3). At 8 weeks, 2 patients had excellent hair reduction (>75%), 26 patients had good hair reduction, 9 patients had fair hair reduction and 3 patients were lost to follow up. At 12 weeks, 10 patients had excellent hair reduction, 18 patients had good hair reduction, 4 patients had fair hair reduction and five more patients were lost to follow up. At the end of 6th month, 12 patients had excellent hair reduction, 16 patients had good hair reduction and 4 patients had fair hair reduction.

Among 40 patients, 38 patients had lip involvement, of which 11 had excellent hair reduction at the end of 6th month, 15 patients had good hair reduction, 4 had fair hair reduction and 8 patients were lost to follow up. Thirty four patients had chin involvement, of which 10 patients had excellent hair reduction by the end of 6th month, 13 patients had good hair reduction, 4 patients had fair hair reduction and 7 were lost to follow up.

In our study, side effects noted were post procedure erythema and perifollicular edema, seen in 50% of the patients.

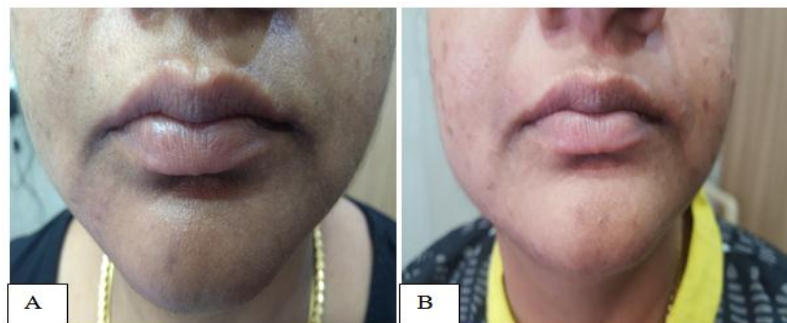

Fig. 2A: Upper lip at first visit; Fig. 2B: Upper lip at 6th month with marked hair reduction

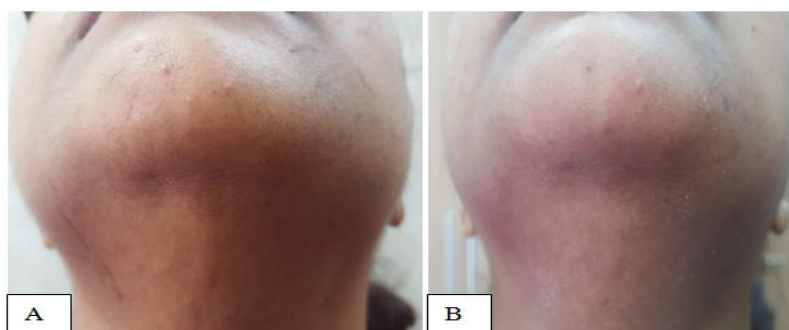


Fig. 3 A: Chin at first visit; Fig. 3 B: Chin at 6th month with marked reduction in hair density

Discussion

About 5-10% of all women of child bearing age and one-third of all post- menopausal women display some degree of hirsutism. Increased hair growth (unwanted hair growth) has strong negative psychological effect on the well being of the women.⁵ For this reason various methods of hair removal have been practiced. Now with the introduction of lasers for hair removal, there have been remarkable advances in this technology with different types of lasers in the market.⁶

Every laser system has some advantages and disadvantages regarding reduction of hairs, side effects, compliance etc. In past few years long-pulsed Nd:YAG laser, 1064 nm wavelength, has emerged as an effective hair removal system with lesser side effects.⁷ This study evaluates the efficacy and safety profile of Nd:YAG laser in the treatment of hirsutism.

Most of the patients in our study group belonged to the age group of 18-25 years. Similar age incidence was observed by Neerja Puri⁸ in their study of thirty patients with hirsutism, where maximum (50%) patients were between 21 to 30 years of age.

In our study 18 patients (45%) had combined involvement of lip, chin and body hair, followed by involvement of both lip and chin in 14 patients (35%). Similarly, in a study of 100 patients by Tahir Kamal,⁹ majority (90%) of patients had treatment done on face (chin, upper lips and sides) and 10% of patients had laser done on their neck.

In our study, 24 patients (60%) had family history of hirsutism. Karn and KC et al¹⁰ in their study of 60 patients noted that, 37% had positive family history of hirsutism. They also noticed abnormal TSH in 5 (3 hypothyroid and 2 hyperthyroidism) patients whereas in our study thyroid dysfunction was noted in 1 patient and PCOD was seen in 12 patients.

In our study, efficacy ie) percentage of hair reduction was graded according to a 4-point scale from excellent to poor. Excellent: >75% reduction; good: 50-75% reduction; fair: 25-50% reduction and poor: <25% reduction in hair density. Similar grading was used by Neerja Puri⁸ and Shrimal et al.¹¹ In our study, at the end of 4 weeks, good hair reduction (50-75%) was noted in 28 patients (70%). Similar hair reduction was obtained in the study by Noor¹² where after one month a mean hair reduction of 68 to 75% was obtained.

At the end of 8 weeks in our study, excellent hair reduction (>75%) was noted in 2 patients (5%) and good hair reduction was seen in 26 patients (65%). At 12 weeks excellent hair reduction was noted in 10 patients (25%) and good hair reduction in 18 patients (45%). At 6th month, after four monthly laser sessions excellent hair reduction was noted in 12 patients (30%) and good hair reduction seen in 16 patients (40%). Similar incidence was noted in a study by Shrimal and Sardar,¹¹ where with monthly session of long-pulsed Nd:YAG laser, patients showed an average hair reduction of 84.67% after four sessions.

In a study conducted by Tanzi and Alster,¹³ a mean hair reduction of 41%–46% on the face were noted after 6 months of a series of three long-pulsed Nd:YAG laser treatments. Noor and Paracaha¹² noted in their study

that at 6 months after a series of four long pulsed Nd:YAG laser treatments, a mean hair reduction of 65% was observed on the face. In majority of patients the response to treatment was good (65%) and excellent response was seen in 6% of patients. Neerja puri⁸ in their study noted that after four sessions of treatment, hair reduction was 62% with NdYAG laser.

In our study at the end of 6 months, equal response was noted in both lip and chin area, i.e) 11 patients (29%) with lip involvement had excellent hair reduction and similarly 10 patients (29%) with chin involvement also had excellent hair reduction. Noor¹² stated in their study that at the end of six months of four monthly laser sessions there was hair reduction of 65% on the face, 68% on the upper lip and 78% on the chin.

In our study, side effects noted were post procedure erythema and perifollicular edema, seen in 50% of patients. Rachna and Snehal¹⁴ et al noted mild to moderate pain in 100% of the treatment sites, short-term erythema in 90%, perifollicular edema in 80% and blistering in 0.8% of the patients. Noor and Paracaha,¹² in their study noted that, 95% patients showed erythema, 89% patients had perifollicular oedema and in 2% patients hyper-pigmentation was seen with long-pulsed laser for hair removal.

Kamal et al⁹ showed long-pulsed Nd:YAG laser and IPL-755 both are equally effective for hirsutism treatment, but Shrimal and Sardar¹¹ showed that the response to long-pulsed Nd:YAG laser is far better than IPL-755 as there was excellent response (>75% reduction in hair) after six sessions with NdYAG laser (Group A) in fourteen (93.33%) out of fifteen patients, whereas in patients with IPL(Group B), it was seen only in three (16.66%) out of eighteen patients. In Group A, erythema was seen in 26.67%, perifollicular edema and hyperpigmentation in 13.33% each. In Group B, erythema was seen in 50% patients, perifollicular edema in 16.67% and hyperpigmentation in 38.89% patients. Thus they concluded that Long-pulsed Nd:YAG Laser (1064 nm) is better than IPL-755 nm in terms of safety and effectiveness in the management of idiopathic facial hirsutism.

The long pulsed Nd:YAG is the safest laser for hair removal in darker skin types. Two factors contribute to the safety of the long pulsed Nd:YAG in darker skin types. First, the wavelength of the Nd:YAG (1064 nm) is at the end of the absorption spectrum of melanin. This wavelength is sufficient to achieve significant thermal injury in dark coarse hairs while sparing epidermal pigment.^{5,8,15,16} Secondly, the adjustable pulse width of long pulsed Nd:YAG lasers allows the laser energy to be delivered over a longer period of time allowing for the heat to dissipate and sufficient epidermal cooling to occur.^{6,13} The long-pulsed Nd:YAG lasers are receiving the most attention at this time, and numerous systems are available using this long wavelength of light. At this wavelength of light, melanin absorption is reduced, which require higher

fluences (power) to damage the hair effectively.¹⁷ Epidermal cooling devices incorporated into these devices ensure a reduction in the potential for epidermal injury and allow them to be successfully used in patients with dark skin (up to skin type VI).

Toosi et al¹⁸ performed a clinical trial on 232 persons to study the efficacy and side effect for three modalities (diode laser: 810 nm), (IPL: cut-off filter of 650 nm wavelength), and (alexandrite: 755 nm) in removal of unwanted hair. The comparison of the treatment results after 6 months did not show any significant statistical difference between alexandrite, IPL, and diode, although hair reduction was observed to be higher with the last.

Neerja Puri⁸ in their study noted that, the percentage of hair reduction after eight sessions of treatment was maximum (92%) in the diode laser group, followed by 90% hair reduction in the Nd:YAG group and 70% in the IPL group.

The two wavelengths which can safely be used for laser hair reduction on darker skin types are the diode (810 nm) and Nd:YAG (1064 nm). In terms of efficacy, the shorter wavelength (diode) laser is generally regarded as more effective because of melanin's higher absorption value which decreases with increasing wavelength.^{19,20} However, the longer wavelength Nd:YAG laser is considered ideal for treating patients with darker skin, due to reduced scatter and deeper penetration of the laser light. Also, shorter pulse durations can be more safely used with the Nd:YAG laser than with the diode. This is an additional advantage when dealing with finer hair with shorter thermal relaxation time (TRT).

Conclusion

The results of this study support safe and effective use of four consecutive laser sessions with long-pulsed 1064 nm Nd: YAG laser for facial hirsutism in Indian patients with darker skin photo types IV and V with minimal side effects. The effectiveness of was directly dependent upon the number of sessions.

References

1. D. Lynn Loriaux, An approach to the patient with hirsutism. *J Clin Endocrinol Metab*, September 2012;97:2959-2961.
2. Liew SH. Unwanted body hair and its removal: A review. *Dermatol Surg*. 1999;25:431-9.
3. Ibrahimi OA, Avram MM, Hanke CW, Kilmer SL, Anderson RR. Laser hair removal. *Dermatol Ther*. 2011;24:94-107.
4. Galadari I. Comparative evaluation of different hair removal lasers in skin types IV, V, and VI. *Int J Dermatol*. 2003;42:68-70.
5. Levy J-L, Trelles MA, de Ramecourt A. Epilation with a long-pulse 1064 nm Nd:YAG laser in facial hirsutism. *J Cosmetic Laser Ther* 2001;3:175-9.
6. Lorenz S, Brunner S, Landthaler M, Hohenleuter U. Hair removal with the long-pulsed Nd:YAG laser. A prospective study with one year follow up. *Lasers Surg Med* 2002;30:127-34.

7. Littler CM. Hair removal using an Nd:YAG laser system. *Dermatol Clin* 1999;17:401-30.
8. Puri N. Comparative study of diode laser versus neodymium-yttrium aluminum: garnet laser versus intense pulsed light for the treatment of hirsutism. *J Cutan Aesthet Surg* 2015;8:97-101.
9. Kamal T. Long-pulsed Nd: Yag laser and intense pulse light therapy for idiopathic facial hirsutism. A comparative study. *J Pak Assoc Dermatol* 2006;16:205-9.
10. Karn D, KC S. Hormonal Profile and Efficacy of Long Pulse Nd-YAG Laser in Treatment of Hirsutism. *J Nepal Health Res Counc* 2014 Jan;12(26):59-62.
11. Shrimal A, Sardar S, Long –pulsed Nd:YAG laser and intense pulse light-755nm for idiopathic facial hirsutism: A comparative study. *J Cutan Aesthet Surg* 2017;10:40-4.
12. Noor SM, Paracaha MM. Effectiveness of long pulsed Nd:Yag laser in hair removal. *JPMI* 2010;24:198-201.
13. Tanzi EL, Alster TS. Long-pulsed 1064-nm Nd: YAG laser-assisted hair removal in all skin types. *Dermatol Surg* 2004;30:13-7.
14. Rachna Mittal, Snehal Sriram, Evaluation of long-pulsed 1064 nm Nd:YAG laser –assisted hair removal vs Multiple treatment sessions and different hair types in Indian patients. *J Cutan Aesthet Surg*. 2008 jul-Dec;1(2):75-79.
15. Goldberg DJ, Silapunt S. Hair removal using a long-pulsed Nd:YAG laser: Comparison at fluences of 50, 80, and 100 J/cm. *Dermatol Surg* 2001;23:434-6.
16. Bencini PL, Luci A, Galimberti M, Ferranti G. Long-term epilation with long pulsed neodymium: YAG laser. *Dermatol Surg* 1999;25:175-8.
17. Mittal R, Sriram S, Sandhu K. Evaluation of long-pulsed 1064 nm Nd:YAG laser-assisted hair removal vs multiple treatment sessions and different hair types in Indian patients. *J Cutan Aesthet Surg* 2008;1:75-9.
18. Toosi, P., Sadighha, A., Sharifian, A. and Razavi, G.M. (2006) A Comparison Study of the Efficacy and Side Effects of Different Light Sources in Hair Removal. *Lasers in Medical Science*, 21, 1-4.
19. Hamilton MM, Dayan SH, Caniol PJ. Laser hair removal update. *Facial Plast Surg* 2001;17:219-22.
20. Tanzi EL, Lupton JR, Alster TS. Lasers in dermatology: Four decades of progress. *J Am Acad Dermatol* 2003;49:1-34.