



Original Research Article

Comparison of the diagnostic efficacy of Tzanck smear with histopathology and direct immunofluorescence in immunobullous disorders

S Aneesh¹, BN Raghavendra^{1,*}, Krishnan Aaryambika¹, Anjan Kumar Patra¹,
KD Bijina¹, Sandhaya¹

¹Dermatology, MVJ Medical College and Research Hospital, Hoskote, Karnataka, India



ARTICLE INFO

Article history:

Received 26-07-2019

Accepted 06-08-2019

Available online 14-09-2019

Keywords:

Direct immunofluorescence

Histopathology

Immunobullous disorders

Tzanck smear.

ABSTRACT

Introduction: The immunobullous disorders have severe impact on the patients and their family and have severe economic and health related consequences associated with pain, agony and loss of manpower. Tzanck smear being a bed side test can aid in establishing the clinical diagnosis with ease and rapidity and can serve as an adjunct to routine histological study. This study was undertaken to assess the utility of Tzanck test for early diagnosis of various immunobullous disorders and correlate the findings with histopathology and direct immunofluorescence.

Objectives: 1.To study Tzanck smear, histopathology, and immunofluorescence patterns in immunobullous disorders. 2.To evaluate diagnostic efficacy and sensitivity of Tzanck smear findings in comparison to histopathology and direct immunofluorescence in clinically suspected cases of immunobullous disorders.

Materials and Methods: A total of 38 cases clinically diagnosed immunobullous disorders were appraised during the study. The patients were subjected to Tzanck smear, skin biopsy for histopathology and direct immunofluorescence. The specimen was sent in 10% buffered formalin and normal saline for routine histological analysis and DIF respectively to the department of Pathology. The resulting data was tabulated and statistically analysed for comparison using sensitivity test.

Conclusion: Tzanck smear served as a simple, rapid and non invasive bedside diagnostic tool, which was cost effective and yielded quick results. It can be concluded that in pemphigus group of disorders, Tzanck smear is 100% sensitive, can yield quick results and can serve as first line of investigation rather than histopathology and DIF which is expensive and takes time for reporting.

Results: Pemphigus vulgaris was the most common immunobullous disease seen in this study, followed by bullous pemphigoid. Tzanck smear served as a rapid diagnostic tool and showed 100% sensitivity in all the pemphigus group of disorders which was compared with histopathological findings, which also showed 100% sensitivity whereas DIF was positive in 93.54% of cases.

© 2019 Published by Innovative Publication.

1. Introduction

The immunobullous disorders are a group of autoimmune diseases in which components of the epidermis and basement membrane zone are the focus of attack, resulting in the formation of cutaneous and mucosal blisters. The target antigens are components of desmosomes or the functional unit of the basement membrane zone known as the adhesion complex.¹ Early diagnosis and treatment of

these severe and potentially life-threatening disorders is essential in preventing the consequences. Tzanck smear is a simple, economical and rapid bed side technique which can be used in early diagnosis of immunobullous disorders, whereas histopathology and direct immunofluorescence, though specific, are time consuming and expensive.² This study was undertaken to assess the utility of Tzanck test in early diagnosis of various immunobullous disorders and correlate the findings with histopathology and direct immunofluorescence.

* Corresponding author.

E-mail address: raghavderm@gmail.com (B. N. Raghavendra).

2. Material and Method

In this prospective, observational, hospital based study conducted in a tertiary care hospital, Thirty eight patients presenting with immunobullous disorders attending the outpatient department of dermatology were enrolled after obtaining a written consent. The study was conducted between September 2016 and June 2018 after approval from institutional ethical committee. The objective was to study Tzanck smear, histopathology, and immunofluorescence patterns in immunobullous disorders and to evaluate the diagnostic efficacy and sensitivity of Tzanck smear findings in comparison to histopathology and direct immunofluorescence in clinically suspected cases of immunobullous disorders.

A detailed clinical history was taken including age, sex, occupation, site, and duration of symptoms. The case

s were subjected to Tzanck smear, biopsy for histopathology and direct immunofluorescence. Tzanck smear was taken from all cases, stained with Giemsa stain for cytological examination. Two skin biopsies were taken from each case and specimen was sent to laboratory in 10% formalin and phosphate buffer saline for routine histopathological examination and DIF respectively. The resulting data was tabulated and statistically analysed for comparison using sensitivity test.

3. Results

A total of 38 cases of immunobullous disorders, with 17 females (44.73%) and 21 males (55.26%) were included in the study (Table 1). The age ranged between 17 and 90 years with mean value of 44.47 years. In this study, the predominant number of cases were in the age group between 30-60 years (Table 2). In the present study, majority of the cases were pemphigus vulgaris 31 cases (81.57%) followed by bullous pemphigoid (13.15%), and dermatitis herpetiformis 2 cases (5.26%) (Table 3).

In pemphigus vulgaris group, Nikolsky sign was positive in 77.41% and Bulla spread sign was positive in 51.61% of the cases. Tzanck smear was positive for acantholytic cells in all the cases of pemphigus vulgaris (100%) with lymphocytes being the predominant infiltrate present in 77.41% (Figure 1). In histopathology, suprabasal split was seen in all cases (100%) (Figure 2) and acantholytic cells were seen 90.32% of the cases. IgG and C3 deposits were seen on DIF in 93.54% of cases (Table 4).

In all the cases of bullous pemphigoid, acantholytic cells were absent and eosinophils were found to be the predominant infiltrates in Tzanck smear. In histopathology, subepidermal split (Figure 3) and DIF showed linear deposits of IgG and C3 in all the cases. Acantholytic cells were conspicuously absent in case of dermatitis herpetiformis with presence of predominant neutrophilic infiltration in Tzanck smear. A subepidermal split was observed

in all cases and DIF showed linear IgA and C3 deposits (Table 6) (Figure 4).

Table 1: Sex incidence

Sex	Number of cases	Percentage
Male	21	55.2
Female	17	44.73
Total	38	100

Table 2: Age distribution

Age in years	Number of cases	Percentage
<30	5	13.15
30-60	25	65.78
>60	8	21.05
Total	38	100

Table 3: Clinical Diagnosis

Clinical Diagnosis	Number of cases	Percentage
Pemphigus vulgaris	31	81.57
Bullous pemphigoid	5	13.15
Dermatitis herpetiformis	2	5.26
Total	38	100

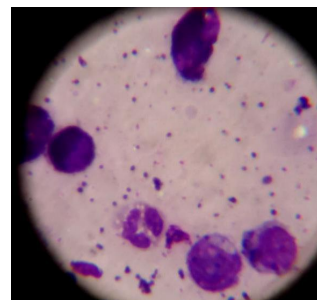


Fig. 1: Tzanck smear showing acantholytic cells, and lymphocytes

4. Discussion

The maximum number of patients in this study were in the age group of 30 to 60 years (65.78%). Out of 31 cases of pemphigus vulgaris, maximum number of patients were in age group of 30 to 60 years (77.41%), where as in the study done by Handa et al³, 57.6% of pemphigus vulgaris patients were in the age group of 11 to 15 years.

In this study, 44.73% of the patients were females and 55.26% were males with a male to female ratio of 1.23:1 which was in accordance with the study by Leena et al and Arya et al.^{4,5} Out of 31 cases of pemphigus vulgaris, 17(54.83%) were male, 14(45.16%) were female with male to female ratio of 1.21:1. This was in accordance with

Table 4: Comparison of Tzanck smear, histopathology and DIF in pemphigus vulgaris

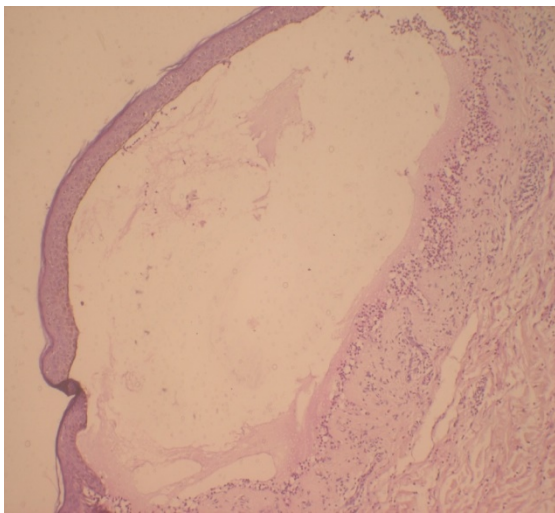
Pemphigus vulgaris	Number of cases with positive findings	Total cases	Percentage
Tzanck smear (Acantholytic cells)	31	31	100
Histopathology (Acantholytic cells)	31	31	100
Histopathology (Suprabasal split)	28	31	90.32
DIF (IgG and C3)	29	31	93.54

Table 5: Comparison of Tzanck smear, histopathology and DIF in Bullous pemphigoid

Pemphigus vulgaris	Number of cases with positive findings	Total cases	Percentage
Histopathology (Acantholytic cells)	0	5	0
Histopathology (Subepidermal split)	5	5	100
DIF (IgG and C3)	5	5	100

Table 6: Comparison of Tzanck smear, Histopathology and DIF in Dermatitis herpetiformis

Pemphigus vulgaris	Number of cases with positive findings	Total cases	Percentage
Histopathology (Acantholytic cells)	0	2	0
Histopathology (Subepidermal split)	2	2	100
DIF (IgA and C3)	2	2	100

**Fig. 2:** Photo micrograph of H & E stain, low power view, suprabasal bulla in pemphigus vulgaris

various studies which found the ratios ranging from 1:1.04 to 1: 1.6^{6–8}

In this study, Tzanck smear showed acantholytic cells in 81.57% (31/38) of all the immunobullous disorders. Acantholytic cells were present in all cases of pemphigus vulgaris 100% (31/31 cases) which was similar to a study by Leena et al⁹ and were negative in all the cases of bullous pemphigoid and dermatitis herpetiformis. Deepti et al¹⁰ in

her cohort found neutrophils in 58.8% cases of pemphigus vulgaris, with absent lymphocytes in pemphigus bullous pemphigoid and dermatitis herpetiformis. A predominant infiltrate of neutrophils was observed in 100% cases of dermatitis herpetiformis, and eosinophils were found in 76.4% cases of bullous pemphigoid. The present cohort showed predominant lymphocytic infiltration in 77.41% cases of pemphigus, 80% of dermatitis herpetiformis and 50% cases of bullous pemphigoid. Neutrophilic infiltration was predominantly observed in cases of dermatitis herpetiformis (100%), 41.93% of pemphigus vulgaris and 80% of bullous pemphigoid. Eosinophilic infiltration was noted in all the cases of bullous pemphigoid, and in 50% cases of dermatitis herpetiformis. It was absent in all the cases of pemphigus vulgaris which was in accordance with study by Deepti et al.¹⁰

In this study, suprabasal split was seen in all cases of pemphigus vulgaris (100%) which was comparable with study by Arya et al (81.4%).⁵ The subepidermal split was seen in all cases of bullous pemphigoid and dermatitis herpetiformis (100%) which was in accordance with studies by Leena et al(100%)⁴ and Banu L et al(100%).¹¹ In 90.32% cases of pemphigus vulgaris acantholytic cells were noted, while it was completely absent in cases of bullous pemphigoid and dermatitis herpetiformis. A study by Deepti et al¹⁰ had similar findings.

The immune complex deposits of IgG and C3 were seen in 93.54% of pemphigus vulgaris and in 100% cases of bullous pemphigoid. All the cases of dermatitis

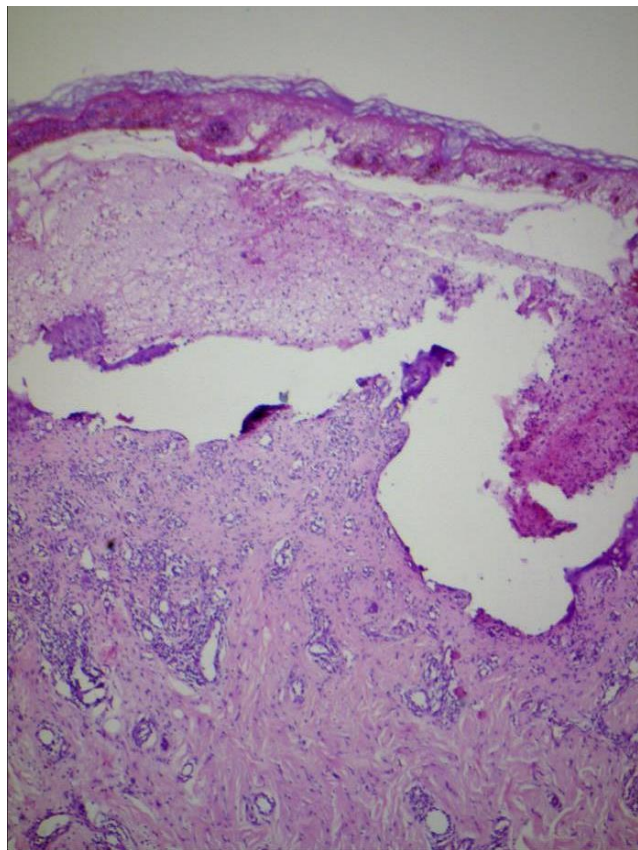


Fig. 3: Photo micrograph of H & E stain, low power view showing subepidermal bulla in bullous pemphigoid

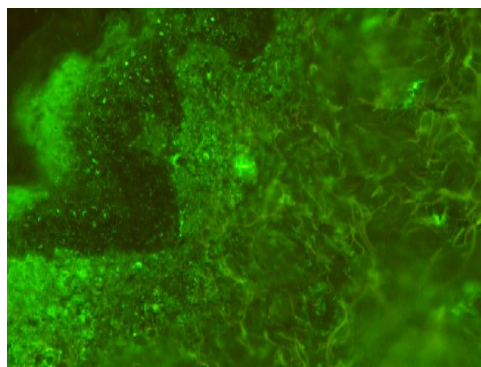


Fig. 4: DIF- showing linear immune complex deposits along dermal papillae

herpetiformis showed deposits of IgA and C3. The above findings were comparable with various studies. In a study by Deepti et al¹⁰, DIF was positive in 94.11% (16/17) cases of pemphigus, in a study by Chams-Davatchi C et al,¹² DIF was positive in 93.2% (389/417) cases of pemphigus vulgaris. Kaur JS et al¹³, noted DIF to be positive in 100% cases of pemphigus and Inchara K et al,¹⁴ reported DIF to be positive in 89.7%(26/29) cases of pemphigus vulgaris.

The studies by Deepti et al¹⁰ and Deepthi PK et al¹⁵ reported DIF to be positive in 100% and 87.5% cases of bullous pemphigoid respectively. Both Banu L et al¹¹ and Deepti et al¹⁰ in their study found positive DIF in all the cases of dermatitis herpetiformis.

The present study demonstrated fishnet pattern of immune complex deposits in 93.54% (29/31) cases of pemphigus vulgaris. Linear pattern of immune complex deposits were seen in all cases of bullous pemphigoid and dermatitis herpetiformis..

A positive correlation was noted between the presence of acantholytic cells in Tzanck smear and the diagnosis of pemphigus vulgaris, as these cells were identified in 100% (31/31) of patients within the pemphigus group of disorders. In 90.32% of cases who showed acantholytic cells in histopathology, we were able to make an early diagnosis of pemphigus vulgaris using Tzanck smear which showed acantholytic cells in 100% cases of pemphigus vulgaris.(100% sensitivity)

A definite diagnosis of immunobullous disorders solely based on the nature of inflammatory infiltrates in cytology could not be made because of the overlapping nature of infiltrates in these disorders especially bullous pemphigoid & dermatitis herpetiformis. Further, cytological evaluation based on cellular infiltrates alone might not be confirmatory.

The sensitivity of Tzanck smear was 100% in all cases of pemphigus vulgaris as compared to DIF which was 93.54%(29/31) Tzanck smear was negative for acantholytic cells in bullous pemphigoid and dermatitis herpetiformis, but showed predominance of eosinophils & neutrophils respectively. The diagnosis was confirmed through histopathology and DIF in these group of disorders..

Although histopathological findings based on level of split were positive in all cases of pemphigus vulgaris and DIF was positive in 93.54% of cases, Tzanck smear was found to be more efficacious as it showed 100% sensitivity. In addition it is a simple bedside technique, which is cost effective, yields quick results and is non invasive, where as biopsy is an invasive technique, requires a skilled personal, more expensive than Tzanck smear and takes time for reporting.

5. Conclusion

Tzanck smear served as a simple, rapid, bedside diagnostic tool which is cost effective, can yield quick results and is a non invasive technique. It showed 100% sensitivity

in all the cohort with pemphigus vulgaris. A definite diagnosis of immunobullous disorders solely based on the nature of inflammatory infiltrates in cytology could not be made because of the overlapping nature of infiltrates in these disorders especially in cases of bullous pemphigoid and dermatitis herpetiformis. It can be concluded that in pemphigus group of disorders, Tzanck smear is 100% sensitive and can probably serve as a first line of investigation rather than histopathology and DIF which is expensive and takes time to yield results.

6. Source of Funding

None.

7. Conflict of interest

None.

References

1. Kirtschig G, Wojnarowska F ;. 2012.
2. -. *Clin Exp Dermatol*. 1994;19:97–112.
3. Handa F, Agarwal RR, Garg RK. A clinical study of 85 cases of Pemphigus. *Indian J Dermatol Venereol*;
4. Leena JB, Chandrashekar M, Vijaya B, Sunila R, Manjunath GV. A clinicopathological study of immunobullous lesions of the skin. A 2 years study. *Adv Lab Med Int*. 2012;2(2):49–60.
5. Arya SR, Valand AG, Krishna K. A clinic-pathological study of 70 cases of pemphigus. *Indian J Dermatol Venereol Leprol*. 1999;65:168–171.
6. Vora D, Popat V, Bhanvadia V, Mehta DA, Bhetariya B, Kumar M. A study of 75 cases of pemphigus in Saurashtra region of India. *Iranian journal of dermatology*. 2010;13:42–46.
7. Patel PR, Dharmesh K, Chiplonkar SG. A clinico-pathological study of 22 cases of pemphigus. *National Journal Of Medical Research*. 2012;2:269–271.
8. Epidemiology of pemphigus in hamedan (west of Iran). A 10 year study (1994-2004). *Int J Pharm Biomed Res*. 2010;1(4):157–160.
9. Leena, Vijaya B, Manjunath GV, Sunila. A clinico-pathological study of 22 cases of pemphigus. *Journal of Clinical and Diagnostic Research*. 2010;(4):2446–2451.
10. Deepthi SP, Sulakshana MS, Manjunatha YA, Jayaprakash HT. A histomorphological study of bullous lesions of skin with special reference to immunofluorescence. *Int J of current research academic review*;2015(3):29–51.
11. Banu L, Gulen GN, Selen S, Hulya E ; 2012..
12. Chams-Davatchi C, Valikhani M, Daneshpazhooh M, Esmaili N, Balighi K, Hallaji Z. Pemphigus: analysis of 1209 cases. *Int J Dermatol*. 2005;44:470–476.
13. Kaur JS, Kanwar AJ, Kaur S, Sehgal S ; 1992..
14. Inchara YK, Rajalakshmi T. Direct immunofluorescence in cutaneous vesiculobullous lesions. *Indian J Pathol Microbiol*. 2007;50(4):730–732.
15. Deepthi PK, Santosh CS, Suguna B, Gopal M, A. Direct immunofluorescence study in autoimmune bullous disorders of skin. *IJBAR*. 2013;04(09):611–618.

Author biography

S Aneesh Associate Professor

BN Raghavendra Associate Professor

Krishnan Aaryambika Resident

Anjan Kumar Patra Professor

KD Bijina Assistant Professor

Sandhaya Senior Resident

Cite this article: Aneesh S, Raghavendra BN, Aaryambika K, Patra AK, Bijina KD, S. Comparison of the diagnostic efficacy of Tzanck smear with histopathology and direct immunofluorescence in immunobullous disorders. *Indian J Clin Exp Dermatol* 2019;5(3):211-215.