



Case Report

Aureobasidium opportunistic fungal Infection-Oddity of species invariably heaves the clinicians attention

U.V.S Akhila Reddy^{1,*}, M Pavan Kumar¹, A Vijaya Mohan Rao¹

¹Dept. of Dermatology Venereology Leprosy, Narayana Medical College and Hospital, Nellore, Andhra Pradesh, India

ARTICLE INFO

Article history:

Received 08-07-2019

Accepted 03-08-2019

Available online 14-09-2019

Keywords:

Renal transplant

Opportunistic fungal infections

Aureobasidium pullulans

ABSTRACT

Post transplant patients are more vulnerable to the opportunistic fungal infections secondary to the long-standing treatment on immunosuppressive therapy. A conscientious look in the post renal transplant patients in view of any opportunistic fungal infections is crucial. *Aureobasidium pullulans* is an agent responsible for various opportunistic fungal pathologies leading to nodules with secondary ulceration on skin and systemic infection leading to abscess formation in viscera.

© 2019 Published by Innovative Publication.

1. Introduction

The incidence of opportunistic fungal infections principally in immunocompromised patients has increased in recent years accounting to 1.5% of all infections in renal transplant patients. *Aureobasidium* species are the surging cause for deep fungal infections. It is a ubiquitous dematiaceous fungus. Clinically significant species are *Aureobasidium pullulans*, *Aureobasidium proteae*, *Aureobasidium mansoni* Common organs to be involved are lungs causing pneumonia and pulmonary embolism, brain leading to brain abscess, gastro intestinal tract causing peritonitis.^{1,2}

Herein we report a case of subcutaneous deep fungal infection caused by an unusual group of fungus, *Aureobasidium* species in a renal transplant patient.

2. Case Report

A 36 year-old male referred from nephrology ward, presented with asymptomatic nodules with crusting and ulceration over both knee regions and palmar aspect of right hand. History of present illness started in January, 2018 as asymptomatic papule over left knee region,

gradually increased in size and number. Figures 1 and 2. No history of other systemic complaints. Past history of kidney transplantation done for the end stage renal disease secondary to diabetic nephropathy in April, 2017 and he was on methyl prednisolone 500mg on the day of operation followed by 50mg of methyl prednisolone for a period of 1 month followed by tapering doses of prednisolone at a dose of 0.5mg/kg/day for 2 months followed by maintenance on tacrolimus 0.1mg/kg/day and mycophenolate mofetil 500mg bid. Differential diagnosis considered were carbuncle and deep fungal infection.

2.1. Investigations

Renal function tests were in abnormal parameters, viral screening for HIV, HbsAg, HCV were non-reactive. Other biochemical and haematological tests were normal. Excision biopsy from the ulcerated lesion over right knee region Figure 3 was sent for histopathology Figure 4 and culture Figure 5. Histopathology showed fragments of epidermis with focal ulceration, lymphocytic infiltration in dermis, multiple microabscesses and multinucleate giant cell granulomas, few spores and hyphae of fungal elements and organism isolated in culture of excised skin bit belongs to *Aureobasidium* species. Pus for culture showed no growth

* Corresponding author.

E-mail address: 142akhilauvs@gmail.com (U. V. S. A. Reddy).

after 48 hours of aerobic incubation

2.2. Treatment

Patient was started on oral voriconazole 200mg twice daily and treated for 3 months and lesions resolved.

3. Discussion

Immunosuppression is partial or complete suppression of immune system which can be congenital or acquired. Most common causes are uncontrolled diabetes mellitus, HIV/AIDS, post transplant patients, malignancies (leukemias and lymphomas). Post transplant patients owe a higher risk of opportunistic fungal infections attributed to prolonged treatment on immunosuppressive therapy as to prevent the chances of organ rejection.

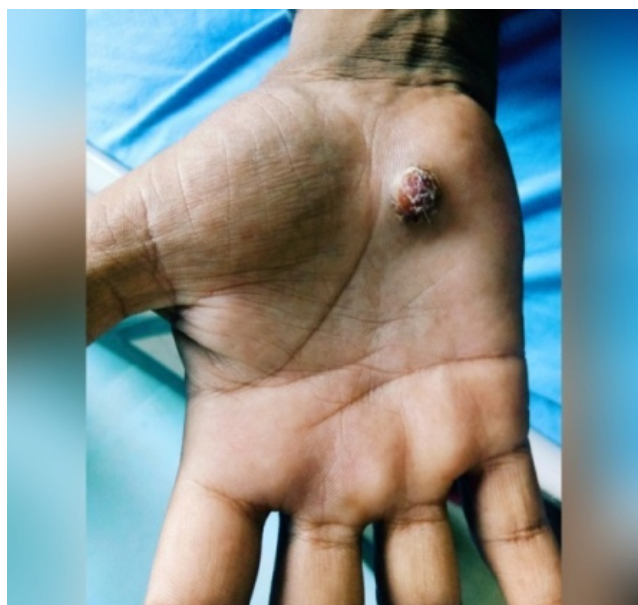


Fig. 1: Lesion over palmar aspect of right hand

Opportunistic fungal infections are the major cause of morbidity and mortality in post transplant patients. One among the emerging cause being *Aureobasidium* species.

kingdom : Fungi

Phylum : Ascomycota

Class : Euascomycetes

Order : Dothideales

Family : Dothioraceae

Genus : *Aureobasidium*.

These are saprophytic dematiaceous fungus with confounding feature of melanin pigment in their cell wall which plays an imperative role in the pathogenesis by protecting against reactive oxygen species and providing heat resistance.^{2,3} Quick growth is seen at 25 ° C as yellowish light brown groups of conidia.

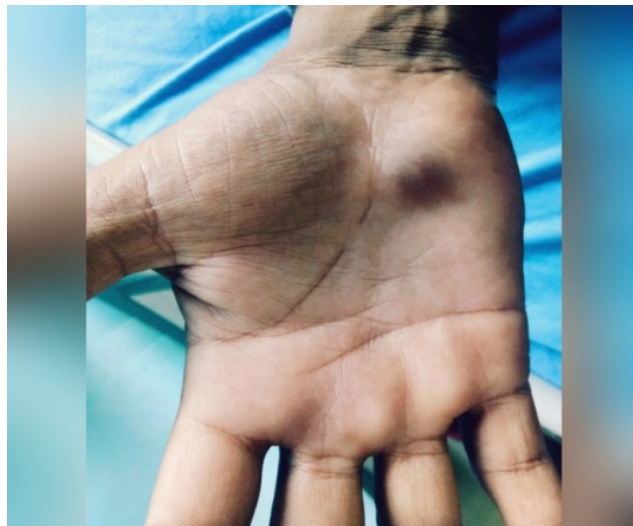

Fig. 2: Lesion after 3 months of voriconazole therapy

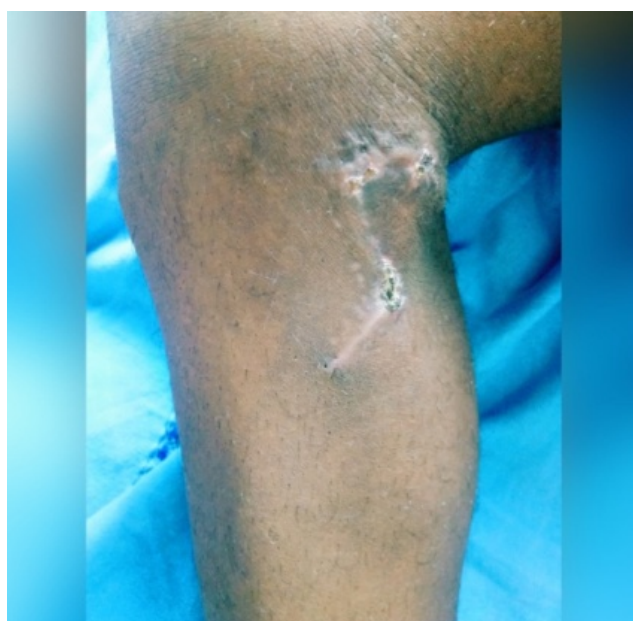

Fig. 3: Excision biopsy done over right knee region

Aureobasidium pullulans is the most common etiological agent of human disease. Most common route of infection is through traumatic inoculation. Most common presentation is ulcerative nodules with disseminated systemic infection. Diagnosis is confirmed by skin biopsy and culture.

Treatment options are oral voriconazole 200mg BD or oral itraconazole 3-5 mg/ kg/day. Systemic involvement is better treated with intravenous voriconazole 6mg / kg 12th hourly or intravenous liposomal amphotericin B 3mg / kg 6th hourly.

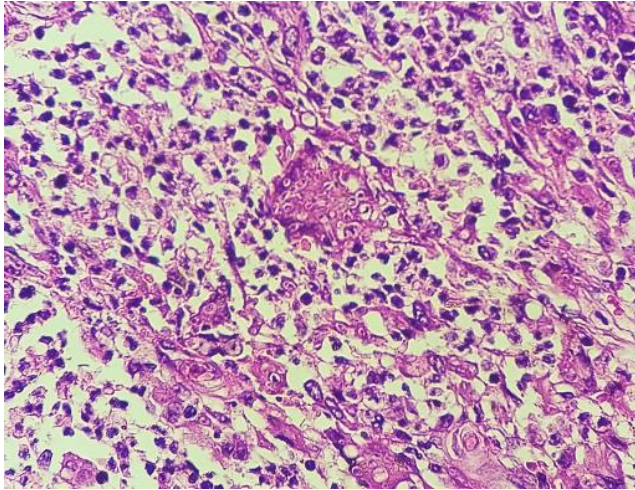


Fig. 4: Microabscess with central multinucleate giant cell filled with fungal spores.



Fig. 5: Fungal growth seen after 3 weeks of culture.

4. Conclusion

The emerging fungal infections by *Aureobasidium* species and paucity of data regarding the management made it essential for a high degree of clinical suspicion and prompt diagnosis to yield a better prognosis.

5. Source of Funding

None.

6. Conflicts of Interest

None.

References

1. Salkin IF, Ja M, K. Opportunistic Infection Of Spleen Caused By *Aureobasidium Pullulans*. *J Clin Microbiol*. 1986;(5):828–859.
2. Mise N, Onoy, Kurtia N. *Aureobasidium Pullulans* Peritonitis. A Case Report And Review Of The Literature ; 2008,.
3. Bolignano G, Criseo G. Disseminated Nosocomial Fungal Infection By *Aureobasidium Pullulans* Var . *Melanigenum* A Case Report. *J Clin Microbiol*. 2003;41:4483–4485.

Author biography

U.V.S Akhila Reddy Final Year Resident

M Pavan Kumar Senior Resident

A Vijaya Mohan Rao Professor and HOD

Cite this article: Reddy UVSA, Kumar MP, Rao AVM. *Aureobasidium* opportunistic fungal Infection-Oddity of species invariably heaves the clinicians attention. *Indian J Clin Exp Dermatol* 2019;5(3):255-257.