



Original Research Article

A quasi interventional study on the efficacy of long pulsed Nd:YAG laser (LPND) in the treatment of periorbital wrinkles in a tertiary care hospital

Madhuri B¹, Spandana P Hegde^{1,*}, Manjunath Shenoy M¹, Vishal B¹, Malcolm Pinto¹

¹Dept. of Dermatology, Yenepoya Medical College, Yenepoya University, Mangalore, Karnataka, India



ARTICLE INFO

Article history:

Received 24-02-2020

Accepted 02-03-2020

Available online 21-04-2020

Keywords:

Long pulsed Nd: YAG laser

Non ablative

Periorbital wrinkles

Skin resurfacing

ABSTRACT

Introduction: Wrinkles or rhytids are a part of the natural ageing process of the human body. Long pulsed Nd: YAG laser (LPND) promotes dermal collagen remodelling without damaging the superficial layers and hence reduce periorbital wrinkles.

Materials and Methods: Patients seeking treatment for periorbital wrinkles, and willing to participate in the study were included. Wrinkles were graded on the basis of wrinkle severity score (WSS) at baseline and one month after 4 monthly sessions of treatment. The 1064nm LPND was employed with settings of: spot size - 10mm, on time - 40 to 50 ms, fluence - 30 to 50 J/cm² and frequency - 1 Hz. Three overlapping passes were done on both sides of the face. Outcome was measured by subjects, investigator and a blinded dermatologist. Appropriate statistical analysis was done.

Results: Twenty eight sites were treated in 14 subjects. Male to female ratio was 3:4. Their mean age was 45.86 ± 8.75. Mean WSS by investigator at baseline was 3.18 ± 1.188 and at the end of treatment was 1.89 ± 1.031 (p = 0.001). Mean WSS by the blinded dermatologist was 3.18 ± 1.188 at baseline and 2.43 ± 1.034 at end of the treatment (p = 0.001). The subject's degree of satisfaction was found to be 2.96 ± 1.036. There were no significant adverse events.

Conclusion: LPND for periorbital wrinkles is both patient and physician friendly, offering maximum results with minimal discomfort and downtime. This modality needs further exploration in the treatment of periorbital wrinkles in the Indian population.

© 2020 Published by Innovative Publication. This is an open access article under the CC BY-NC-ND license (<https://creativecommons.org/licenses/by/4.0/>)

1. Introduction

Wrinkles or rhytids are a part of the natural ageing process of the human body. As face is a site of aesthetic concern, patients look for a simple yet effective method to reduce wrinkling. Topical agents, chemical peels, injectables, surgeries and lasers have been used for the management of periorbital wrinkles with varying success. Ablative lasers have been used to improve the skin laxity and to reduce wrinkles. However, the adverse effects like epidermal denudation and thermal injury have posed a significant challenge and reduced the amount of patients opting for this modality. Non ablative lasers are safer and give almost similar results with lesser undesirable consequences.

The 1064-nm long-pulsed Neodymium: Yttrium Aluminium Garnet (Nd:YAG) laser has shown to enhance dermal collagen synthesis without damaging the epidermis.¹ Our study aimed to determine the efficacy of LPND in the treatment of periorbital wrinkles and to evaluate the adverse effects of this therapeutic modality.

2. Materials and Methods

After obtaining institutional ethical clearance, 20 subjects seeking treatment for periorbital wrinkles and willing to participate in the study were included. Only 14 subjects completed 4 sessions, hence results of 14 patients that included 28 sites were analysed. The study was performed at the dermatology outpatient department of a tertiary care hospital from January 2019 to August 2019. Hyperion

* Corresponding author.

E-mail address: hegdespandana@gmail.com (S. P. Hegde).

1064nm LPND by Laseroptek, which is FDA approved for the treatment of wrinkles and skin laxity, was employed. Settings were as follows: spot size of 10 mm, on time of 40-50 ms, fluence of 30-50 J/cm² and frequency of 1 Hz. A total of 4 sessions were done at monthly intervals. Protective eye-gear which protects the eye from 1064nm wavelength of light was used. Three overlapping passes of LPND over the periorbital wrinkles on both sides of the face were done with pre and post procedural cooling. Pre and post treatment photographs were taken. The final assessment was done one month after completion of treatment. Wrinkles were graded on the basis of wrinkle severity score (WSS) at baseline and at one month after completion of the treatment by investigator (Table 1). Outcome was also analysed according to the WSS by a blinded dermatologist with the aid of pre and post treatment photographs. Subjects were asked to grade their response based on degree of satisfaction on a scale of 0 to 5 (Table 2). Statistical analysis was done and descriptive statistics like mean, standard deviation were calculated. Inferential statistics like paired t test was used for quantitative data using SPSS (Statistical Package for Social Sciences) version 20. (IBM SPASS statistics [IBM corp. released 2011]).

3. Results

Fourteen patients with periorbital wrinkles over 28 sites were analysed. Male to female ratio was 3:4. Their mean age was 45.86 ± 8.75 years. (Table 3) Mean WSS as graded by investigator at baseline was 3.18 ± 1.188 and at the end of study was 1.89 ± 1.031 ($p = 0.001$). Mean WSS grading by the blinded dermatologist was 3.18 ± 1.188 at baseline and 2.43 ± 1.034 at end of the treatment ($p=0.001$) (Table 4). Mean of self assessment done by the subject based on degree of satisfaction was found to be 2.96 ± 1.036 . Two patients complained of slight pain during the procedure which subsided on post procedural cooling. No other adverse events were noticed throughout the treatment period. The pre (baseline) and post treatment (1 month after completion of treatment) photographs are shown in Figures 1, 2 and 3.

4. Discussion

LPND non ablative skin resurfacing promotes periorbital rejuvenation by provoking collagen synthesis in the dermis without damaging the superficial epidermis.² It does not change the inherent behaviour of the muscle (orbicularis oculi) nor does it influence gravitational forces. Ablative methods are associated with better results but comparatively have more downtime than non ablative methods, because of prolonged erythema, crusting, edema, scarring, pigmentation and possibility of secondary infections. All these limitations are overcome by the non ablative LPND whilst delivering almost comparable results for superficial

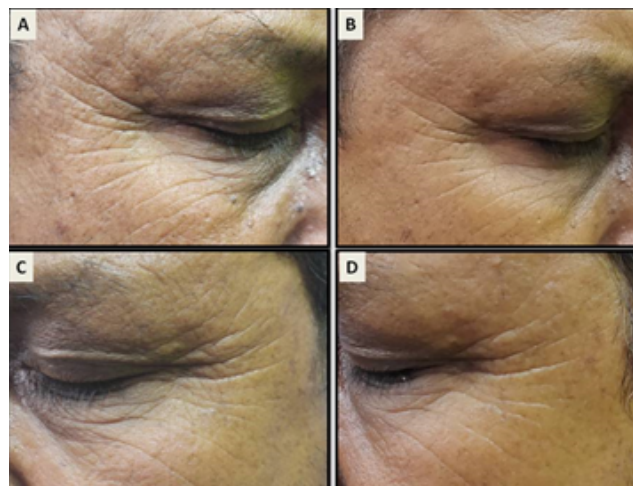


Fig. 1: a) Periorbital wrinkles (right side) at baseline; b) 1 month post treatment with LPND; c) Periorbital wrinkles (left side) at baseline; d) 1 month post treatment with LPND

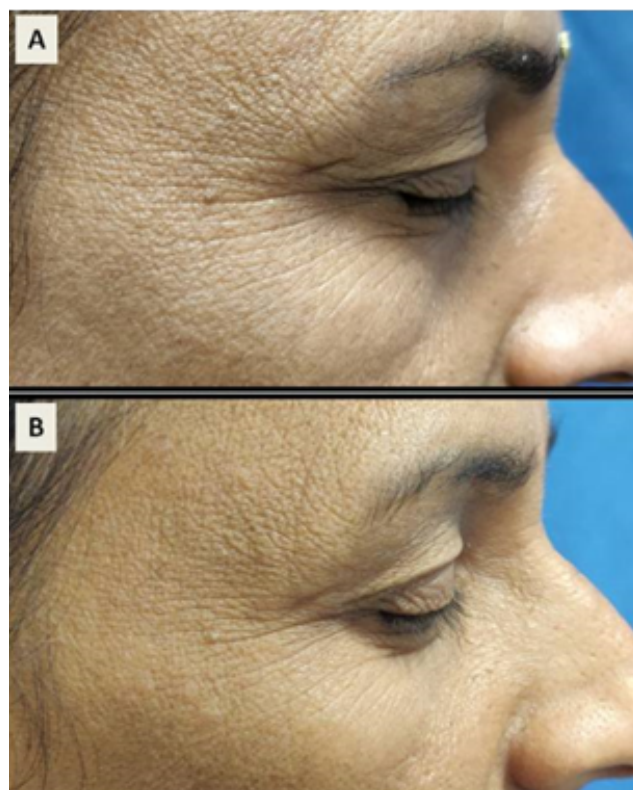


Fig. 2: a) Periorbital wrinkles (right side) at baseline; b) 1 month post treatment with LPND

Table 1: Wrinkle severity score (WSS)

| Grade | Criteria |
|-------|--|
| 0 | No evidence of fine lines/ wrinkles |
| 1 | A few short barely perceptible line/ wrinkles |
| 2 | A few shallow lines/ wrinkles that are discretely visible, no deep lines/ wrinkles |
| 3 | Shallow, easily visible lines/ wrinkles |
| 4 | Moderate number of fine lines/ wrinkles |
| 5 | Many deep lines |

Table 2: Degree of satisfaction (Likert scale)

| Grade | Criteria |
|-------|--------------------|
| 0 | Very dissatisfied |
| 1 | Dissatisfied |
| 2 | Neutral |
| 3 | Somewhat satisfied |
| 4 | Satisfied |
| 5 | Very satisfied |

Table 3: Demographic characteristics of the study subjects

| | |
|--|--------------------|
| Total number of subjects included | 20 |
| Total number of subjects who completed the study | 14 (28 sites) |
| Male: female ratio (n=14) | 3:4 |
| Mean age with S.D. | 45.86 ± 8.75 years |

S.D. – Standard deviation

Table 4: Comparison of baseline and final WSS of 14 patients (28 sites) who completed the study, by investigator and blinded dermatologist

| Wrinkle severity score (WSS) | Principal investigator | | Blinded dermatologist | |
|------------------------------|------------------------|--------------------|-----------------------|--------------------|
| | Baseline WSS (n = 28) | Final WSS (n = 28) | Baseline WSS (n = 28) | Final WSS (n = 28) |
| 0 | 0 | 2 | 0 | 0 |
| 1 | 2 | 10 | 0 | 6 |
| 2 | 7 | 5 | 6 | 9 |
| 3 | 7 | 11 | 8 | 8 |
| 4 | 8 | 0 | 8 | 5 |
| 5 | 4 | 0 | 6 | 0 |
| Mean with S.D. | 3.18 ± 1.188 | 1.89 ± 1.031 | 3.18 ± 1.188 | 2.43 ± 1.034 |
| p value | 0.001 | | 0.001 | |

S.D. – Standard deviation

wrinkles.¹

Our study included mostly middle aged men and women with Fitzpatrick type 4 skin. We had inadequate compliance with only 70% of the recruited subjects completing the scheduled treatment. Our results indicate a good improvement of 41% according to the investigator and 24% according to the blinded dermatologist. These results were obtained in 4 sessions indicating the results could further improve if more sessions were employed. Results were statistically highly significant, however mean degree of satisfaction according to the subjects was accounting to somewhat satisfactory. This is because the deep wrinkles are not targeted by this non ablative laser. Most patients did not experience any discomfort or other adverse events.

Many studies have evaluated the efficacy of LPND in perioral as well as periorbital wrinkling, alone or with combination of surgical methods.^{2–5} Dayan et al treated 34 patients for a minimum of 7 treatments, 1 to 4 weeks apart using a 10-mm hand piece LPND with the settings: Fluence: 22 J/cm², on time: 50-milliseconds and frequency: 2 pulses/ second. They evaluated the results based on the 9 point Fitzpatrick scoring system for wrinkles. Results were assessed by the patient and 3 masked physicians. Patient assigned and physician graded Fitzpatrick scores reduced significantly by 41% and 20% respectively after 6 treatments and continued to improve on further treatment. No significant adverse events were noted. This study differed from our study in treatment duration and the 9

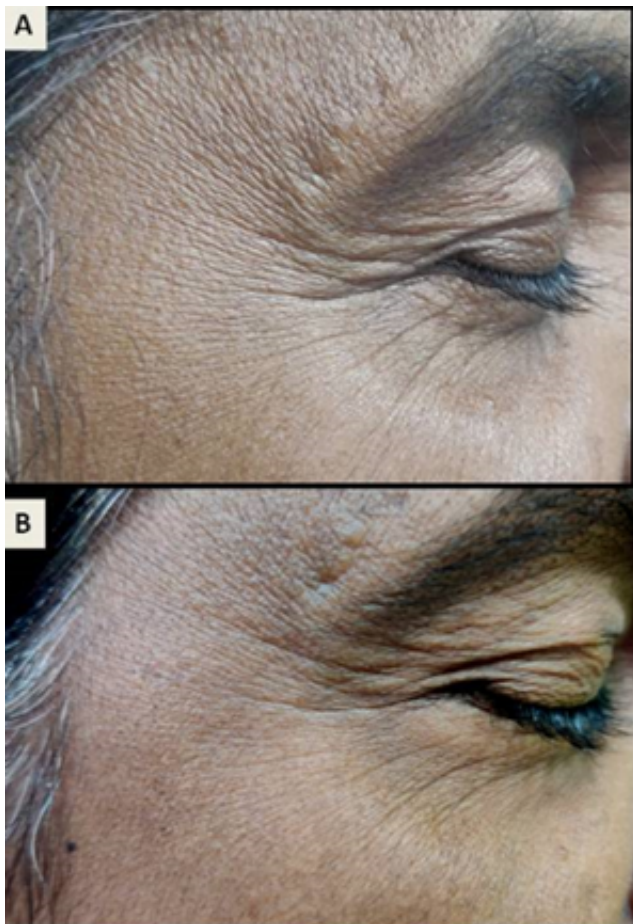


Fig. 3: a) Periorbital wrinkles (right side) at baseline; b) 1 month post treatment with LPND

point scoring system that they used to grade wrinkles which assesses wrinkling (1-3) as well as degree of elastoses (1-9).⁵

Chang et al conducted a split face study of 27 patients with periorbital wrinkles with LPND for 3 sittings at 2 week intervals. Treatment parameters were: fluence: 54.7-61.8 J/cm², on time: 56.5 microseconds and spot size: 5mm. They assessed the outcome based on pre and post treatment photographs, evaluation by 2 blinded dermatologists using Fitzpatrick Wrinkle Classification System and patients' degree of satisfaction. They used 6 point visual analog scale (VAS) at 8 weeks of follow up and 6 months after the last treatment session. The mean wrinkle score on treated site reduced significantly (34.9%) at 8 weeks follow up. Patients' degree of satisfaction showed that there was about 30-50% improvement, though it reduced further after 6 months of final treatment.² Though their parameters were comparable to ours, they gave multiple passes until erythema/ edema was achieved, which ensured better results. Also, a split face study is ideal to gauge the efficacy of LPND in periorbital wrinkles.

We are unable to compare our results with other studies because of the discrepancy in the skin type, equipments used, parameters, number of sessions, treatment intervals and the grading systems. Following non ablative skin resurfacing, the degree of heat transmission depends on the wavelength of the laser, fluence emitted, and the depth of the absorbing chromophore in the dermis.⁶ Higher fluence, multiple pass technique and more number of sittings are the ideal parameters to be used while treating periorbital wrinkles. We employed the current parameters to ensure minimal discomfort to the subjects.

Limitations of the study were small sample size, lack of control or comparator, shorter duration of therapy and follow-up period. Nevertheless, this appears to be the first Indian study on LPND in periorbital wrinkles according to the best of our knowledge.

5. Conclusion

Non ablative skin resurfacing is currently gaining importance in dermatological practice as it is easy to perform and patient friendly while giving good results with minimal discomfort. There is no downtime or no strict protocols. Improvements in skin quality, tone and elasticity can be gained without any invasive techniques. The results of the modality look promising whereas long term studies, especially in Indian population, are required to notice the sustainability of the procedure. This emerging option can be considered as an additional tool in the management of periorbital rejuvenation in Indian population.

6. Source of funding

None.

7. Conflict of interest

None.

References

1. Trelles MA, Álvarez X, Martín-Vázquez MJ, Trelles O, Velez M, et al. Assessment of the Efficacy of Nonablative Long-Pulsed 1064-nm Nd:YAG Laser Treatment of Wrinkles Compared at 2, 4, and 6 Months. *Fac Plast Surg*. 2005;21:145–153.
2. Chang SE, Choi M, Kim MS, Chung JY, Park YW, et al. Long-pulsed Nd:YAG laser on periorbital wrinkles in Asian patients: randomized split face study. *J Dermatol Treat*. 2014;25:283–289.
3. Goldberg DJ, Whitworth J. Laser Skin Resurfacing with the Q-switched Nd:YAG Laser. *Dermatol Surg*. 1997;23:903–907.
4. Roberts T, Yokoo K. Continuing Medical Education Examination—Facial Aesthetic Surgery In Pursuit of Optimal Periorbital Rejuvenation: Laser Resurfacing With or Without Blepharoplasty and Brow Lift. *Aesthet Surg J*. 1998;18(5):321–332.
5. Dayan SH, Vartanian AJ, Menaker G, Mobley SR, Dayan AN. Nonablative Laser Resurfacing Using the Long-Pulse (1064-nm) Nd:YAG Laser. *Arch Fac Plast Surg*. 2003;5(4):310–310.
6. Pozner JN, Goldberg DJ. Nonablative laser resurfacing: state of the art 2002. *Aesthet Surg J*. 2002;22:427–434.

Author biography

Malcolm Pinto Assistant Professor

Madhuri B Post Graduate

Spandana P Hegde Assistant Professor

Manjunath Shenoy M Professor and Head

Vishal B Professor

Cite this article: Madhuri B , Hegde SP, Shenoy M M, Vishal B , Pinto M. **A quasi interventional study on the efficacy of long pulsed Nd:YAG laser (LPND) in the treatment of periorbital wrinkles in a tertiary care hospital.** *IP Indian J Clin Exp Dermatol* 2020;6(1):45-49.