

# A Role of Estrogen in Etiopathogenesis of Melasma in Female Patients- A Prospective Observational Study in a Tertiary Care Hospital

Krishnendra Varma<sup>1,\*</sup>, Kiran Kumare<sup>2</sup>, Harsh Sharma<sup>3</sup>, Megha Sharma<sup>4</sup>

<sup>1</sup>Professor, <sup>2,4</sup>PG Student, <sup>3</sup>Assistant Professor, RD Gardi Medical College, Ujjain, Madhya Pradesh

**\*Corresponding Author:**

Email: krishnendra\_vermal7@yahoo.co.in

## ABSTRACT

**Background:** Melasma is a common patchy brown, tan or blue-gray facial skin discoloration usually seen in women in the reproductive years.

**Aim:** To study the role of estrogen in etiopathogenesis of melasma in female patients.

**Objectives:** To study the estrogen levels and its imbalance in female patients attending Dermatology OPD of C.R.G.H. within 1 year by correlating with the normal levels.

**Patients and Methods:** Sixty -six female patients suffering from melasma, between the ages of 15-45 years, were enrolled in the study. Patients were investigated for estrogen levels at any time of their menstrual cycle and estrogen values estimated according to follicular and luteal phase values.

**Results:** Amongst the sixty- six patients, there were only 18 (27.3%) patients who had normal values for estrogen while the remaining 48 patients (72.7%) had deranged values (mostly increased).

**Conclusion:** Estrogen plays an important role in causation of melasma.

**Key Words:** Melasma, estrogen, discolouration, reproductive years

## INTRODUCTION

The word Melasma is derived from Greek word melas (black) while chloasma is derived from the word chloazein (green) and since the pigmentation is brown-black melasma is the preferred term.<sup>[1]</sup>

Melasma is acquired hypermelanosis of sun-exposed areas. It presents as hyper pigmented macules, which can be confluent or punctate. The cheeks, upper lip, chin and forehead are the most common locations but it can occur on other sun-exposed locations. Melasma is common in constitutionally dark skin types, especially in people with light brown skins, especially in people of East and South East Asian and Hispanic origin who live in areas with intense solar ultraviolet radiation (UVR).<sup>[1]</sup> It is commoner in women than in men (9:1) and is rare before puberty, occurring most commonly in women of reproductive age.

The exact etiology of melasma is not known but several factors have been implicated. UVR (UVA and UVB) and visible light cause peroxidation of lipids in cellular membranes, leading to generation of free radicals, which stimulate melanogenesis. Elevated levels of estrogens and progesterone (as occurring in pregnancy) are important. Melasma also develops with estrogen- and progesterone-containing pills.<sup>[2]</sup> However, progesterone may be more important, as melasma develops in postmenopausal woman who are given progesterone and not when given estrogen supplementation. Estrogens probably stimulate melanogenesis through estrogen receptors present on melanocytes.<sup>[1]</sup> Other hormones may also be important. Genetic factors are indicated because more than 30% of patients have a family history of melasma.<sup>[3]</sup>

Constituents of cosmetics have been frequently incriminated. Drugs (phenytoin, griseofulvin, and NSAIDs) can cause melasma-like pigmentation. The face is most commonly affected though rarely pigmentation may extend on to 'V' area of the neck or may be confined to the forearms. On the face, three patterns of melasma are recognized:

- **Centrifacial:** The most frequent (63%) pattern, with pigmentation on cheeks, forehead, upper lip, nose, and chin.
- **Malar:** Constituting 21%, with pigmentation present only on cheeks and nose.
- **Mandibular:** The least common (16%), with pigmentation on ramus of the mandible.

## MATERIALS AND METHODS

The present study was a prospective observational study in which sixty -six clinically diagnosed female melasma patients of reproductive age group i.e 15-45 years attending Dermatology Out Patient Department in C.R.G.H, Ujjain, Madhya Pradesh constituted the subject material for present study. These patients belonged to Ujjain and its adjoining districts.

The patients with post inflammatory hyperpigmentation, other pigmentary disorders with epidermal dermal pigmentation e.g. Nevus of Ota, Nevus of Ito, Mongolian spots and previous cases of melasma were excluded.

A detailed history and clinical examination of each patient was carried out. The personal data like family history of melasma, marital status, number of children, age of onset, use of drugs and cosmetics and exposure to sunlight was recorded. Area and extent of

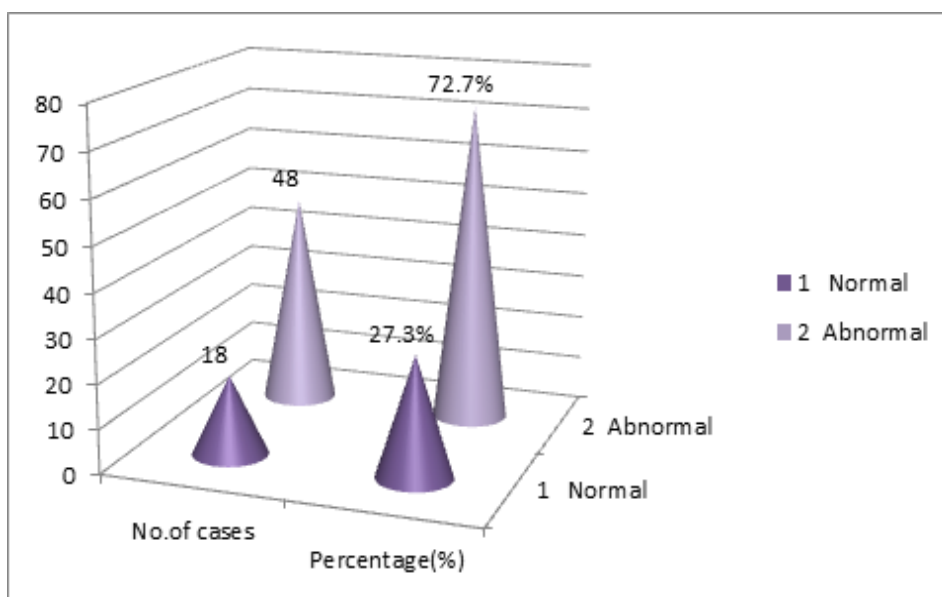
involvement of melasma were also noted. The results of routine investigations like complete blood and urine examinations, random blood sugar were recorded. Biochemical parameter of serum estradiol was done in the biochemistry laboratory of the C.R.G.H. Sample was drawn at any time of the menstrual cycle. Estradiol and progesterone were estimated by radioimmunoassay (RIA). The data were collected and transferred to SPSS version 16 and analyzed accordingly.

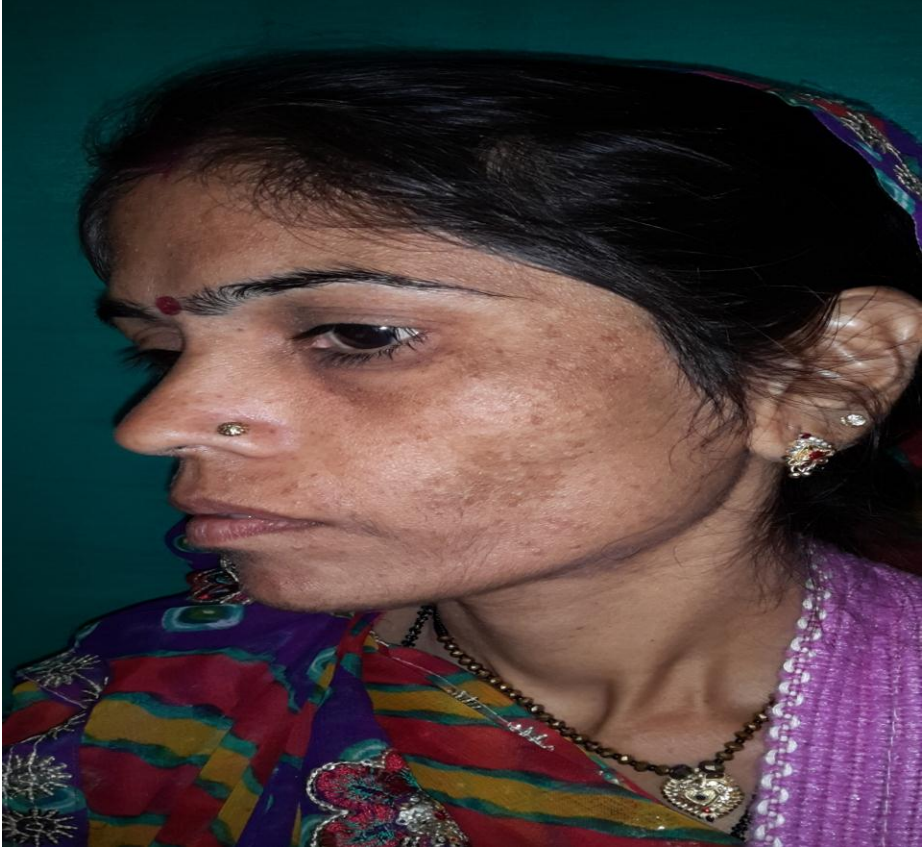**RESULTS AND OBSERVATIONS**

Sixty six females with an age range of 15-45 years were enrolled. 33 (50.0%) belonged to the age group 26-35 years, 17 (25.8%) were of 15-25 years and 16 (24.25%) were in the age range of 36-45 years while the mean age of all the patients was 30.5 years. All the patients were married. Normal value taken for estrogen in follicular phase was 26.1-161.0 and in luteal phase was 32.7-201.0. Out of 66 patients, estrogen level of 18 (27.3%) patients was found to be normal while that of 48 (72.7%) was found to be deranged with either an increase or decrease, mostly increased in the estradiol levels, showing its significant effect on causation of melasma. The maximum number of patients had raised values between 201-500.0pg/ml.

**Distribution of Number of Cases according to Estrogen level**

S. No.	Normal Estrogen values (pg/ml)	Estrogen Level	No. of cases	Percentage (%)
1.	26.1-16.0 pg/ml (follicular phase)	Normal	18	27.3
2.	32.7-201.0 pg/ml (luteal phase)	Abnormal	48	72.3
	Total	Total	66	100.0





## DISCUSSION

The exact cause of melasma is uncertain but a direct relationship with female hormonal activity appears to be significant because it commonly occurs in pregnancy and with the use of oral contraceptive pills<sup>[4,5]</sup>. Melasma is thought to be the stimulation of melanocytes by the female sex hormones estrogen and progesterone to produce more melanin pigments when the skin is exposed to sun. Many cases appear to be related to excess estrogen, either produced endogenously during pregnancy or delivered exogenously through the use of oral contraceptive pills and hormone replacement therapy; however, the mechanism of this interaction has not been elucidated. In vitro studies<sup>[6,7]</sup> have shown that cultured human melanocytes express estrogen receptors, and estradiol increases the levels of tyrosinase, tyrosinase-related-protein 1 and tyrosinase related-protein 2, the enzymes involved in human eumelanogenesis within normal human melanocytes. Although, estrogen has been hypothesized to be central in the pathogenesis of melasma, there had been few studies to support this view. It is known that melanogenesis is mediated, at least in part, by the binding of melanocyte stimulating hormone to the human melanocortin receptor 1 (MCR1) in normal human melanocytes while estradiol increases MCR1, mRNA levels and tyrosinase levels, although the mechanism of these responses has not been established.<sup>[7,8,9]</sup>

In our study, all the patients were married. Sixty six females with an age range of 15-45 years were enrolled. 33 (50.0%) belonged to the age group 26-35 years, 17 (25.8%) were of 15-25 years and 16 (24.25%) were in the age range of 36-45 years while the mean age of all the patients was 30.5 years. In our study, out of 66 patients, estrogen level of 18 (27.3%) patients was found to be normal while that of 48 (72.7%) was found to be deranged with either an increase or decrease, mostly increased in the estradiol levels. This is similar to the study of Khalid Mahmood et al in which 89.1% showed deranged values of estrogen (mostly increased).<sup>[10]</sup>

Study of Jee et al. reported a dose-dependent proliferation of melanocytes in culture after 17 $\beta$ -estradiol addition, despite a decrease of tyrosinase activity and melanin content.<sup>[11]</sup>

Iffat Hassan et al Higher levels of E2-17 $\beta$  on 5, 7, 9 were observed in the study group. These findings indicate a possible role of high E2-17 $\beta$  in the maintenance of melasma.<sup>[12]</sup>

Kim NH et al showed that downregulation of H19 and a sufficient dose of estrogen treatment might be involved in the development of melasma.<sup>[13]</sup>

According to Dr. Zein E. Obagi When estrogen levels are elevated, either from pregnancy or birth control pill, additional melanin is produced. With all this extra melanin floating in the skin, it settles as dark deposits, which results in melasma.

Thus, the present study gives an understanding about the role of estrogen, in the causation of melasma.

## CONCLUSION

It is concluded from the present study that raised estradiol (estrogen) levels contribute towards the development of melasma and it may serve as the basis for exploring different topical or systemic anti-estrogen therapies for melasma in future studies.

## BIBLIOGRAPHY

1. Bandyopadhyay D. Topical treatment of melasma. *Indian J Dermatol* 2009;54:303-9.
2. Grimes PE, Yamada N, Bhawan J. Light microscopic, immunohistochemical and ultra-structural alteration in patients with melasma. *Amer J Dermatopathol* 2005;27:96-101.
3. Kang WH, Yoon KH, Lee ES, Kim J, Lee KB, Yim H, et al. Melasma: Histopathological characteristics in 56 Korean patients. *Br J Dermatol* 2002;146:228-37.
4. Grimes PE. Melasma: Etiologic and therapeutic considerations. *Arch Dermatol* 1995; 131:1453-7.
5. Sodhi VK, Sausker WF. Dermatoses of pregnancy. *Am Fam Physician* 1988; 37:131-8. 7.
6. Im S, Eun-So L, Kim W et al. Donor specific response of estrogen and progesterone on cultured human melanocytes. *Korean Med Sci* 2002; 17: 58- 64. 25.
7. Kippenherger S, Loitsch S, Solano F et al. Quantification of tyrosinase, TRP-1 and TRP-2 transcripts in human melanocytes by reverse transcriptase-competitive multiplex PCR--regulation by steroid hormones. *J Invest Dermatol* 1998; 110: 364-7.
8. Suzuki I, Cone RD, Im S et al. Binding of melanotropic hormones to the melanocortin receptor MC1R on human melanocytes stimulates proliferation and melanogenesis. *Endocrinology* 1996; 137: 1627-35. 27.
9. Scott MC, Suzuki I, Abdel-Malek ZA. Regulation of the human melanocortin 1 receptor expression in epidermal melanocytes by paracrine and endocrine factors and by ultraviolet radiation. *Pigment Cell Res* 2002; 15: 433-9.
10. Mahmood K, Nadeem M, Aman S, Hameed A, Kazmi AH. Role of estrogen, progesterone and prolactin in the etiopathogenesis of melasma in females. *J Pak Assoc Dermatol*. 2011;21:241-7.
11. Jee SH, Lee SY, Chiu HC, Chang CC, Chen TJ (1994) Effects of estrogen and estrogen receptor in normal human melanocytes. *Biochem Biophys Res Commun* 199: 1407-1412.
12. Hassan I, Kaur I, Sialy R, Dash RJ. Hormonal milieu in the maintenance of melasma in fertile women. *J Dermatol*. 1998;25:510-2.
13. Kim NH, Lee CH, Lee AY. H19 RNA downregulation stimulated melanogenesis in melasma. *Pigment Cell Melanoma Res*. 2010;23:84-92.