



## Original Research Article

## Correlation of cutaneous findings and sonographic ovarian morphology in polycystic ovarian syndrome

Vaishnavi B V<sup>1</sup>, Aneesh S<sup>1,\*</sup>, Patra AK<sup>1</sup>, Raghavendra BN<sup>1</sup>, Sandhaya<sup>1</sup><sup>1</sup>Dept. of Dermatology, MVJ Medical college and Research Hospital, Bangalore, Karnataka, India

## ARTICLE INFO

## Article history:

Received 31-07-2020

Accepted 05-09-2020

Available online 05-12-2020

## Keywords:

Acne vulgaris

Acanthosis nigricans

Androgenetic alopecia

Polycystic ovarian syndrome

## ABSTRACT

**Background:** Polycystic ovarian syndrome (PCOS) is a common endocrinopathy typified by oligoovulation or anovulation, signs of androgen excess, and multiple small ovarian cysts. The prevalence and incidence of PCOS is on the rise with rapid modernisation and changes in lifestyle. The correlation of cutaneous findings and sonographic changes in ovaries in PCOS has not been studied extensively in Indian population. The present study was conducted to evaluate this correlation.

**Objectives:** To study and correlate the cutaneous features and ultrasonographic findings of ovaries in PCOS.

**Settings and Design:** This was hospital based cross sectional, observational study.

**Materials and Methods:** All the patients fulfilling the inclusion criteria were enrolled in the study. Both ovaries were examined sonographically for ovarian diameter, ovarian volume, follicular number and arrangement of follicles. Clinical and radiological findings were analysed statistically for correlation.

**Results:** An appraisal of 50 subjects showed that 40 (80%) patients experienced menstrual disorders. Cutaneous manifestations observed included acne, acanthosis nigricans, hirsutism, androgenic alopecia, seborrhoea, acro chordons of which acne and hirsutism were most commonly observed. Majority of study subjects, 24(48%) were found to have ovaries with follicular number of 15-16. All the cutaneous manifestations were noted to be significantly increased in 24 patients having a follicular number 15-16. 56% of cases had elevated free testosterone levels. Free testosterone levels correlated significantly with number of follicles ( $p=0.037$ ).

**Conclusion:** The cutaneous features of acne and hirsutism were most commonly observed in the study. Majority, 44% cases had consistent features of polycystic ovaries (PCO) on USG, 6 had normal study with no correlation between number of follicles in the ovaries and the cutaneous features.

© This is an open access article distributed under the terms of the Creative Commons Attribution License (<https://creativecommons.org/licenses/by/4.0/>) which permits unrestricted use, distribution, and reproduction in any medium, provided the original author and source are credited.

## 1. Introduction

Polycystic Ovarian Syndrome (PCOS) is a common endocrine disorder in women of child bearing age (15-20%). Indian studies have recorded a prevalence of 2.2% to 26% in adolescent age group.<sup>1</sup> In our country, since the prevalence rates are found to be higher in the younger age group it is important to identify and treat the problem at a early stage and henceforth combat the adverse metabolic effects, which would manifest much later in life.

Polycystic ovarian syndrome (PCOS) is a common endocrinopathy typified by oligoovulation or anovulation, signs of androgen excess, and multiple small ovarian cysts. These signs and symptoms vary widely between women and within individuals over time. Women with this endocrine disorder also have higher rates of dyslipidemia and insulin resistance, which increase long- term health risks. The diagnosis of PCOS is made if two of the following three Rotterdam criteria (2003) are present:

1. Oligoovulation (fewer than eight menses per 12 month period) and /or anovulation.

\* Corresponding author.

E-mail address: [raghavderm@gmail.com](mailto:raghavderm@gmail.com) (Aneesh S).

2. Clinical hyperandrogenism and /or biochemical signs of hyperandrogenism.
3. PCO on ultrasound (>12 follicles in each ovary measuring 2-9 mm in diameter and/or increased ovarian volume >10mL).

Other disorders that cause irregular menstrual cycles and androgen excess must be excluded prior to the diagnosis of PCOS.<sup>2</sup> Cutaneous manifestations of PCOS can be caused by peripheral androgen excess and insulin resistance. Hirsutism, acne, seborrheic dermatitis and androgenic alopecia are caused by androgen excess and acanthosis nigricans is caused by insulin resistance.

## 2. Materials and Methods

This was a hospital based, cross sectional, observational study conducted in patients with clinical features of PCOS attending the skin and gynecology departments of MVJMC & RH from September 2016 to September 2018 with approval of Institutional Ethical Committee. 50 patients (non pregnant women between 15-35 years of age) having any 2 of the following criteria were enrolled for the study:

1. Menstrual irregularity.
2. Clinical or biochemical hyperandrogenemia.
3. Polycystic or normal ovarian morphology on USG.

Informed consent was taken from each patient. A detailed history regarding the age, marital status, symptoms, duration of disease, menstruation, family history and treatment were recorded in a proforma. The study subjects underwent a meticulous general physical and cutaneous examination. Ultrasonographic examination of abdomen and pelvis were performed using Voluson 730 pro ultrasound machine and findings pertaining to ovaries alone were considered on all the study subjects. Both ovaries were examined for ovarian diameter, ovarian volume, follicular number and arrangement of follicles. Free testosterone levels were estimated.

### 2.1. Statistical analysis

Statistical analysis of the data was performed using the Statistical Package for Social Sciences (SPSS Version 17). Statistical significance of the results was determined by the Chi-square test. A p value of <0.05 was considered to be statistically significant.

## 3. Results

A total of 50 patients were enrolled for the study, majority of patients (32%) belonged to 21-25 years age group as shown in Table 1 and 40 (80%) patients experienced menstrual disorders manifesting as amenorrhoea in 22% of the subjects, oligomenorrhoea in 36% and polymenorrhoea in 22% of the cases. Majority of the patients were obese and

most of patients (36%) had a BMI in the range of 23-24.9 kg/m<sup>2</sup>. It was also noted that 88% of patients had polycystic ovaries on USG as shown in Figure 1.

In our study acne vulgaris was the most common cutaneous manifestation observed in 38 (76%) patients. Hirsutism and androgenic alopecia were present in 31(34%) and 29 (58%) women respectively. Only 18(46%) patients expressed seborrheic dermatitis as shown in Table 2. Majority of them (56%) had elevated free testosterone levels. The analysis of correlation between cutaneous features and ovarian morphology on ultrasonographic study revealed that PCO was present in 93.5% of hirsute subjects and 93.1% of cases with acne (Table 3) It was observed in the present study that the cutaneous features was evident more in cases who had a follicle number of 15 and 16. However, acanthosis nigricans was noted with increased frequency in subjects with follicle number of 12 and 14 (Table 4)

The cutaneous feature of hirsutism was observed in 62% of the cases with the commonest site being upper lip and chin. (Figure 2) Acne vulgaris was documented in 76% of the patients with grade I lesions seen in 31.6% of cases. (Figure 3)

The sonographic evaluation of the ovaries showed that 36% cases had a follicle number between 12 and 14. Further, 7 cases in this group had normal free testosterone levels and 11 had raised testosterone level.

## 4. Discussion

The predominant age group afflicted with PCOS was between 21-25 years (32%) followed by 15-20 years (28%). Mean age was 24.26 years. The documented data suggest that PCOS is more common in the reproductive age group and the incidence of disease decreases with advancing age.

In a study by Ramanand et al.<sup>3</sup> (2013), 30.8% were in the age group of 19 to 22 years, and 7.5% were in the age group of 23 to 26 years and a study by Gowri et al.<sup>4</sup> showed 16\40(40%) were in the age group of 21-25 years. The age profile of the cases in our study was observed to reflect closely with the above two studies.

The occurrence of menstrual irregularity was observed in 80% of the study subjects with oligomenorrhoea being the most common entity (36%). In one of largest published data on 1741 patients by Balenet al.<sup>5</sup> approximately 30% of the patients had regular menses, 50% oligomenorrhoea, and 20% amenorrhoea. It appears that oligomenorrhoea can be a common symptom of PCOS even in western population.

Majority of the patients were overweight and most (36%) of the patients had BMI in the range of 23- 24.9 Kg/m<sup>2</sup>. The prevalence of obesity and overweight women in a study by Keen MA, et al was 27% and 53%, respectively<sup>6</sup> which is comparable to our study.

In the present study the most common cutaneous manifestation was acne vulgaris which was present in 38

(76%) patients. Hirsutism and androgenic alopecia were present in 31(34%) and 29 (58%) of women respectively. Only 18(46%) patients expressed seborrheic dermatitis. Gowri BV et al. evaluated the incidence and prevalence of skin manifestations in 40 patients with PCOS. In their study, of all the cutaneous manifestations, acne was seen in the maximum number of cases (67.5%), followed by hirsutism (62.5%), seborrhoea (52.5%), androgenetic alopecia (AGA) (30%), acanthosis nigricans (22.5%), and acrochordons (10%).<sup>4</sup> The cutaneous manifestations in our study is very much comparable to study done by Gowri et al.

In our study 44 (88%) patients had findings consistent with PCO on USG, while 6 (12%) patients showed normal ovaries. A survey of research data revealed frequencies that resemble closely with the results in our study. In a study by Botsis et al PCO was detected by transvaginal ultrasound in only 75% of women with clinical diagnosis of PCOS. 25% women with PCOS did not have characteristic finding on ultrasound.<sup>7</sup> In our study, out of 50 patients, 28(56%) patients had raised testosterone levels and 22(44%) had normal levels.

An increased level of serum testosterone was seen in 22 (55%) patients in a study by Gowri BV et al similar to our study.<sup>4</sup> In this study, all the cutaneous manifestations were observed to be present in a higher magnitude mostly in the group with ovarian follicle number between 15-16, followed by 12-14 follicles and 17-19 follicles (Table 5). After a thorough search of the research database, there were no studies showing correlation between number of follicles and clinical features.

There was no statistically significant correlation observed with the number of follicles and clinical features. The normo androgenic subtype of PCOS lacks any association with ovarian follicle number and other morbidities as seen in classical PCOS, this could possibly explain the above occurrence in this study.

**Table 1:** Age wise distribution of patients

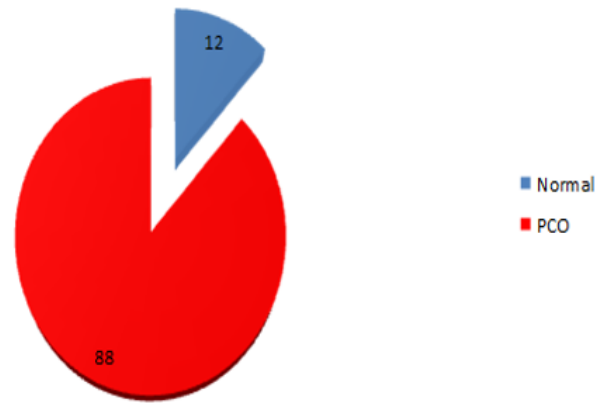
Age in years	Number of cases	Percentage
15-20	14	28
21-25	16	32
25-30	13	26
31-35	7	14
Total	50	100

**5. Conclusion**

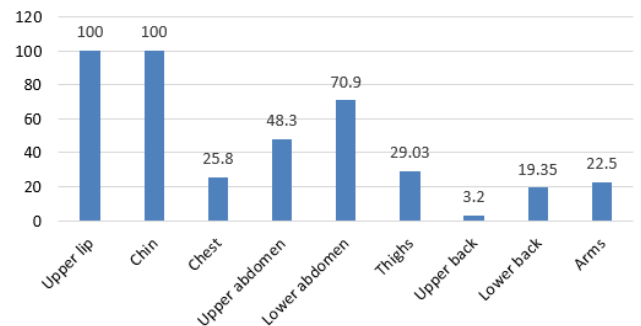
PCOS is known to have various cutaneous manifestation of hyperandrogenism. The cutaneous features of acne and hirsutism were observed most commonly, amongst the study group, followed by female pattern hair loss, acanthosis nigricans, acrochordons and seborrheic dermatitis. Free testosterone correlated well with number of follicles and p value was 0.037, which was statistically significant.

**Table 2:** Skin manifestations in patients with PCOS

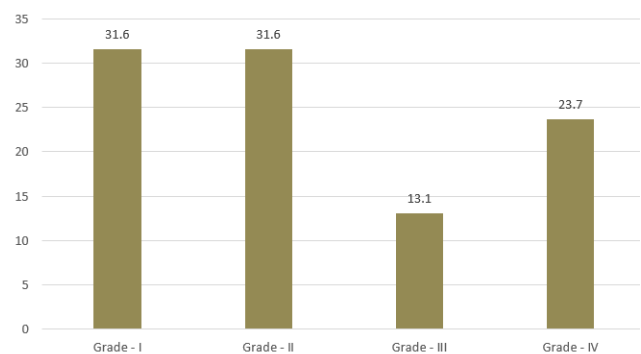
S.No	Cutaneous finding	Number of cases	Percentage
1	Hirsutism	31	62
2	Acne Vulgaris	38	76
3	Acanthosis nigricans	27	54
4	Androgenetic alopecia	29	58
5	Seborrheic dermatitis	18	36
6	Acrochordons	20	40



**Fig. 1:** USG findings in PCOS patients



**Fig. 2:** Distribution of hirsutism



**Fig. 3:** Grades of acne

**Table 3:** Correlation of cutaneous manifestations with USG findings

S.No	Cutaneous finding	Number of cases	Number of cases with PCO on USG in percent	Percentage
1	Hirsutism	31	29	93.5
2	Acne vulgaris	38	34	89.47
3	Acanthosis nigricans	27	22	81.4
4	Androgenetic alopecia	29	27	93.1
5	Seborrheic dermatitis	18	16	88.8
6	Acrochordon	22	20	90.9

**Table 4:** Correlation of cutaneous findings with number of follicles

Follicle number	Hirsutism (n-50)	Acne vulgaris (n-50)	Acanthosis nigricans (n-50)	Androgenetic alopecia (n-50)	Acro chordon (n-50)	Seborrheic dermatitis (n-50)
12-14	11 (22%)	14 (28%)	13(26%)	12 (24%)	7 (14%)	5 (10%)
15-16	16 (32%)	19 (38%)	11 (22%)	13(26%)	13 (26%)	10 (20%)
17-19	2 (4%)	2 (4%)	0	1(2%)	0	1 (2%)
Normal	2 (4%)	3 (6%)	3 (6%)	3 (6%)	2 (4%)	2 (4%)
Total	31	38	27	29	22	18

**Table 5:** Correlation of number of follicles, free testosterone levels and clinical features

Number of follicle	Number of cases	Free testosterone level	Hirsutism	Acne	Acanthosis nigricans	Androgenetic alopecia	Seborrheic dermatitis	Acro chordon
12-14	18	Normal -7 ↑- 11	4 7	5 9	5 8	5 7	2 3	1 7
15-16	24	Normal -13 ↑-11	7 9	10 9	5 6	9 4	5 5	6 6
17-19	2	Normal-2 ↑-0	2 0	2 0	0	1 0	1 0	0
Normal	6	Normal-0 ↑-6	2 0	3 0	0 3	3 0	2 0	2 0
Total	50	50	31	38	27	29	18	22

Majority, 44 cases had PCO on USG, 6 had normal study with no correlation between number of follicles in the ovaries and the cutaneous features. A clear cut correlation might have been observed if there would have been a larger study sample.

## 6. Limitations

Small sample size was the major limiting factor in the study

## 7. Source of Funding

No financial support was received for the work within this manuscript.

## 8. Conflict of Interest

The authors declare they have no conflict of interest.

## References

- Joshi B, Mukherjee S, Patil A, Purandare A, Chauhan S, Vaidya R. A cross-sectional study of polycystic ovarian syndrome among adolescent and young girls in Mumbai, India. *Indian Journal of Endocrinology and Metabolism*. 2014;18(3):317–317. Available from: <https://dx.doi.org/10.4103/2230-8210.131162>. doi:10.4103/2230-8210.131162.
- Rotterdam E. ASRM sponsored PCOS consensus workshop group. Revised 2003 consensus on diagnostic criteria and long term health risk related to polycystic ovary syndrome (PCOS). *Hum Reprod*.

2004;19:41–48.

- Ramanand S, Ramanand J, Ghanghas R, Ghongane B, Jain S, Patwardhan M. Clinical characteristics of polycystic ovary syndrome in Indian women. *Indian Journal of Endocrinology and Metabolism*. 2013;17(1):138–138. Available from: <https://dx.doi.org/10.4103/2230-8210.107858>. doi:10.4103/2230-8210.107858.
- Chandravathi PL, Sindhu PS, Naidu K, Gowri B. Correlation of skin changes with hormonal changes in polycystic ovarian syndrome: A cross-sectional study clinical study. *Indian Journal of Dermatology*. 2015;60(4):419–419. Available from: <https://dx.doi.org/10.4103/0019-5154.160505>. doi:10.4103/0019-5154.160505.
- Balen AH, Conway GS, Kaltasg. Polycystic ovarian syndrome: the spectrum of the disorder in 1741 patients. *Hum*. 1995;10:2107–2118.
- Keen M, Shah I, Sheikh G. Cutaneous manifestations of polycystic ovary syndrome: A cross-sectional clinical study. *Medknow*; 2017. Available from: <https://dx.doi.org/10.4103/2229-5178.202275>. doi:10.4103/2229-5178.202275.
- Botsis D, Kassanos D, Pyrgiotis PA. Sonographic incidence of polycystic ovary in gynecological population. *Ultrasound Obstet Gynecol*. 1995;6:182–185.

## Author biography

**Vaishnavi B V**, Resident

**Aneesh S**, Associate Professor

**Patra AK**, Professor and Head

**Raghavendra BN**, Professor

**Sandhaya**, Senior Resident

**Cite this article:** Vaishnavi B V, Aneesh S, Patra AK, Raghavendra BN, Sandhaya. Correlation of cutaneous findings and sonographic ovarian morphology in polycystic ovarian syndrome. *IP Indian J Clin Exp Dermatol* 2020;6(4):333-337.