



## Original Research Article

## Evaluation of trichoscopic features in female pattern hair loss

Krishnendra Varma<sup>1</sup>, Ujjwal Kumar<sup>1</sup>, Aishwarya Mahadik<sup>1</sup>, Somya Agrawal<sup>1,\*</sup><sup>1</sup>Dept. of Dermatology, RD Gardi Medical College, Ujjain, Madhya Pradesh, India

## ARTICLE INFO

## Article history:

Received 22-10-2021

Accepted 19-11-2021

Available online 11-12-2021

## Keywords:

Trichoscopy

Female pattern hair loss

Androgenetic alopecia

## ABSTRACT

**Introduction:** Female pattern hair loss (FPHL) is explained by decrease in hair fiber production and their eventual miniaturization. It is considered a counterpart of male androgenetic alopecia but the role of androgens in its pathogenesis is yet to be proven.

**Aim:** To evaluate the trichoscopic features in females with patterned hair loss.

**Materials and Methods:** Inclusion and exclusion criteria were applied and 37 cases were enrolled in our study. Detailed history and clinical examination were done to establish the diagnosis. Trichoscopic examination was done after taking consent in diagnosed cases.

**Results:** On trichoscopy, hair diameter variability, peri pilar sign, white dots, scalp pigmentation and focal atrichia was observed in 62.2%, 62.2%, 40.5%, 45.9% and 40.5% respectively. Most common trichoscopy finding observed was peri pilar sign and hair diameter variability in 23/37 females.

**Conclusion:** Definitive diagnosis of FPHL is difficult to be established solely on the basis of clinical examination. Thus, trichoscopy serves as a non-invasive tool to ascertain the diagnosis in these patients.

This is an Open Access (OA) journal, and articles are distributed under the terms of the [Creative Commons Attribution-NonCommercial-ShareAlike 4.0 License](https://creativecommons.org/licenses/by-nc-sa/4.0/), which allows others to remix, tweak, and build upon the work non-commercially, as long as appropriate credit is given and the new creations are licensed under the identical terms.

For reprints contact: [reprint@ipinnovative.com](mailto:reprint@ipinnovative.com)

## 1. Introduction

Initially the term 'diffuse alopecia' was widely used for hair loss in women but with the demonstration of male hormones in its pathogenesis, the term androgenetic alopecia was established.<sup>1</sup> FPHL was thought to be the variant of same entity but the definite evidence is still lacking. The term 'patterned baldness' is described as decrease in hair fiber production and their eventual miniaturization. It presents with thinning and shortening of hair with increase in central parting.

Its incidence increases with age and the age of onset is usually 18-45 years with the second peak of incidence noted between 50-60 years of age.<sup>2</sup>

Trichoscopic patterns observed in patients of FPHL include:

1. Hair diameter variability of more than 20% is diagnostic, especially in frontoparietal region.<sup>3</sup>
2. Peri pilar sign is a light brown atrophic area seen during the early stages and correlates with the inflammatory infiltrate.<sup>4</sup>
3. Scalp pigmentation is a patchy honeycomb pattern due to penetration of ultraviolet radiation through thin hair.
4. White dots are seen in later grades.
5. Yellow dots result due to accumulation of sebum in dilated hair follicles.
6. Focal atrichia is complete atrophy of pilosebaceous units.

Some of the trichoscopic findings were found to be overlapping in the same patient. It serves as an important tool to establish the diagnosis and to know the pathological response in these patients.

\* Corresponding author.

E-mail address: [somyaagr@yahoo.com](mailto:somyaagr@yahoo.com) (S. Agrawal).

**2. Materials and Methods**

This observational study was conducted in department of dermatology of R.D. Gardi Medical College, Ujjain to evaluate the trichoscopy findings in patients of female pattern hair loss. The study period was from September 2020 to October 2021. Written consent and ethical clearance from Institutional Ethical Committee was taken.

Detailed history regarding onset, duration, progression, medical and family history was taken. Thorough clinical examination was done to look for specific features of patterned baldness like diffuse thinning over crown and increase in central parting.

Trichoscopic examination was done using handheld DermLite DL4 dermoscope (10x) and digital photographs were taken using iPhone XR. Findings were summarized and discussed in detail.

**2.1. Inclusion criteria**

Female patients with clinical features suggestive of patterned hair loss.

**2.2. Exclusion criteria**

Females on corticosteroids, chemotherapeutic drugs and hair growth promoters.

**3. Results**

Out of 37 cases examined for female pattern hair loss, majority of them belonged to the age group of 37-45 years (48.6%). The mean age of presentation found to be was 33.9±7.8 years. The mean duration of hair loss noted was 4.32 years in our study.

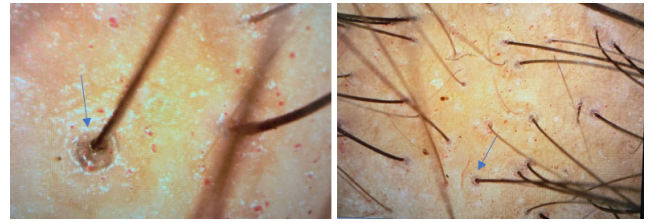
Among the clinically diagnosed 37 cases, trichoscopic findings seen were peri pilar sign (23 cases), hair diameter variability (23 cases), white dots (15 cases), scalp pigmentation (17 cases) and focal atrichia (15 cases).

**Table 1:** Distribution of patients according to age

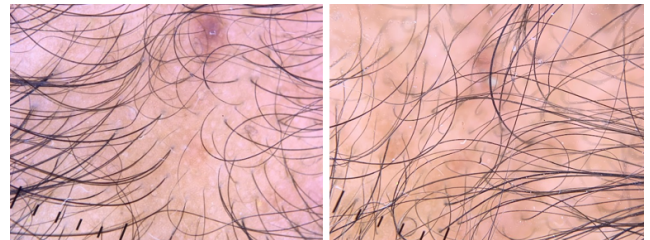
Age group	Frequency	Percentage
18-26 years	9	24.3%
27-36 years	10	27%
37-45 years	18	48.6%
Total	37	100%

**Table 2:** Distribution of patients according to duration of hair loss

Duration	Frequency	Percentage
1-3 years	12	32.4%
4-6 years	18	48.6%
7-9 years	7	18.9%
Total	37	100%



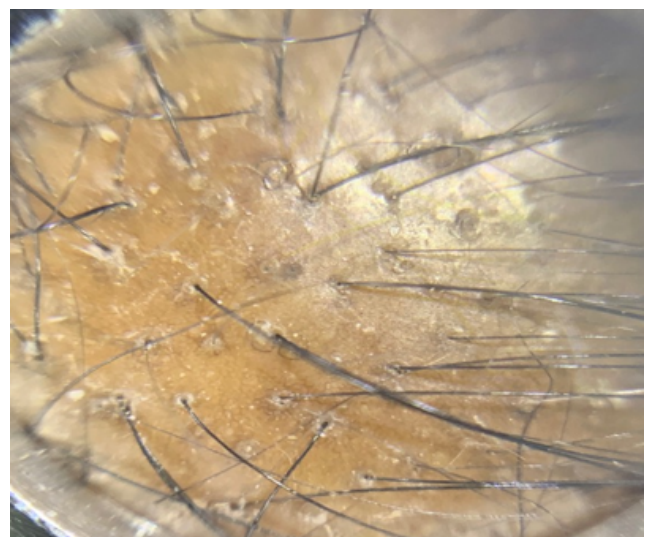
**Fig. 1:** Peripilar sign



**Fig. 2:** Variability in hair shaft diameter and decrease in number of hair per follicular unit



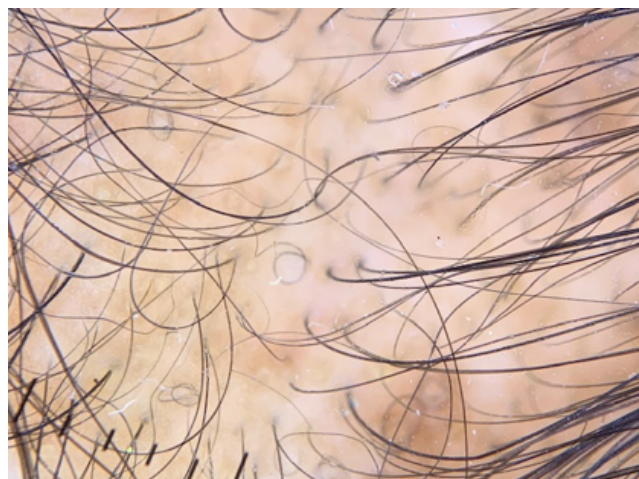
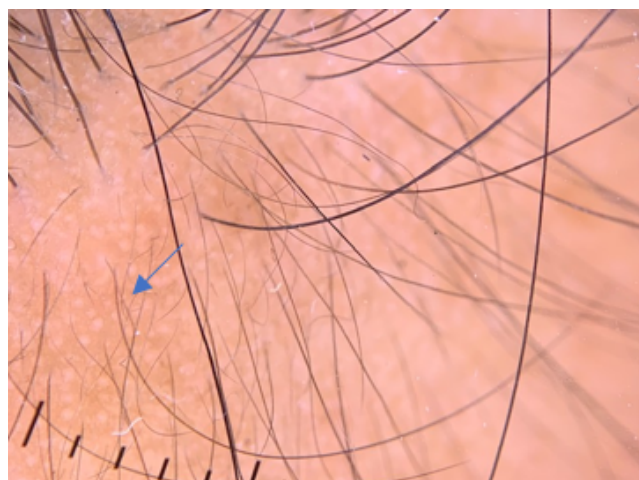
**Fig. 3:** Normal density over occipital scalp



**Fig. 4:** Scalp pigmentation

**Table 3:** Distribution of patients according to trichoscopy findings

Trichoscopy findings	Present		Absent	
	n	%	n	%
Hair diameter variability	23	62.2	14	37.8
Peri pilar sign	23	62.2	14	37.8
White dots	15	40.5	22	59.5
Scalp pigmentation	17	45.9	20	54.1
Focal atrichia	15	40.5	22	59.5

**Fig. 5:** Focal atrichia**Fig. 6:** White dots

Most common finding observed was hair diameter variability and peripilar sign in 62.2% of females whereas the least common findings noted were white dots and focal atrichia in 40.5% females.

#### 4. Discussion

The mean age of presentation in our study was found to be  $33.9 \pm 7.8$  years. This was concordant with the study of Zhang et al.<sup>5</sup> conducted in 60 patients having the mean age of  $34 \pm 10.6$  years whereas the mean age of presentation was found to be 31.17 years in a study of Tandon et al.<sup>6</sup> conducted at RML Hospital, New Delhi.

The mean duration of hair loss was found to be  $4.3 \pm 2$  years in our study. This was in agreement with the study conducted by Zhang et al.<sup>5</sup> having the mean duration of  $4.49 \pm 3.76$  years while the study conducted by Tandon et al.<sup>6</sup> showed the mean duration of 5.1 years.

Hair diameter variability and peri pilar sign was found in maximum number of females in our study (62.2%). This was concordant with the study conducted by Tosti et al.<sup>7</sup> showing variability in thickness as the most common finding. Hair diameter variability of  $>20\%$  is suggestive of miniaturization whereas peri pilar sign is a brown atrophic area around the follicle indicating peri follicular infiltrate. However, Zhang et al.<sup>5</sup> found scalp pigmentation as the most common trichoscopy finding. It results due to penetration of ultra violet rays through thin hair and bald scalp. It was found in only 45.9% females in our study. Zhang et al.<sup>5</sup> showed significant association of scalp pigmentation and focal atrichia (pencil-erased focal hair loss) with grade of hair loss with these findings being more evident in higher grades whereas such association was absent in our study. Other findings included white dots and yellow dots. White dots signify eccrine gland pores whereas yellow dots represent empty follicles filled with sebum. These trichoscopy findings help in differentiating female pattern hair loss from its very close differential chronic telogen effluvium.

#### 5. Conclusion

The definite diagnosis of female pattern hair loss is difficult to be established solely on the basis of clinical examination due to its close resemblance with chronic telogen effluvium. Hence, trichoscopy serves as an important non-invasive tool to ascertain the diagnosis in these females.

#### 6. Source of Funding

No financial support was received for the work within this manuscript.

#### 7. Conflict of Interest

None.

#### References

- Hamilton J. Male hormone stimulation is prerequisite and an incitant in common baldness. *Am J Anat.* 1942;71(3):451–80. doi:10.1002/aja.1000710306.
- Olsen EA. Female pattern hair loss. *J Am Acad Dermatol.* 2002;45(3):70–80. doi:10.1067/mjd.2001.117426.

3. Lacharrière OD, Deloche C, Misciali C, Piraccini BM, Vincenzi C, Bastien P, et al. Hair diameter diversity: A clinical sign reflecting the follicle miniaturization. *Arch Dermatol*. 2001;137(5):641–6.
4. Ummiti A, Priya P, Chandravathi P, Kumar C. Correlation of trichoscopic findings in androgenetic alopecia and the disease severity. *Int J Trichology*. 2019;11(3):118–22. doi:10.4103/ijt.ijt\_103\_17.
5. Zhang X, Caulloo S, Zhao Y, Zhang B, Cai Z, Yang J, et al. Female pattern hair loss: Clinico-laboratory findings and trichoscopy depending on disease severity. *Int J Trichology*. 2012;4(1):23–8. doi:10.4103/0974-7753.96082.
6. Tandon S, Arora P, Gautam RK, Bhardwaj M, Garga U, Sharma N, et al. Correlation between clinical features, biochemical parameters, and histopathological findings in women with patterned baldness: Study from North India. *J Cutan Aesthet Surg*. 2019;12(1):42–8. doi:10.4103/JCAS.JCAS\_30\_18.
7. Tosti A, Piraccini BM, Sisti ADE. Hair loss in women. *Minerva Ginecol*. 2009;61(5):445–52.

### Author biography

**Krishnendra Varma**, Professor and Head

**Ujjwal Kumar**, Professor

**Aishwarya Mahadik**, Assistant Professor

**Somya Agrawal**, 3rd Year Resident

**Cite this article:** Varma K, Kumar U, Mahadik A, Agrawal S. Evaluation of trichoscopic features in female pattern hair loss. *IP Indian J Clin Exp Dermatol* 2021;7(4):284-287.