



Original Research Article

Different patterns of cutaneous manifestation of diabetes mellitus type-2 observed in tertiary care centre of South West Rajasthan

Anurag Bareth¹, Charul Agrawal¹, Kalpana Gupta^{1,*}¹Dept. of Dermatology, Venereology and Leprosy, Geetanjali Medical College and Hospital, Udaipur, Rajasthan, India

ARTICLE INFO

Article history:

Received 26-11-2021

Accepted 01-12-2021

Available online 11-12-2021

Keywords:

Diabetes mellitus

Acrochordon

Acanthosis nigricans

ABSTRACT

Introduction: Diabetes mellitus (DM) is a common endocrinal disorder caused by complex interaction of genetics and environmental factors. Various dermatological features are known to be cutaneous markers of diabetes mellitus like diabetic dermatopathy, acrochordons, acanthosis nigricans and bullous diabeticorum, etc.

Materials and Methods: An observational cross-sectional study on a total of 400 patients of Diabetes Mellitus Type-2. A complete cutaneous examination was done in all cases to observe for the presence of any specific or nonspecific dermatosis. All the statistical tests were two sided and P-value <0.05 was considered as significant level.

Results: This study showed that in specific cutaneous disorders, Acrochordon 138(34.5%) was the most common manifestation which was followed by, Bacterial Infections 93(23.5%), Dermatophytosis 77(19.2%), Candidiasis 76(19%), Acanthosis nigricans 50(12.5%) and Onychomycosis 33(8.25%) in decreasing order. Xerosis 259(64.7%) was the commonest manifestation in non-specific cutaneous disorders followed by, Generalized pruritus 200(50%), Seborrheic keratosis 35(8.75%) in decreasing order.

Conclusion: Cutaneous manifestations are quite common in uncontrolled (HbA_{1c}>7gm) type 2 diabetes mellitus as compare to controlled group. Uncontrolled group is more prone to develop diabetic complication like hypertension, diabetic retinopathy and peripheral neuropathy etc. It is concluded that, Diabetes mellitus Type-2 involves the skin quite often and whenever patients present with multiple skin manifestation and then diabetic status should be checked and controlled.

This is an Open Access (OA) journal, and articles are distributed under the terms of the [Creative Commons Attribution-NonCommercial-ShareAlike 4.0 License](https://creativecommons.org/licenses/by-nc-sa/4.0/), which allows others to remix, tweak, and build upon the work non-commercially, as long as appropriate credit is given and the new creations are licensed under the identical terms.

For reprints contact: reprint@ipinnovative.com

1. Introduction

Diabetes mellitus (DM) is a common endocrinal disorder caused by complex interaction of genetics and environmental factors. It is a common and debilitating disease¹ characterized by hyperglycaemia due to absolute or relative insulin deficiency. In India, the disease prevalence varies from 2.4% to 11.6%.² In this disorder, abnormalities in the metabolism of carbohydrates, alteration of metabolic pathways, vascular involvement in the form of atherosclerosis, microangiopathy, neuronal

involvement in form of sensory, motor and autonomic neuropathies and impaired host mechanism, all play a role.³ Abnormalities of insulin and elevated blood glucose level led to involvement of multiple organ system including cardiovascular, renal, nervous system, eyes and skin.⁴ Various dermatological features are known to be cutaneous markers of diabetes mellitus like diabetic dermatopathy, acrochordons, acanthosis nigricans and bullous diabeticorum, etc. Dermatological features of diabetes mellitus are highly beneficial to the clinicians as few of them can alert the medical practitioner to the diagnosis of Diabetes Mellitus and also reflect the status of glycaemic control and metabolic derangement.⁵ Therefore,

* Corresponding author.

E-mail address: drpankalgupta@yahoo.com (K. Gupta).

the aim of the present study was to evaluate the pattern of cutaneous manifestation and their complications in diabetes mellitus type-2 in controlled and uncontrolled state in South West Rajasthan.

2. Material and Methods

An observational cross-sectional study was conducted on a total of 400 patients who attended the dermatology outpatient department and admitted in medicine ward of Geetanjali Medical College and Hospital, Udaipur from 1st February 2015 to 31st January 2016. Patients with gestational diabetes, those associated with HIV or any malignancy, and hyperglycaemia due to chronic steroid intake were excluded from the study.

Detailed history with particular reference to cutaneous complaints like onset and duration of rash, history of evolution, progression and treatment modalities if any including demographic data, duration and type of diabetes was recorded. A complete cutaneous examination was done in all cases to observe for the presence of any specific or nonspecific dermatosis. Fasting and postprandial blood glucose and HbA1c were done in all cases and relevant microbiological, cytological or histopathological examinations were carried out in relevant cases to establish dermatological diagnosis.

Dermatological manifestation per patient and temporal relation with DM Type-2 were estimated using measures of mean (central tendency theorem) and measures of dispersion (standard deviation). All the statistical tests were two sided and P-value <0.05 was considered as significant level.

3. Results

Out of 400 patients, 208(52%) patients were males and 192(48%) were females. The mean age of patients were 47.6 ± 7.582 years within the range of 30-70 years. 260(65%) patients had DM Type-2 since the last 5 years, 89(22.25%) patients since last 5-10 years and 51(12.75%) patients since more than 10 years. Patients with uncontrolled DM Type-2 were 192(48%) and those with controlled DM Type-2 were 208(52%). 240(60%) patients were on oral hypoglycaemics, 114(28.7%) patients on insulin, 45(11.3%) patients on combination therapy (Table 1).

Out of 400 patients of DM Type-2, 208(52%) patients belong to the controlled group and 192(48%) patients belong to the uncontrolled group. Among the specific disorders, Dermatophytosis was present in 24(6%) patients in controlled group and 53(13.25%) patients in uncontrolled group. Candidiasis was present in 21(5.25%) patients in controlled group and 55(13.75%) patients in uncontrolled group. Bacterial Infection was present in 25(6.25%) patients in controlled group and 68(17%) patients in uncontrolled group. Acanthosis Nigricans was present in

13(3.25%) patients in controlled group and 37(9.25%) patients in uncontrolled group. Acrochordon was present in 44(11%) patients in controlled group and 94(23.5%) patients in uncontrolled group. Onychomycosis was present in 9(2.25%) patients in controlled and 24(6%) patients in uncontrolled group. Among the non-specific disorders, Generalized Pruritus was present in 69(17.25%) patients in controlled group and 131(32.75%) patients in uncontrolled group. Xerosis was present in 96(24%) patients in controlled group and 163(40.75%) patients in uncontrolled group (Table 2).

This study showed that in specific cutaneous disorders, Acrochordon 138(34.5%) was the most common manifestation which was followed by, Bacterial Infections 93(23.5%), Dermatophytosis 77(19.2%), Candidiasis 76(19%), Acanthosis nigricans 50(12.5%) and Onychomycosis 33(8.25%)(Figure 1). Xerosis 259(64.7%) was the commonest manifestation in non-specific cutaneous disorders followed by, Generalized pruritus 200(50%), Seborrheic keratosis 35(8.75%) (Figure 2).

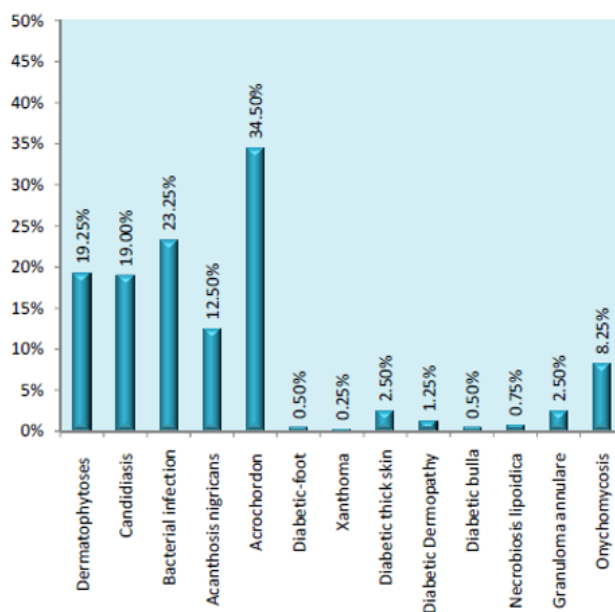


Fig. 1: Percentage of specific cutaneous disorders

4. Discussion

Globally, an estimated 462 million individuals are affected by type 2 diabetes, corresponding to 6.28% of the world's population.⁶

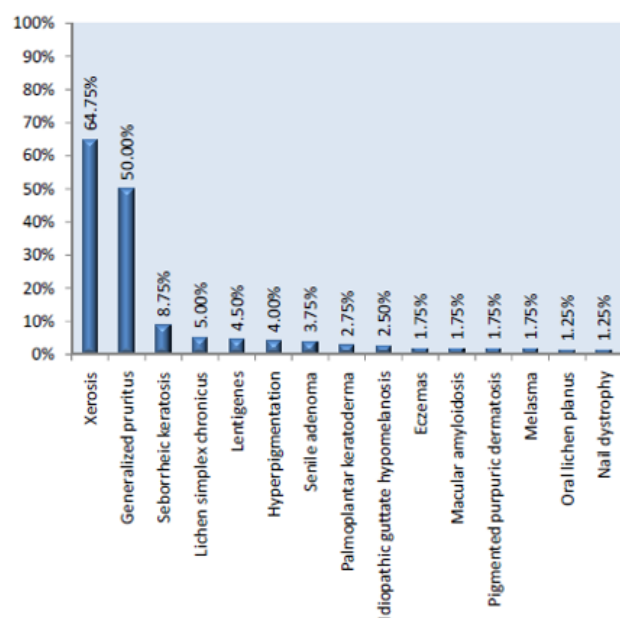
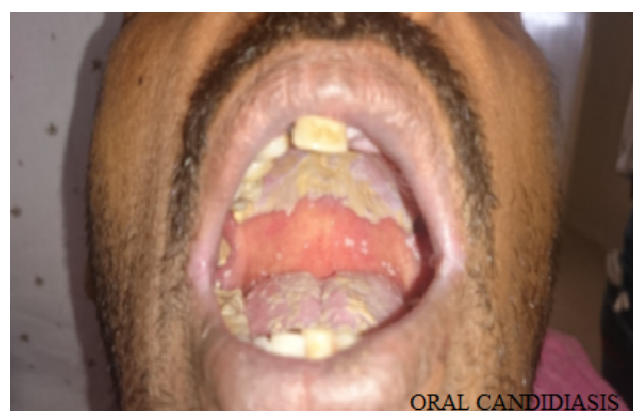In this study both controlled and uncontrolled patients were almost equal in numbers 52% and 48% respectively and male versus female ratio were 1:08. This study showed male predominance though few study like Bhat et al,⁷ Mahajan et al⁸ and Lugo et al⁹ showed female predominance.

Table 1: Descriptive summary

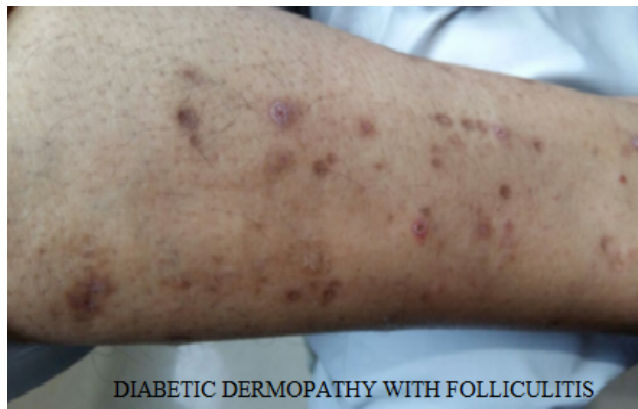
Study Variables	Descriptive Statistics
Gender distribution	
Male	208(52%)
Female	192(48%)
Age of patients (Mean ± SD years)	47.6 ± 7.582
Duration of DM Type-2 (Mean ± SD years)	
<5 years	260(3.5 ± 1.7)
5-10 years	89(6.8 ± 1.4)
>10 years	51(14 ± 3.2)
Status of DM Type-2	
Uncontrolled	192(48%)
Controlled	208(52%)
Status of treatment	
On oral hypoglycemics	240(60%)
On insulin	114(28.7%)
On combination therapy	45(11.3%)
No treatment	NIL

Table 2: Characteristic of diabetic patients in controlled and uncontrolled group

Characteristics	Controlled Group	Uncontrolled Group	P value
Specific disorder			
Dermatophytosis	24(6%)	53(13.25%)	<0.05
Candidiasis	21(5.25%)	55(13.75%)	<0.05
Bacterial Infection	25(6.25%)	68(17%)	<0.05
Acanthosis Nigricans	13(3.25%)	37(9.25%)	<0.05
Acrochordon	44(11%)	94(23.5%)	<0.05
Onychomycosis	9(2.25%)	24(6%)	<0.05
Non-specific			
Generalized Pruritus	69(17.25%)	131(32.75%)	<0.05
Xerosis	96(24%)	163(40.75%)	<0.05

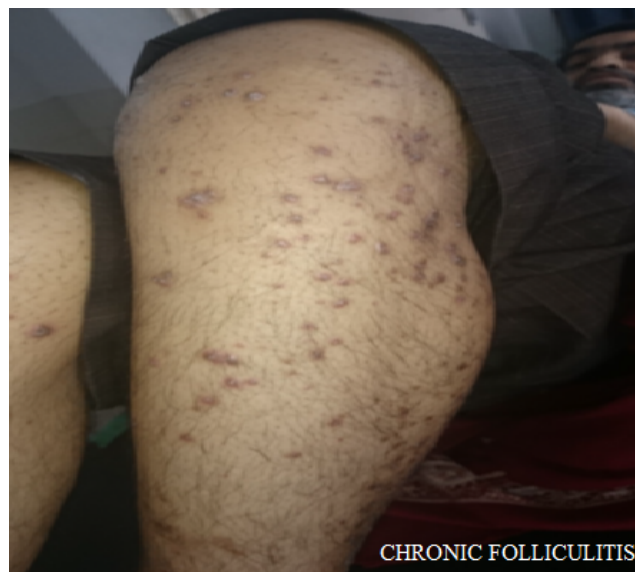**Fig. 2:** Percentage of non-specific cutaneous disorders**Fig. 3:** Oral Candidiasis

Mean age of diabetic patients was 48 years. This seems to be similar to the report Ahmed et al,¹⁰ where the mean age of diabetic patients was 54 years. It signifies that majority of them had longstanding diabetes affecting their social activities, as well as, productivity.¹⁰



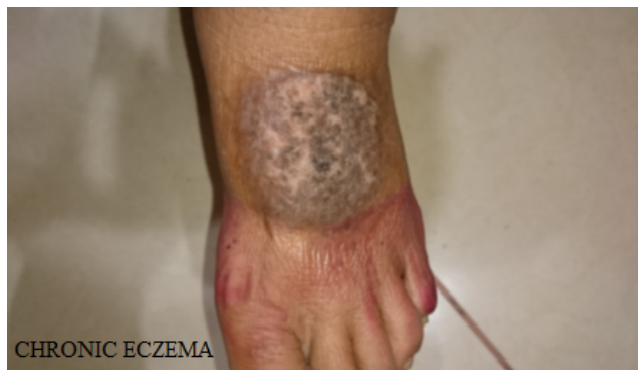DIABETIC DERMOPATHY WITH FOLLICULITIS

Fig. 4: Diabeticdermopathy with folliculitis



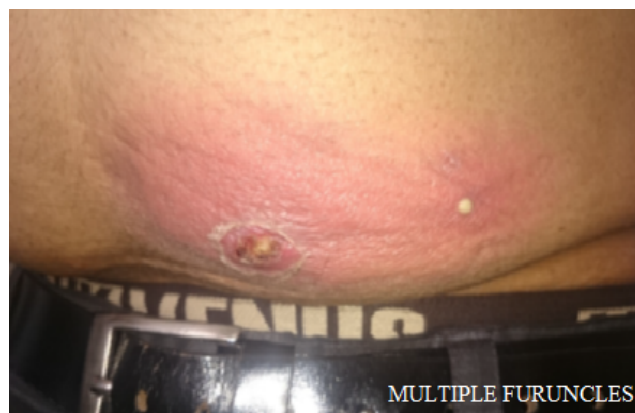CHRONIC FOLLICULITIS

Fig. 7: Chronic folliculitis



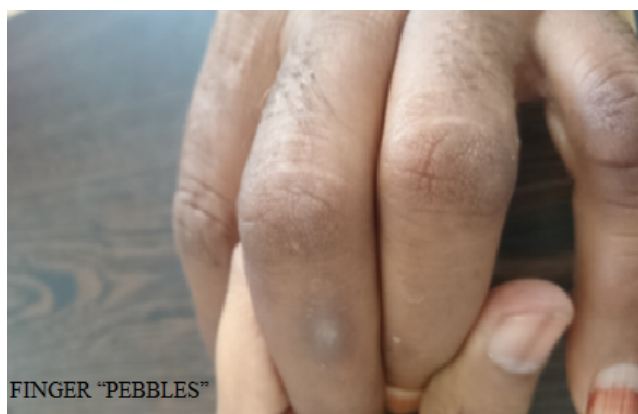CHRONIC ECZEMA

Fig. 5: Chronic eczema



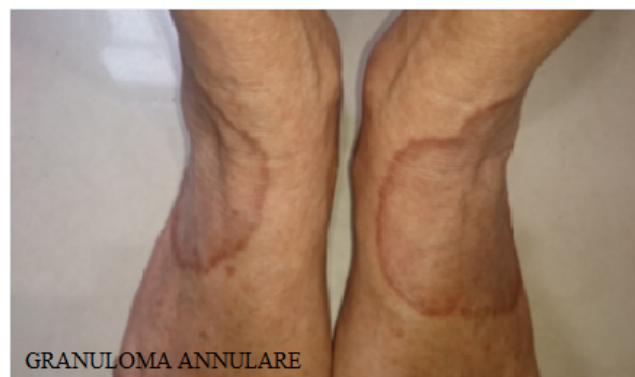MULTIPLE FURUNCLES

Fig. 8: Multiple furucles



FINGER "PEBBLES"

Fig. 6: Finger "PEBBLES"



GRANULOMA ANNULARE

Fig. 9: Granulomaannulare

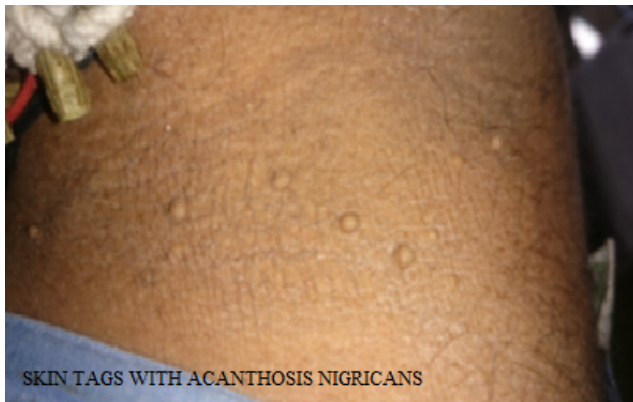

Fig. 10: Skin tags with acanthosis nigricans

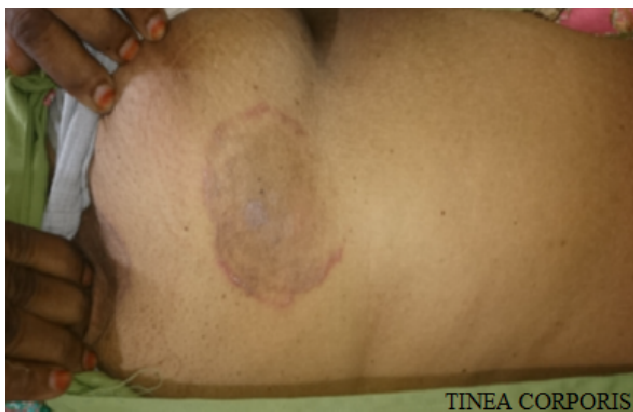

Fig. 11: Tinea corporis

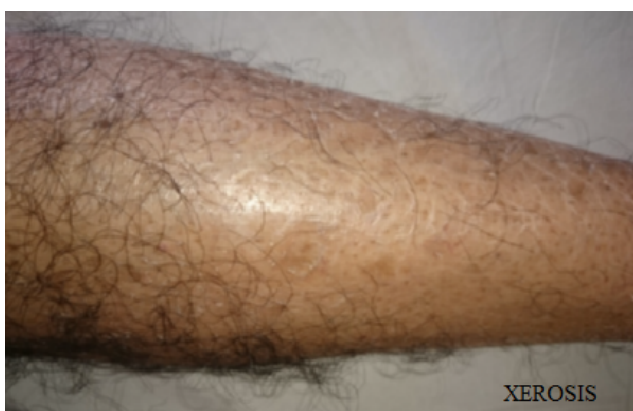

Fig. 12: Xerosis

This study, cutaneous manifestations were more commonly seen in uncontrolled diabetes mellitus type 2 (HbA1c >7gm). Commonest specific cutaneous manifestation observed was Acrochordon 34.5% which has similar frequency was reported by Kahana et al¹¹ 26.3% but Thappa et al¹² reported high incidence of acrochordon 62.8% which may be explained by the fact that they have more complicated and uncontrolled cases of diabetes mellitus. Zahra Azizian et al¹³ reported Xerosis and Androgenic Alopecia to be the two main common cutaneous disorders detected in their patients and, Roselind¹⁴ et al reported predomination of fungal infections in their study.

As we already discussed that it has been regarded as a sign of impaired glucose tolerance, DM, and increased cardiovascular (atherogenic lipid profile) risk. The next commonest skin manifestations observed in this study was skin Infections 69.75%. Bacterial infections was seen in 23.2% of patients which is similar to other studies. Thappa et al¹² and Bhat et al.⁷ Common infection observed was Dermatophytoses 19.2% and Onychomycosis 8.25%, similar frequency was reported observed by Rangunatha et Al¹⁵ 8.1% and Mahajan et al⁸ 11% for dematophytoses and Kuvandik et al¹⁶ 68.9% and Glaser et al¹⁷ 50% for onychomycosis respectively. In our study, Candidiasis was observed in 19%. Mahajan et al⁸ and Foss et al¹⁸ reported 10% and 12.9% respectively. Raghu et al¹⁹ found fungal infection more common in type 2 diabetics. The relative high prevalence of skin infections in this study could be due to poor hygienic conditions as well as uncontrolled diabetes mellitus which increases the risk of development of micro-angiopathy and related sequelae. Other than acrochordon and infection, Acanthosis nigricans 12.5% was also observed in our study which showed high percentage as compare to Bhat et al⁷ 5.3%, Mutairi et al²⁰ 4.7%, Mahajan et al⁸ 3% respectively.

In non-specific cutaneous manifestation we observed xerosis 64.75%, generalized pruritus 50%, which were statistically significant ($p < 0.5$) in uncontrolled diabetes type 2. Others less common skin manifestation were seborrheic keratosis 8.75%, lichen simplex chronicus 5%, lentigenes 4.5%, hyperpigmentation 4%, senile adenoma 3.75%, palmoplantar keratoderma 2.75%, eczema 1.75%, macular amyloidosis 1.75%, pigmented purpuric dermatosis 1.75%, melasma 1.75%, oral lichen planus 1.25%, nail dystrophy 1.25% in descending order.

Xerosis 64.75% accounted for the commonest skin manifestation in non-specific disorder of diabetic patients. Thappa et al¹² and Rangunatha et al¹⁵ reported 18.8% and 4.4% respectively. The reason for high prevalence of xerosis in our diabetic population is perhaps due to cold and dry climatic condition in this region for most of time in the year. The clinical observations are supported by objective findings of a reduced hydration state of the stratum corneum

and decreased sebaceous gland activity in patients with diabetes, without any impairment of the stratum corneum barrier function.¹⁵

Generalized pruritus 50% was next common skin manifestation in non specific disorder while Thappa et al¹² and Mahajan et al⁸ reported 15.2% and 10% respectively. There was statistically significant increased incidence of pruritus in diabetics than non-diabetics.²¹

The complications of Diabetes Mellitus Type-2 we were observed in this study like hypertension, diabetic retinopathy, nephropathy and peripheral neuropathy which were more in uncontrolled group, mostly as result of poor glycaemic control.

5. Summary and Conclusions

This was a detailed study to evaluate the pattern of cutaneous manifestation in 400 patients with type 2 diabetes which highlighted a number of observations. Cutaneous manifestations are quite common in uncontrolled (HbA1c>7gm) type 2 diabetes mellitus as compare to controlled group. Uncontrolled group is more prone to develop diabetic complication like hypertension, diabetic retinopathy and peripheral neuropathy etc.

It is concluded that, Diabetes mellitus Type-2 involves the skin quite often and whenever patients present with multiple skin manifestation and then diabetic status should be checked and controlled.

6. Conflicts of Interest

The authors declare that there are no conflicts of interest regarding the publication of this paper.

7. Source of Funding

None.

References

- Rosen J, Yosipovitch G. Skin Manifestations of Diabetes Mellitus. [Updated 2018 Jan 4]. In: Feingold K, Anawalt B, Boyce A, editors. Endotext [Internet]. South Dartmouth (MA): MDText.com, Inc.; 2000.
- Park K. Parks Textbook of Preventive and Social Medicine. 17th Edn. Jabalpur, India: M/S Bhanarsidas Bhanot Publishers; 2002. p. 294–8.
- Rao GS, Pai GS. Cutaneous manifestations of diabetes mellitus. *Indian J Dermatol Venereol Leprol.* 1997;63(4):232–4.
- Giligor RS, Lazarus GS. Skin manifestations of diabetes mellitus. In: Rifkin H, Raskin P, editors. Diabetes Mellitus. Brady co, Louana; 1981. p. 313–21.
- Urbach K, Lentz JW. Carbohydrate metabolism and the skin. *Arch Derm Syphilol.* 1965;52:301–4. doi:10.1001/archderm.1945.01510290006001.
- Khan M, Hashim MJ, King JK, Govender RD, Mustafa H, Al-Kaabi J, et al. Epidemiology of Type 2 Diabetes - Global Burden of Disease and Forecasted Trends. *J Epidemiol Glob Health.* 2020;10(1):107–11.
- Bhat YJ, Gupta V, Kudyar RP. Cutaneous manifestations of diabetes mellitus. *Int J Diab Dev Ctries.* 2006;26(4):153.
- Goyal A, Raina S, Kaushal SS, Mahajan V, Sharma NL. Pattern of cutaneous manifestations in diabetes mellitus. *Indian J Dermatol.* 2010;55(1):39–41. doi:10.4103/0019-5154.60349.
- Lugo-Somolinos A, Sánchez JL. Prevalence of dermatophytosis in patients with diabetes. *J Am Acad Dermatol.* 1992;26(3):408–10. doi:10.1016/0190-9622(92)70063-1.
- Ahmed K, Muhammad Z, Qayum I. Prevalence of cutaneous manifestations of diabetes mellitus. *J Ayub Med Coll Abbottabad.* 2009;21(2):76–9.
- Kahana M, Grossman E, Feinstein A, Ronnen M, Cohen M, Millet MS, et al. Skin tags: a cutaneous marker for diabetes mellitus. *Acta Dermatovenereologica.* 1987;67(2):175–7.
- Thappa DM. Skin tags as markers of diabetes mellitus: an epidemiological study in India. *J Dermatol.* 1995;22(10):729–31.
- Azizian Z, Behrangi E, Hasheminasabzavareh R, Kazemlo H, Esmaeeli R, Hassani P. Prevalence Study of Dermatologic Manifestations among Diabetic Patients. *Adv Prev Med.* 2019;doi:10.1155/2019/5293193.
- Rosling S, Muhammed K, and KGSK. Cutaneous manifestations in patients with type 2 diabetes mellitus and normal controls. *J Skin Sex Transm Dis.* 2020;2(1):26–30.
- Ragunatha S, Anitha B, Inamadar AC, Palit A, Devarmani SS. Cutaneous disorders in 500 diabetic patients attending diabetic clinic. *Indian J Dermatol.* 2011;56(2):160–4. doi:10.4103/0019-5154.80409.
- Kuvandik G, Çetin M, Genctoy G, Horoz M, Duru M, Akcali C, et al. The prevalence, epidemiology and risk factors for onychomycosis in hemodialysis patients. *BMC Infect Dis.* 2007;7(1):1–5.
- Glaser HJ. The effectiveness of laser treatments for onychomycosis in adults in the community: a systematic review thesis. *J Foot Ankle Res.* 2015;doi:10.1186/1757-1146-8-S2-O15.
- Foss NT, Polon DP, Takada MH, Foss-Freitus ML. Skin lesions in diabetic patients. *Rev Saudi Publica.* 2005;39(9):677–82.
- Raghu TY, Vinayak V, Kanthraj GR, Girisha BS. Study of cutaneous manifestations of diabetes mellitus. *Indian J Dermatol.* 2004;49(2):73–5.
- Al-Mutairi N, Eassa BI, Da AR. Clinical and mycologic characteristics of onychomycosis in diabetic patients. *Acta Dermatovenereologica Croatica.* 2010;18(2):84–91.
- Brickman WJ, Huang J, Silverman BL, Metzger BE. 2010.

Author biography

Anurag Bareth, Resident

Charul Agrawal, Resident

Kalpna Gupta, Professor and HOD

Cite this article: Bareth A, Agrawal C, Gupta K. Different patterns of cutaneous manifestation of diabetes mellitus type-2 observed in tertiary care centre of South West Rajasthan. *IP Indian J Clin Exp Dermatol* 2021;7(4):341-346.