



Case Report

A case of Pemphigoid gestationis- Successfully managed with good outcome

Shitij Goel^{1,*}, Azra Ferheen Chaudhary¹, Mansi Bansal¹, Ruchi Srivastava², Mayuri Ahuja²

¹Dept. of Dermatology, School of Medical Sciences and Research, Sharda University, Greater Noida, Uttar Pradesh, India

²Dept. of Obstetrics and Gynecology, School of Medical Sciences and Research, Sharda University, Greater Noida, Uttar Pradesh, India



ARTICLE INFO

Article history:

Received 22-02-2022

Accepted 02-03-2022

Available online 30-03-2022

Keywords:

Pemphigoid gestationis

Oral prednisolone

Pregnancy outcome

ABSTRACT

State of pregnancy can manifest with various physiological and pregnancy specific dermatoses. The physiological changes include pigmentary, vascular and connective tissue changes. The specific dermatoses includes Atopic Eruption of Pregnancy, Polymorphic eruption of Pregnancy, Pemphigoid Gestationis and Intrahepatic Cholestasis of Pregnancy.

Pemphigoid gestationis (PG) is a rare autoimmune bullous disease exclusively associated with pregnancy. It develops during the third trimester of pregnancy and is associated with maternal and foetal complications. Here, we report a case of PG which was successfully managed with systemic steroids with a favourable outcome.

This is an Open Access (OA) journal, and articles are distributed under the terms of the [Creative Commons Attribution-NonCommercial-ShareAlike 4.0 License](https://creativecommons.org/licenses/by-nc-sa/4.0/), which allows others to remix, tweak, and build upon the work non-commercially, as long as appropriate credit is given and the new creations are licensed under the identical terms.

For reprints contact: reprint@ipinnovative.com

1. Introduction

State of pregnancy can manifest with various physiological and pregnancy specific dermatoses. The physiological changes include pigmentary, vascular and connective tissue changes. The specific dermatoses includes Atopic Eruption of Pregnancy, Polymorphic eruption of Pregnancy, Pemphigoid Gestationis and Intrahepatic Cholestasis of Pregnancy.

Pemphigoid gestationis (PG) is a rare autoimmune bullous disease exclusively associated with pregnancy. It develops during the third trimester of pregnancy and is associated with maternal and foetal complications. Here, we report a case of PG which was successfully managed with systemic steroids with a favourable outcome.

2. Case Report

A 25 year old female, at 32 weeks gestation in her fourth pregnancy presented to the outpatient dermatology department with intensely itchy pruritic eruption since 12 days. The lesions were preceded by generalised itching, predominantly intense on her abdomen. Following which she developed multiple erythematous, oedematous plaque, which first appeared periumblically, then progressed to involve her trunk, arms, legs and face. The lesions then developed a central dusky hue and peripheral rim of vesicles.

The patient has been married for 5 years and previous pregnancies resulted in a full term LSCS in 2017, a missed abortion in 2018 at 12 weeks, and another spontaneous abortion at 8 weeks in the same year.

She had no family history of dermatological conditions or autoimmune diseases. There was no history of similar complaints in her previous pregnancy, no history of systemic illness, HSV infection and no history of drug intake other

* Corresponding author.

E-mail address: drgoelderma@gmail.com (S. Goel).

than multivitamins.

On cutaneous examination, multiple well defined, erythematous, annular plaques of size ranging from 2 – 6 cm diameter, with central dusky hue and peripheral rim of vesicles were present predominantly on abdomen, upper chest, back, arms, thighs, palm, soles and face.(Figure 1) Mucosal involvement was not present.

Routine haematological and biochemical tests revealed dimorphic anaemia. Other parameters like bile acids, renal function were normal. Histopathological examination displayed subepidermal bulla with plasma cells and few eosinophils in the bullous cavity. Dermis showed moderate degree of perivascular infiltration by lymphocytes and eosinophils. On Direct Immunofluorescence, a thin linear deposit of IgG and C3 was seen at basement membrane zone. Based on the clinico-pathological correlation, diagnosis of Pemphigoid gestationis was made.

Patient was initially started on oral Prednisolone 30mg once daily, levocertizine 5mg twice daily with topical mometasone furoate 0.1% to be applied twice daily over the lesions. After 5 days of follow-up, patient presented with an increase in size and no. of lesions, with increase in severity of pruritis.(Figures 2 and 3)

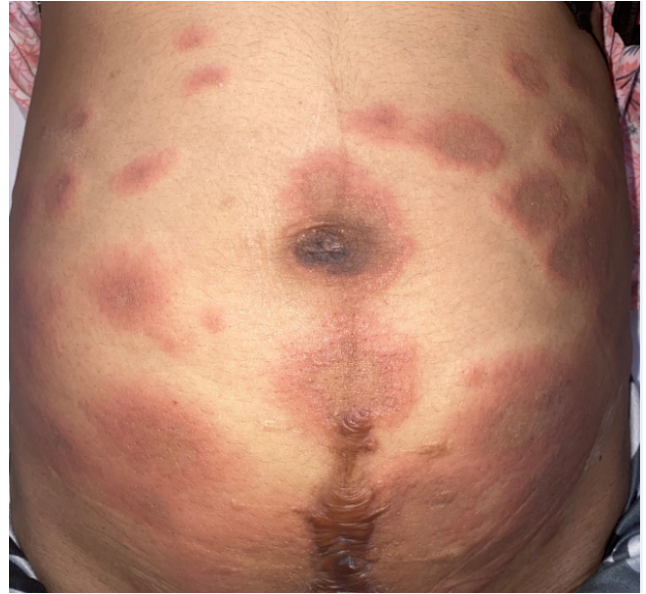

Fig. 2: Enlargement of lesions after 3 days

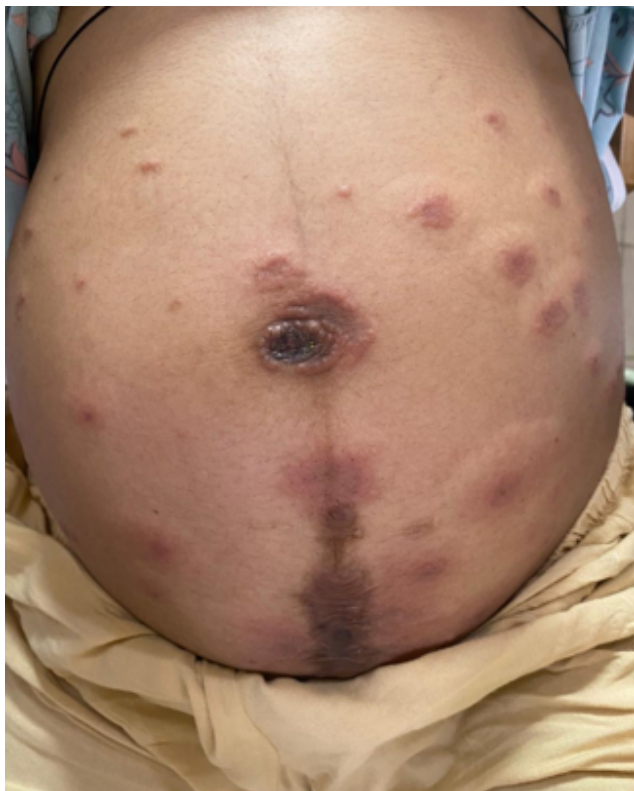

Fig. 1: Erythematous annular plaques with periumbilical involvement at the time of first presentation

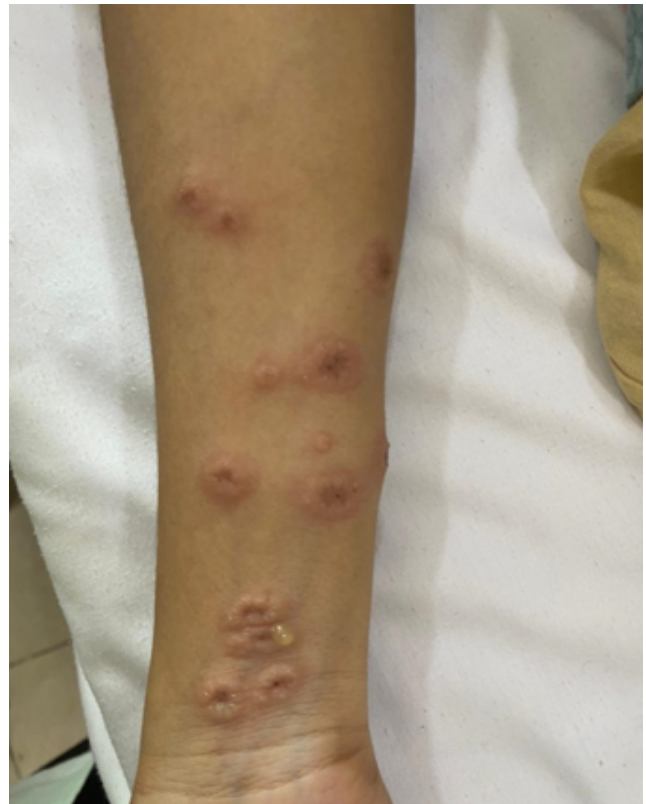

Fig. 3: Erythematous annular plaques with vesicles at day 3 overvolar aspect of forearm

The prednisolone dose was then increased to 40mg once daily, and first generation antihistamine, oral

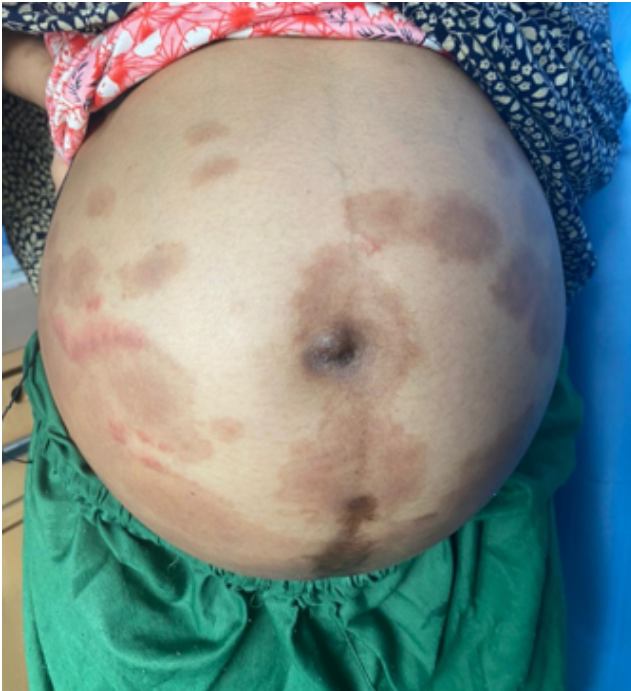


Fig. 4: Marked improvement in lesions seen after oral prednisolone (40mg)

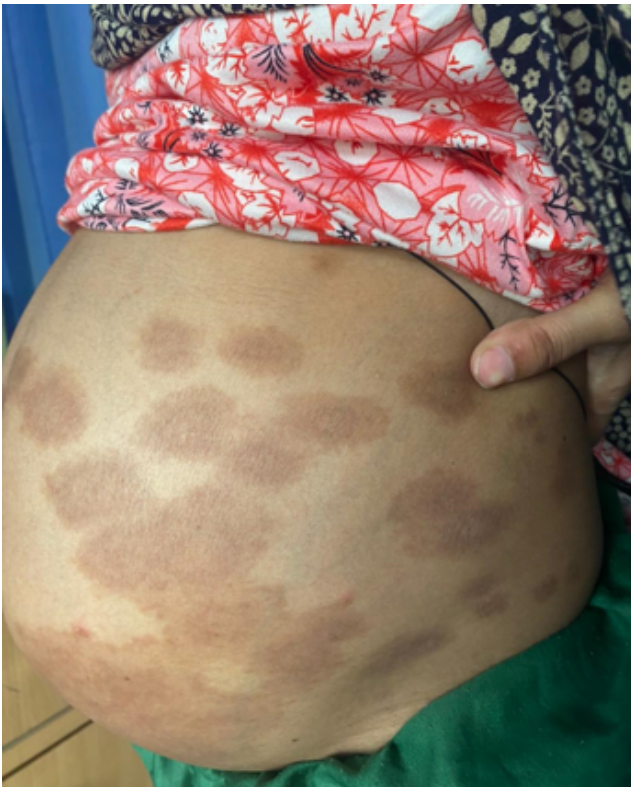

Fig. 5: Marked improvement in lesions seen after oral prednisolone (40mg)

chlorpheniramine maleate 4mg thrice daily was added to the treatment.

On next follow-up, patient showed improvement in lesion as well as pruritis. (Figures 4 and 5) The steroid was tapered to 30mg, which was continued till delivery.

At each dermatology consultation visit, patient was followed up and evaluated in obstetrics department of our hospital to check for foetal well-being.

Elective caesarean section was planned at 36 weeks gestation, indication being tenderness in previous LSCS scar. A rescue dose of Injection hydrocortisone 100mg i.v. was given prior to the surgery.

Pregnancy Outcome - Patient delivered a healthy male child. No skin lesions were present on the body of child. The patient and new born child were followed up regularly in post-partum period. A week after delivery, prednisolone was gradually tapered. Neither the patient had any recurrence of disease nor did the child develop any cutaneous vesicular lesions. Follow up was done at monthly interval for the next 6 months and the patient reported no recurrence of disease.

3. Discussion

Pemphigoid gestationis, is a rare autoimmune sub-epidermal bullous dermatoses of pregnancy which causes severe distress to the pregnant women. Intense itching is a prominent feature. The patient may present initially with pruritic urticarial papules, which later transform to vesicles, and finally, large tense bullae. The periumbilical involvement is characteristic which differentiates it from other pregnancy specific dermatoses. It mainly affects multiparous women in their second or third trimester of pregnancy, but onset in the first trimester or postpartum period has also been reported.^{1,2} Classically, there is a period of decreased severity or remission during the last 6 weeks of pregnancy, followed by a flare immediately after delivery. Recurrences in subsequent pregnancies may occur, however, skipped pregnancies have also been reported.

PG can cause fetal complications like - abortion, prematurity, small-for-date babies. Neonatal PG can occur in 3% of neonates of mothers with PG due to transfer of antibodies across the placenta.

In our patient features favouring the diagnosis included - intense itching, presence of vesicle and periumbilical involvement. Features different from classical PG included - presence of lesions on face and palms. Bullous lesions were not seen. Our diagnosis was confirmed by perilesional skin biopsy and DIF.

Use of high dose prednisolone is sometimes associated with adverse effects like pre eclampsia during pregnancy and chance of cleft palate, pre term, low birth weight in neonate. However, the data are conflicting, and it is unknown to what extent maternal disease itself could contribute to the adverse effects.³ In our patient Prednisolone was given considering maternal and foetal

benefits outweighing the risks.

Various case studies have showed the role of alternate steroid sparing treatment options in unresponsive cases. These includes Azathioprine, plasma exchange and intravenous immunoglobulin. IVIG has a good safety profile for the mother and the fetus.⁴

Other important factors in management included regular check-ups with obstetrician and neonatologist during the entire course of treatment. In addition, proper counselling also has an important role. All patients have to be counselled about foetal prognosis and the possibility of relapse after delivery, relapse with the use of hormonal contraceptives, and the risk of relapse in subsequent pregnancies.

We are reporting this case, in view of rarity of presentation, to emphasize the importance of high degree of suspicion and confirmation with DIF and timely Institution of oral corticosteroids. Also, we would like to emphasize regular collaboration of dermatologists and obstetricians so as to have, a favourable mother and child outcome.

4. Conflict of Interest

The authors declare that there is no conflict of interest.


5. Source of Funding

None.

References

1. Fong M, Gandhi GR, Gharbi A. Pemphigoid Gestationis. [Updated 2021 Mar 21]. In: StatPearls [Internet]. Treasure Island (FL): StatPearls Publishing; 2021.
2. Sävervall C, Sand FL, Thomsen SF. Pemphigoid gestationis: current perspectives. *Clin Cosmet Investig Dermatol*. 2017;10:441-9. doi:10.2147/CCID.S128144.
3. Bandoli G, Palmsten K, Smith C, Chambers CD. A Review of Systemic Corticosteroid Use in Pregnancy and the Risk of Select Pregnancy and Birth Outcomes. *Rheum Dis Clin North Am*. 2017;43(3):489-502. doi:10.1016/j.rdc.2017.04.013.
4. Cobo MF, Santi CG, Maruta CW, Aoki V. Pemphigoid gestationis: clinical and laboratory evaluation. *Clinics*. 2009;64(11):1043-7. doi:10.1590/S1807-59322009001100002.

Author biography

Shitij Goel, Professor  <https://orcid.org/0000-0001-5186-507X>

Azra Ferheen Chaudhary, Resident  <https://orcid.org/0000-0001-7497-5212>

Mansi Bansal, Senior Resident

Ruchi Srivastava, Professor

Mayuri Ahuja, Assistant Professor

Cite this article: Goel S, Chaudhary AF, Bansal M, Srivastava R, Ahuja M. A case of Pemphigoid gestationis- Successfully managed with good outcome. *IP Indian J Clin Exp Dermatol* 2022;8(1):51-54.