

Content available at: <https://www.ipinnovative.com/open-access-journals>

IP Indian Journal of Clinical and Experimental Dermatology

Journal homepage: www.ijced.org/

Case Series

Optimum fluence of Q-switched 1064nm laser in lip melanosis

Reshmi Subramaniam^{1,*}, Vani Vasanth², Byalekere Shivanna Chandrasekhar²¹Dept. of Dermatology, SUT Academy of Medical Sciences, Trivandrum, Kerala, India²Dept. of Dermatology, CUTIS Academy of Cutaneous Sciences, Bangalore, Karnataka, India

ARTICLE INFO

Article history:

Received 27-01-2022

Accepted 08-02-2022

Available online 30-03-2022

Keywords:

Lip melanosis

1064nm Q-switched Nd-YAG laser

ABSTRACT

Background: Pink lips have always been considered an attribute of a beautiful face. The content of lip cosmetics is cause for concern as they are easily ingested. Hence, the need for lip-lightening by other means, like lasers. We aimed to find the efficacy and optimum fluence of the Qs-Nd :YAG 1064 nm laser in reducing lip melanosis of unknown cause.

Materials and Methods: A prospective Case series study was carried out. Fifteen consecutive patients with lip melanosis of unknown etiology, were selected. Patients were advised to undergo Lip toning with Spectra laser (Qs Nd:YAG 1064 nm) every 2 weeks, for atleast 8-10 sessions. Before each session, photographs and Digital dermoscopy (polarized,20x) pictures were taken to assess outcome. Lip pigmentation and erythema were assessed quantitatively using skin colorimetric device called 'Dermacatch'.

Results: Ten patients completed atleast 5 sessions. Of this, four patients completed 7-8 sessions and showed significant clinical improvement. Dermoscopic changes in patients after treatment are 'hazy whitening' of areas which were 'velvety' in color. The four patients who showed clinical improvement also showed dermoscopic changes.

Discussion: Lip pigmentation improvement is slow and fluence-dependent and may need more than five sessions. The effective fluence for lip lesions is 3 to 4 times that for facial melanosis. Patients maybe started on higher fluences depending on tolerance. Dermoscopic changes precede clinical improvement.

Conclusion: Lip pigmentation was found to respond to high fluences only. Dermoscopic changes can give an early indication of possible clinical improvement that can be expected. Skin colorimetry device did not correlate well with clinical features with respect to melanosis of lip.

This is an Open Access (OA) journal, and articles are distributed under the terms of the [Creative Commons Attribution-NonCommercial-ShareAlike 4.0 License](https://creativecommons.org/licenses/by-nc-sa/4.0/), which allows others to remix, tweak, and build upon the work non-commercially, as long as appropriate credit is given and the new creations are licensed under the identical terms.

For reprints contact: reprint@ipinnovative.com

1. Introduction

Pink lips, from the ancient times, have been considered one of the essential attributes of a beautiful face. The fact that coloring substances have been used to enhance appearance of the lips by the Sumerians dating back as far as 7000 BC is testament to this. The practice was continued over generations of civilizations from Egyptians to Greeks and Romans to the present-day.¹

Physiologic pigmentation of the lips is most commonly seen in Asian, African-American, and Hispanic populations and in people of Mediterranean descent and manifests in the first two decades of life.² Women normally resort to camouflaging the color of the lip with 'balms', 'lip sticks' or 'lip glosses'. Lip balms help moisturize lips, while lipsticks give desired color, hydration and sun protection. The content of these cosmetics, since they are being used around the mouth, is cause for concern as they are easily ingested. Some studies conducted on the amount of trace metals in lip sticks in different countries found quantities of heavy metals like arsenic and lead albeit within acceptable limits set by

* Corresponding author.

E-mail address: drreshmis@gmail.com (R. Subramaniam).

FDA.^{3,4} Another study showed high lead and cadmium content.⁵ Thus, the cumulative health effects from exposure to heavy metals over a long period of time, especially in women cannot be easily ignored, as metals like lead easily cross placenta and also into breast milk.⁴

Hence, recent awareness regarding hazards of daily cosmetics and their systemic absorption opens up a pressing need to get rid of lip pigmentation through other means, like lasers or chemical peels or topical lip lightening agents, rather than mere camouflaging. The desire among men and women to get naturally pink or unpigmented lips without cosmetics, can never be beaten. The different lasers evaluated for different types of lip pigmentation in Asians include Pulsed non-Q-switched Ruby laser,⁶ Q-switched Alexandrite laser,⁷⁻⁹ Qs-Nd: YAG 532 nm,¹⁰ Qs-Nd: YAG 1064 nm,¹¹ and Diode laser.¹²

Laser toning using low-fluence, large spot size, multiple-pass Q-switched laser is a popular treatment among Asians for skin rejuvenation and lightening. Qs-Nd :YAG 1064 nm remains the safest pigmentary laser for Indian skin, due to its low affinity for melanin and less epidermal absorption. The very same reasons necessitate more number of sessions.^{13,14} Our aim was to find the efficacy of the Qs-Nd :YAG 1064 nm laser in reducing lip melanosis of unknown cause and the optimum fluence at which effective pigment dilution occurs in lips.

2. Materials and Methods

Materials and Methods: A prospective Case series study was carried out. 15 consecutive patients with complaints of lip melanosis of unknown etiology, were selected for the study. Detailed history and cutaneous examination was done and data tabulated into a case proforma. Patients were advised to undergo Lip toning with SPECTRA laser (Qs Nd:YAG 1064 nm) every 2 weeks, for at least 8-10 sessions.

Fluences ranging from 1.2J/cm² upto 4.2 J/cm² were used, increased by 0.1 to 0.4 J/cm² at every visit, depending on tolerance and adherence to lip care regimen. Spot sizes varied between 6-8 mm and frequency used between 5-10 Hz. Three passes were given.

Before each session, photographs and Digital dermoscopy (polarized, 20x) pictures were taken to assess outcome.

Lip pigmentation and erythema were assessed quantitatively using Skin colorimetric device called 'Dermacatch', a new skin colorimeter covering the visible light spectrum.

Patients with smoker's lip melanosis, history of herpes labialis, vitiliginous or keloidal tendency were excluded from study.

3. Results

1. Of the 15 patients with lip melanosis, 10 were female and F:M ratio was 2:1. Six patients dropped out of study of which five dropped out before completing five sessions.. One patient who dropped out after 6 sessions cited inadequate response as the reason. Another patient complained of increased pigmentation which could not be corroborated by comparing pre and post photographs. The rest of the patients who dropped out were not motivated to complete all the sessions. Of the 15 patients, 10 patients completed at least five sessions.
2. Four patients showed clinical improvement and had completed 7-8 sessions
3. One patient showed marked improvement at 4.2 J/cm² at end of 7 sessions, while Moderate improvement seen in one patient at the end of 8th session and at maximum fluence of 4J.
4. Two patients showed mild improvement (Maximum fluence reached was 3.6J/cm² and 4J/cm²) at 7th and 8th sessions respectively.
5. One patient complained of increased melanosis as reason to drop out from study
6. Two patients complained of pain at 2.4J and 3.4 J respectively
7. Dermoscopic changes in patients after treatment seemed to be 'hazy whitening' of previous areas which were 'velvety' in color and corresponded to areas of visible clinical improvement.
8. The six patients who showed changes on dermoscopy included the four patients who also showed some clinical improvement.

Dermoscopic changes were seen in most of the patients who reached higher fluences (>3.4J/cm²) and completed at least 6 sessions (six patients). Dermoscopic changes included disappearance of previous dark spots and 'hazy whitening' of previously pigmented areas. Dermacatch values did not show results consistent with gross and dermoscopic changes in all patients. Lip care with regular use of lip balms was adhered to by six out of 15 patients only. But this did not seem to affect tolerance to higher fluences.




Fig. 1: Patient 1: Marked improvement of lip melanosis in a patient after 7 sessions of 4.2J/cm² fluence.

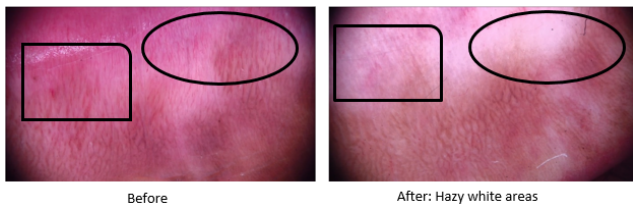

Fig. 2: Dermoscopy of Patient-1

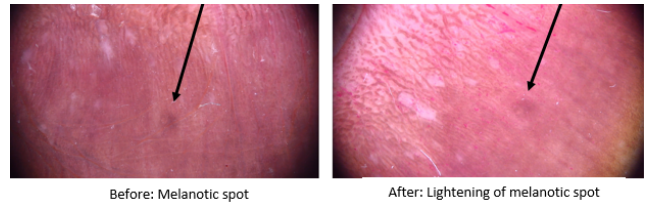


Fig. 8: Dermoscopic pictures of patient 3

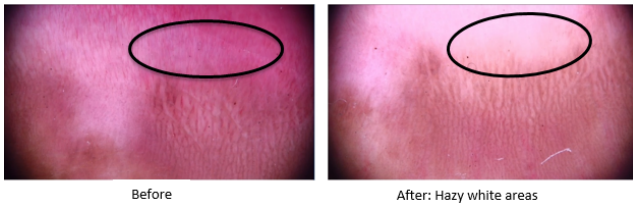


Fig. 3: Dermoscopy of Patient 1

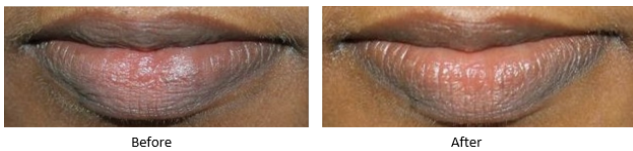


Fig. 4: Patient-2: Visible lightening of lip after 7 sessions, maximum fluence reached was 3.4J/cm²

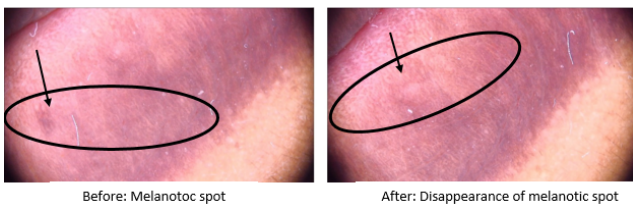

Fig. 5: Dermoscopic pictures of patient 2-clearance of melanotic spot

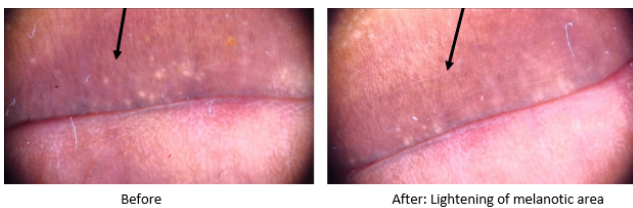


Fig. 6: Patient 2-Lightening of melanotic areas

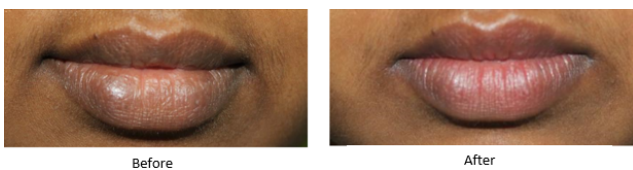


Fig. 7: Visible lip lightening in patient-3 after 8 sessions, maximum fluence 4J/cm²

4. Discussion

Although not to the same extent as women, men also seemed to be seeking dilution of lip pigmentation. None of our patients admitted to the habit of smoking, yet were often asked if they smoked. This was a major reason for more men and women coming forward to get rid of pigmentation of lips.

Some patients(3) had a tendency to drop out within the first 2 to 3 sessions of laser, though the same may not be seen when undergoing laser for other reasons like acne scars or facial pigmentation. The reason maybe slow improvement of lip pigmentation and the fact that it can be easily camouflaged by quality make-up etc. Remarkable improvement seen in two patients who reached higher fluence highlights the fact that pigment dilution is fluence-dependent and also dependent on number of sessions completed. The effective fluence for lip lesions seem to be at least 3 to 4 times that used for facial melasma or rejuvenation. There may not be a need to gradually increase from low to high fluences and patients maybe started and continued on higher fluences if they can tolerate it. Another study also documented results from a single fluence setting.¹¹ To find out optimal fluence in SPECTRA machine for lip melanosis and also to scrutinize the possible adverse effects on lips from such high fluences, more patients with lip melanosis need to be included. Dermoscopic aspects of labial pigmentation and changes with laser need further evaluation through more studies and correlation with histopathology where possible.

There was lack of consistency between values of lip pigmentation and erythema obtained from skin colorimetric device (called Dermacatch) and what was evident on photographs and dermoscopy. This was in contrast to another study which showed higher specificity and reproducibility in Dermacatch device as compared to Mexameter.

5. Conclusion

Though Laser toning for facial pigmentation and skin rejuvenation has been quite popular among Asians, lip melanosis does not seem to respond at the same fluence as used on face. Lip pigmentation seems to respond to maximum fluence at least 3 to 4 times that used for facial pigmentation. In most cases, Dermoscopic changes

maybe seen before effects become visible to the eye. Skin colorimetry did not help in detecting subclinical effects of laser on pigmentation.

6. Conflict of Interest

The authors declare they have no conflict of interest.


7. Source of Funding

No financial support was received for the work within this manuscript.


References

1. Draelos ZD. Cosmetics and skin care products. A historical perspective. *Dermatol Clin*. 2000;18(4):557-9. doi:10.1016/s0733-8635(05)70206-0.
2. Vachiramon V, Mcmichael AJ. Approaches to the evaluation of lip hyperpigmentation. *Int J Dermatol*. 2012;51(7):761-70. doi:10.1111/j.1365-4632.2011.05272.x.
3. Piccinini P, Piecha M, Torrent SF. European survey on the content of lead in lip products. *J Pharm Biomed Anal*. 2013;76:225-33. doi:10.1016/j.jpba.2012.11.047.
4. Al-Saleh I, Al-Enazi S. Trace metals in lipsticks. *Toxicol Environ Chem*. 2011;93(6):1149-65. doi:10.1080/02772248.2011.582040.
5. Nkansah MA, Owusu-Afriyie E, Opoku F. *J Consum Prot Food Saf*. 2018;13:367-367.
6. Al-Saleh I, Al-Enazi S, Hanada K, Baba T, Sasaki C, Hashimoto I. Successful Treatment of Mucosal Melanosis of the Lip with Normal Pulsed Ruby Laser. *The Journal of Dermatology*. 1996;93(6):263-266.
7. Rijhwani M, Manchanda Y. Q-switched Alexandrite laser in the treatment of pigmentation of lips in Laugier-Hunziker syndrome. *Gulf J Dermatol Venereol*. 2016;23(2):41-5.
8. Zuo YG, Ma DL, Jin HZ, Liu YH, Wang HW, Sun QN, et al. Treatment of Laugier-Hunziker syndrome with the Q-switched alexandrite laser in 22 Chinese patients. *Arch Dermatol Res*. 2010;302(2):125-30. doi:10.1007/s00403-009-0930-1.
9. Papadavid E, Walker NP. Q-switched Alexandrite laser in the treatment of pigmented macules in Laugier-Hunziker syndrome. *J Eur Acad Dermatol Venereol*. 2001;15(5):468-9. doi:10.1046/j.1468-3083.2001.00322.x.
10. Kunachak S, Kunachakr S, Kunachakr S, Leelaudomlipi P, Wongwaisayawan S. An Effective Treatment of Dark Lip by Frequency-Doubled Q-Switched Nd:YAG Laser. *Dermatologic Surg*. 2001;27(1):37-40.
11. Limpjaroenviriyakul N, Jurairattanaporn N, Kamanamool N, Rojhirunsakool S, Kanokrunsee S, Udompataikul M, et al. Low-fluence Q-switched Nd:YAG 1064-nm laser versus Q-switched Nd:YAG 532-nm laser in the treatment of hyperpigmented lips: a prospective, randomized, controlled, evaluator-blinded trial. *Lasers Med Sci*. 2020;35(1):165-71. doi:10.1007/s10103-019-02814-4.
12. Iyer V, Farista S. Management of hyperpigmentation of lips with 940 nm diode laser: two case reports. *Int J Laser Dent*. 2014;4(1):31-8. doi:10.5005/jp-journals-10022-1052.
13. Acton A. Lasers in Medicine. In: A. Acton, ed., Chapter 1. Atlanta: Scholarly Editions; 2019. p. 1.
14. Baquie M, Kasraee B. Discrimination between cutaneous pigmentation and erythema: comparison of the skin colorimeters Dermacatch and Mexameter. *Skin Res Technol*. 2017;20(2):218-27.

Author biography

Reshmi Subramaniam, Assistant Professor  <https://orcid.org/0000-0001-6862-7641>

Vani Vasanth, Senior Consultant

Byalekere Shivanna Chandrasekhar, Medical Director and Chief Dermatologist  <https://orcid.org/0000-0001-9593-8875>

Cite this article: Subramaniam R, Vasanth V, Chandrasekhar BS. Optimum fluence of Q-switched 1064nm laser in lip melanosis. *IP Indian J Clin Exp Dermatol* 2022;8(1):67-70.