

A study of cutaneous manifestations of chronic pulmonary diseases among patients attending a tertiary care hospital

Arjun Ajay Shankar¹, Malcolm Pinto^{2,*}, Deepu Changappa Cheriamane³, Manjunath Shenoy M⁴

¹Junior Resident, ^{2,3}Assistant Professor, ⁴HOD & Professor, Yenepoya Medical College, Mangalore

***Corresponding Author:**

Email: malcolmpinto@gmail.com

Abstract

Background: Cutaneous manifestations are frequently associated with pulmonary diseases and vice versa.

Aim: To study the frequency of cutaneous manifestations of pulmonary disease in patients attending our hospital.

Methods: A total of 100 patients, after confirming the clinical diagnosis of pulmonary disease among patients attending the Respiratory Medicine department were included in our study. All the cutaneous manifestations were noted and were further categorised into disease specific findings, nail findings, oral cavity findings, pigmentary changes, infections, age related changes and miscellaneous findings.

Results: Cutaneous manifestations were observed in all 100 cases studied. Xerosis (48), clubbing (43), onychorrhexis (35), hyperkeratosis of bilateral elbows (33) and onychomycosis (19) were the common findings noted.

Conclusion: High frequency of various cutaneous manifestations was observed in the study group. Prompt identification of cutaneous changes followed by the appropriate investigations and referrals may help us in the comprehensive management and care of patients with pulmonary disease.

Key words: Cutaneous, Pulmonary, Xerosis, COPD, Hyperkeratosis

Introduction

Dermatologic disease is frequently associated with internal manifestations.¹ Cutaneous manifestations are frequently associated with pulmonary diseases and vice versa.² Pulmonary conditions can be life threatening, and early detection and treatment may have an impact on the patient's quality of life. Better understanding of the common and rare cutaneous manifestations of pulmonary diseases enables physicians to enhance their clinical proficiency.³ The first review of the various cutaneous findings of chronic lung diseases was published in 1991.⁴ Since then, the literature review related to this study has been lacking. This prompted us to conduct this study at our institution.

Materials and Methods

One hundred patients with chronic pulmonary disease referred from the Department of Respiratory Medicine over a period of 6 months were included in our epidemiological study. Detailed history was recorded and meticulous clinical examination was carried out. Diagnosis of pulmonary disease was made based on the clinical features and was supplemented by necessary investigations if required. Only patients with established pulmonary disease were taken up for the study. All cutaneous signs were recorded using a standard proforma and were further categorised into disease specific findings, nail findings, oral cavity findings, pigmentary changes, infections, age related changes and miscellaneous findings.

Results

Out of the 100 patients who were studied, 67 had chronic obstructive pulmonary disease (COPD), 16 had pulmonary tuberculosis, 11 had bronchial asthma, 3 had interstitial lung disease, 2 had bronchogenic carcinoma and 1 was diagnosed with aspergilloma. After obtaining consent, all patients in the study group (69 men and 31 women) were subjected to in detail cutaneous examination. The mean age of the patients studied was 68.4 years which ranged from 45 to 82 years. The common dermatological manifestations noted were xerosis (Fig. 1), clubbing (Fig. 2), onychorrhexis (Fig. 3), hyperkeratosis of B/L elbows (Fig. 4), onychomycosis (Fig. 5) and tobacco nail stains (Fig. 6). All the cutaneous manifestations noted have been summarised in Table 1 in decreasing order of frequency. Age related manifestations like seborrheic keratosis, cherry angioma, asteatotic eczema, senile purpura, senile comedones, and idiopathic guttate hypomelanosis were not included in the findings in Table 1 as these findings are common among people of this age group and may not be because of the underlying pulmonary disease.

Table 1: Frequency of different cutaneous manifestations noted

Findings	No. of patients
Xerosis	48
Clubbing	43
Onychorrhexis	35
Hyperkeratosis of bilateral elbows	33
Onychomycosis	19
Tobacco nail stains	15
Dermatophytosis	12
Seborrheic dermatitis	8
Subungual hyperkeratosis	6
Beau's line	4
Oral pigmentation	4
Pigmentary changes (melasma, stasis pigmentation, schamberg's disease, vitiligo and freckles)	15

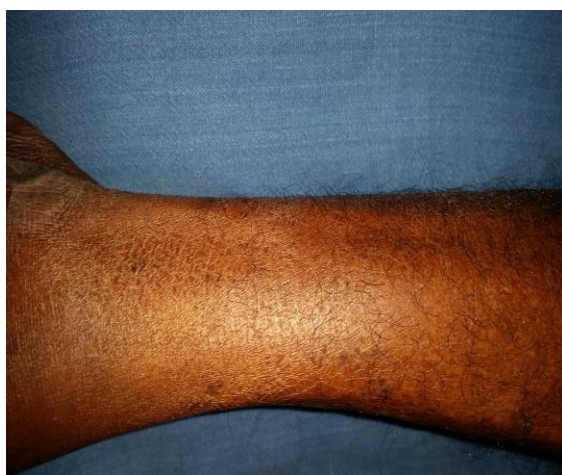

Fig. 1: Xerosis

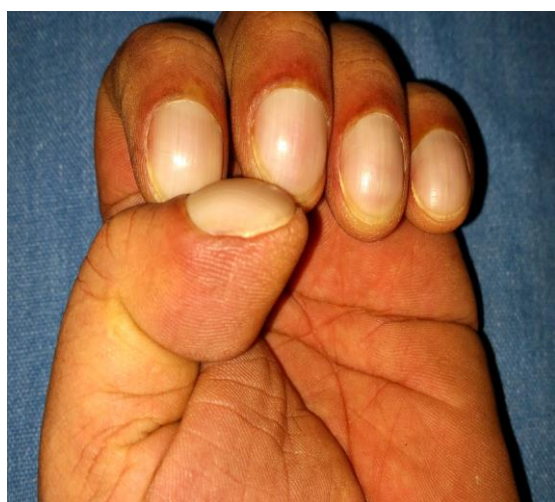

Fig. 2: Clubbing

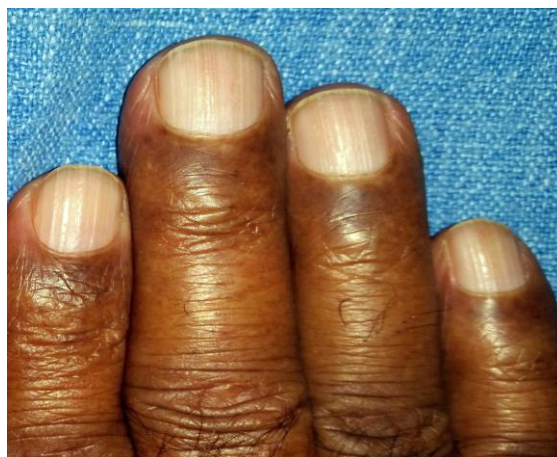

Fig. 3: Onychorrhexis

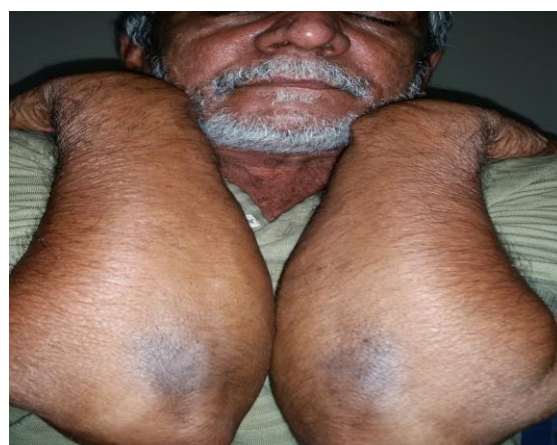

Fig. 4: Hyperkeratosis of Bilateral elbows

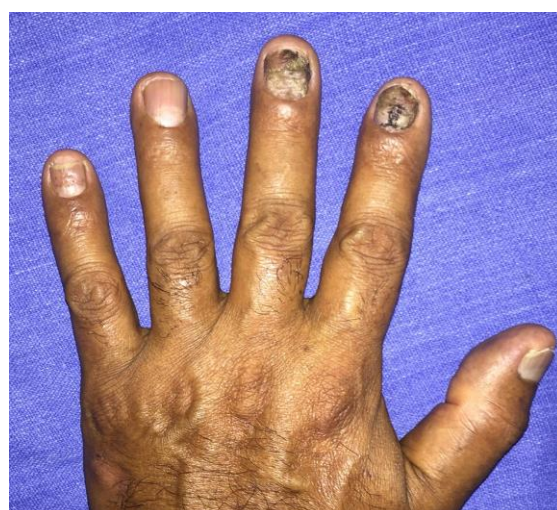


Fig. 5: Onychomycosis

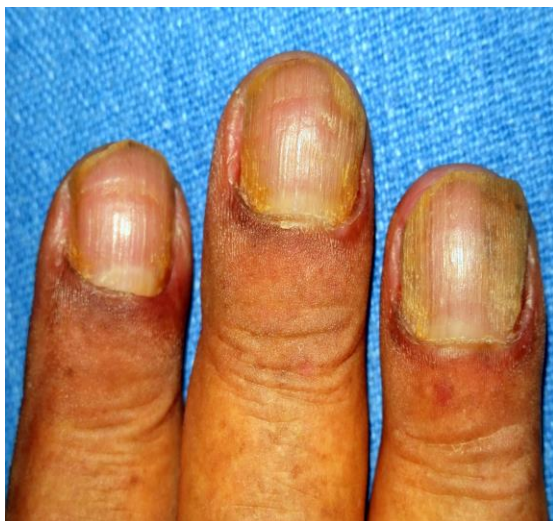

Fig. 6: Tobacco nail stain

Discussion

The present study found xerosis to be the common manifestation among patients with chronic pulmonary diseases. Xerosis was noted in 48% of the patients examined and was comparatively higher than other findings observed in our study. Higher incidence of xerosis was found in a study done by Zemstov A and Shahar J.⁵ In this study, nail changes was the most common manifestation noted in chronic pulmonary diseases. Clubbing (43) and onychorrhexis (35) were the most common findings noted. Out of the 67 patients who were chronic smokers, 15 cases in our study (22%), had tobacco nail stains. Tobacco stains on fingers are commonly seen among smokers, but there is scarce description of this phenomenon. Staining may result from local pigment deposition secondary to high-tar concentration in the skin-cigarette interface.⁶ Nicotine has been shown to reduce blood flow in fingers and increase systemic blood pressure, a mechanism that could rationally explain the association of impaired stain removal and peripheral arterial disease.^{7,8} Yellow staining identifies high risk smokers due to the tobacco exposure.⁶ Other nail changes observed were onychomycosis, subungual hyperkeratosis, beau's line, onycholysis, koilonychia, onychomedesis, pincer nail and nail pigmentation. The result observed in regard to clubbing and koilonychia were similar to results observed by Stone OJ in association with chronic pulmonary diseases.⁹ Hyperkeratosis of both elbows referred to as Dahl's sign or Thinkers sign was observed in 33% of patients, which confirms a higher incidence of this cutaneous finding among patients with chronic pulmonary disease.^{5,10} Dahl's sign was first described in a patient with severe COPD. It results from repeated pressure from the elbows on the epidermis of the thighs in patients spending large amounts of time in the tripod position, resulting in hyperpigmented, hyperkeratotic plaques. Dahl's sign can also be seen on the elbows

of patients who chronically lean forward on a hard surface, essentially creating a callus, as seen in our patients although characteristically it is generally found on the thighs. This finding provides supporting evidence of disease chronicity and severity among patients with COPD.¹¹ According to Pride, these lesions responded readily to emollients and are generally asymptomatic.⁴ Oral mucosal pigmentation were seen in 4 patients, which may be correlated with smoking, a substance abuse commoner among patients with chronic pulmonary disease.¹² Pigmentary changes, lichen planus, verruca vulgaris, eczemas were other changes observed in our study but there are no literature reviews suggesting correlation between these changes and chronic pulmonary diseases till date.

Conclusion

A high frequency of various cutaneous manifestations in patients with chronic pulmonary disease was observed in the study undertaken. With paucity of medical literature and fragmentary existent data on cutaneous manifestations in patients with chronic pulmonary disease, there is definitely a need to take up more such studies to correlate cutaneous findings with chronic pulmonary disease, which may enable comprehensive management of such patients.

Acknowledgement: Department of Respiratory Medicine

References

1. Callen JP. Skin Signs of Internal Malignancy. In: Callen JP, Jorizzo JL, Bologna JL, Piette W, editors. *Dermatological Signs of Internal Disease*. 3rd edition. Philadelphia: WB Saunders, 2003.p.95-110.
2. Franquet T, Giménez A, Cáceres J, Sabaté JM, Nadal C. Imaging of pulmonary-cutaneous disorders: matching the radiologic and dermatologic findings. *Radiographics* 1996;16:855-69.
3. Rullán J, Seijo-Montes RE, Vaillant A, Sánchez NP. Cutaneous Manifestations of Pulmonary Disease. In: Sánchez NP, editor. *Atlas of Dermatology in Internal Medicine*. New York: Springer Science and Business Media; 2012.p.17-30.
4. Pride H. The dermatology of chronic lung disease. *Cutis* 1991;48:398-403.
5. Zemstov A, Shahar J. Skin manifestations of chronic obstructive pulmonary disease. *Cutis* 1993;52:91-2.
6. John G, Pasche S, Rothen N, Charmoy A, Delhumeau-Cartier C, Genné D. Tobacco-stained fingers: a clue for smoking-related disease or harmful alcohol use? A case-control study. *BMJ Open* 2013;3:e003304.
7. Reus WF, Robson MC, Zachary L, et al. Acute effects of tobacco smoking on blood flow in the cutaneous micro-circulation. *Br J Plast Surg* 1984;37:213-5.
8. Rojanapongpun P, Drance SM. The effects of nicotine on the blood flow of the ophthalmic artery and the finger circulation. *Graefes Arch Clin Exp Ophthalmol* 1993;231:371-4.
9. Stone O. J. Spoon nails and clubbing. *Cutis* 1975;16:235-41.

10. Kaufman W, Kaufman J. Hyperkeratoses of forearms and thighs associated with chronic lung disease. *J Am Acad Dermatol* 1987;16:889-90.
11. Miller PE, Houston BA. Images in clinical medicine. Dahl's sign. *N Engl J Med* 2014;371:357.
12. Moravej-Salehi E, Hajifattahi F. Relationship of Gingival Pigmentation with Passive Smoking in Women. *Tanaffos* 2015;14:107-14.