

Content available at: <https://www.ipinnovative.com/open-access-journals>

IP Indian Journal of Clinical and Experimental Dermatology

Journal homepage: www.ijced.org/

Original Research Article

Dermatosis among overweight and obese children attending a tertiary care centre - A prospective study

Rakhee V Nair¹, Sana Shams^{1,*}, Rathish T Pillai¹, Febin Kallan¹¹Dept. of Dermatology, Azezia Medical College Hospital, Adichanalloor, Kerala, India

ARTICLE INFO

Article history:

Received 06-09-2022

Accepted 08-09-2022

Available online 29-09-2022

Keywords:

SD-seborrheic dermatitis

Keratosis pilaris

ABSTRACT

Background: Obesity is a chronic disease that is increasing worldwide, both amongst adults and children. As per family health survey conducted by Ministry of Health and Family Welfare in 2022, 38% women and 36.5% of men in Kerala are overweight or obese. It can affect almost all organs, including the skin. Obesity among children is increasing in India with an overall prevalence of 8-10% (15-20% in urban population). The cutaneous manifestations can be associated both with the age of onset and duration of obesity. However, studies showing association with class of obesity and cutaneous manifestations are lacking and hence we undertook this study, to know the association in children attending a tertiary care center.

Materials and Methods: This was a prospective study carried out over a period of 6 months from May 2021 to November 2021 in our centre. A total of 133 children, aged 6–16 years with BMI >25 kg/m² were included in the study. After taking informed consent from the parents/attendants; demographic details, height and weight were recorded and systemic examination was done. A detailed cutaneous examination was performed, and all the findings were noted in a predesigned proforma. Relevant investigations were carried out, wherever deemed necessary.

Results: A total of 133 children (male/female 63.9%/ 36.1%) were included in the study with a mean age of 10.97 ± 2.72. The mean BMI of the patients was 28.43 ± 3 kg/m². Majority of the patients (78.9%) were overweight; 17.3% had Class I obesity, 3% had Class II obesity and 0.8% had Class III obesity. The most common cutaneous changes observed in our patient group were acanthosis (62.4%), seborrheic dermatitis (47.4%), seborrheic dermatitis (37.6%), frictional dermatitis (29.3%), striae distensae (24.8%), tinea cruris (24.8%), keratosis pilaris (18.1%), plantar hyperkeratosis (10.5%) and achrochordon (3.8%). The incidence of acanthosis nigricans, striae, seborrheic dermatitis, frictional dermatitis, seborrheic dermatitis, verruca, keratosis pilaris and acne were higher in children with Class II obesity while acanthosis, striae, acne, and hirsutism was more common in Class III obesity.

Conclusions: As the prevalence of obesity is increasing among the children, the paediatricians and dermatologists should be aware of its various manifestations including the cutaneous ones to ensure their early diagnoses and treatment, which are as common as in adults, and can be a source of great physical or psychological morbidity.

This is an Open Access (OA) journal, and articles are distributed under the terms of the [Creative Commons Attribution-NonCommercial-ShareAlike 4.0 License](https://creativecommons.org/licenses/by-nc-sa/4.0/), which allows others to remix, tweak, and build upon the work non-commercially, as long as appropriate credit is given and the new creations are licensed under the identical terms.

For reprints contact: reprint@ipinnovative.com

1. Introduction

Obesity is a chronic disease, reported world wide. Although common in adults, the increasing prevalence in children

is alarming. Abnormal or excessive fat accumulation that may impair health is defined as overweight and obesity by the World Health Organization (WHO). Overweight and obesity have grown in children in the last decades and is now an epidemic, especially in the developed and developing nations. This can lead to significant public health

* Corresponding author.

E-mail address: sanaanzar143@gmail.com (S. Shams).

issues.¹ Poor lifestyle behaviours is one of the main reasons for childhood obesity. These include sweetened beverage consumption, skipping breakfast, low milk, vegetable and fruit intake, and increased sedentary habits. Children with obesity are more prone to becoming obese adults. They can have long-term cardiometabolic diseases, Type 2 diabetes, cardiovascular morbidity and mortality later in life.^{1,2}

Skin is affected in various ways in obesity. Studies have shown that the most frequent obesity-associated dermatological conditions in children are acanthosis nigricans and acrochordons, atopic dermatitis, skin infections, and endocrinological changes including hyperinsulinism (insulin resistance) and hyperandrogenism. Other common skin manifestations associated with obesity are striae distensae and plantar hyperkeratosis. Although the causes of the majority of the skin lesions associated with obesity are not known, the larger mass of adipose tissue and the secretion of peptides (cytokines, hormones, etc.) from enlarged fat cells due to obesity could lead to skin lesions.¹

Body mass index (BMI) is a simple index of weight-for-height that is commonly used to classify overweight and obesity in adults by the WHO. A BMI of 18.5–24.9 kg/m² is taken as normal, BMI 25–29.9 kg/m² overweight, and BMI >30 kg/m² taken as obese. Obesity can further be characterized by BMI as Class I (30–34.9 kg/m²), Class II (35–39.9 kg/m²), and Class III (>40 kg/m²).

We have undertaken this study to assess the different types of skin lesions associated with overweight and obese children between the ages 6 years to 16 years, visiting a tertiary care centre. We also wanted to find, if there is any correlation between the skin changes and the class of obesity.

2. Materials and Methods

This was a prospective study carried out over a period of 6 months from May 2021 to November 2021 in our centre. A total of 133 children aged 6–16 years or more with BMI >25 kg/m² were included in the study. After taking informed consent from the parents/attendants; demographic details, height, weight, and systemic examination were done. A detailed cutaneous examination was performed, and all the findings were noted on a predesigned proforma. Relevant investigations were carried out, wherever deemed necessary.

3. Results

A total of 133 children (male/female 63.9%/36.1%) were included in the study. The mean age was 10.97 ± 2.72. The mean BMI of the patients was 28.43 ± 3 kg/m². Majority of the patients (78.9%) were overweight. While 17.3% had Class I obesity, 3% had Class II obesity and 0.8% had Class III obesity, respectively. The most common cutaneous changes observed in our

patient group were acanthosis nigricans (62.4%), seborrheic dermatitis (47.4%), sebomelanosis (37.6%), frictional dermatitis (29.3%), striae (24.8%), tinea cruris (24.8%), acne (18.8%), keratosis pilaris (18%), verruca vulgaris (18%), plantar hyperkeratosis (15.8%), hirsutism (15%), urticaria (12.8%) and achrochordon (9%). Fisher's exact tests have been conducted to find out the significant changes in various dermatoses among over weight and different classes of obesity and it showed that changes like striae, sebomelanosis, frictional dermatitis, acne, seborrheic dermatitis, plantar hyperkeratosis and achrochordon were statistically significant (p<0.05). Independent sample T test was also conducted to find out any statistically significant differences in BMI and the presence or absence of various dermatoses.

The incidence of acanthosis nigricans, seborrheic dermatitis and frictional dermatitis were higher in children with class I obesity. The incidence of acanthosis nigricans, striae, sebomelanosis, frictional dermatitis, seborrheic dermatitis, plantar hyperkeratosis and acne were higher in children with Class II obesity. The incidence of sebomelanosis, chronic urticaria, frictional dermatitis, acne vulgaris, seborrheic dermatitis and plantar hyperkeratosis were more common in class III obesity.

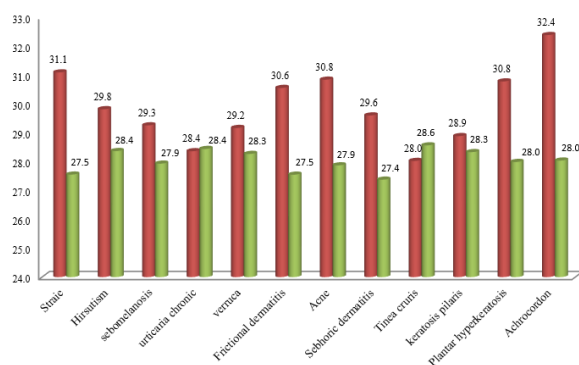


Fig. 1: Mean distribution of BMI between the presence and absence of various dermatoses.

4. Discussion

The age of onset, duration, and severity of the underlying disease are the factors which are directly related to cutaneous manifestations of obesity, and the incidence is greater when diabetes and/or insulin resistance syndrome is associated with obesity. In a study performed by Boza et al., showed that striae, plantar hyperkeratosis, acrochordons, intertrigo, pseudo acanthosis nigricans, keratosis pilaris, lymphedema, and bacterial infections showed a statistically significant relationship with obesity, compared with the control group.²

In our study, acanthosis nigricans was the most common dermatosis seen in 62.4% of the children. Most

common dermatologic manifestation of paediatric obesity is Acanthosis nigricans which is occurring in 66% of overweight adolescents. Most common early symptom observed in children who present with obesity and/or insulin resistance syndrome is acanthosis nigricans.³ Hud et al. observed that acanthosis nigricans along with elevated plasma insulin levels was seen in 74% of obese population.⁴

Seborrheic dermatitis was the second most common cutaneous manifestation seen in 47.4% of the children. In a study by Venna et al., seborrheic dermatitis was seen in 10% of study patient.⁵

Sebomelanosis were seen in 37.6% of children.

Frictional dermatitis was seen in 29.3% and tinea cruris were seen in 24.8% of the children.² In obese patients, mainly due to friction of the skin in body folds skin infections are more common resulting in intertrigo and superadded infection. Pachyonychia, furunculosis, and erythrasma caused by *Corynebacterium minutissimum* are other infections in obese patients. Boza et al. found a statistically significant association of infections with obesity. In our study, tinea cruris were seen in 24.8% of the patients and were more common in 25.7% overweight children.

In our study striae were seen in 24.8% with an incidence of up to 40% in children with moderate to severe obesity in childhood, the presence of striae is directly related to excess weight. Boza et al. have also reported an association between increasing grades of obesity and striae.²

Acne has been attributed to obesity induced hyperinsulinemia and is another common manifestation of obesity. Studies have reported a correlation between the acne incidence and degree of obesity. In our study, acne was a common presentation seen in 18.8% of the patients and was more frequent in Class II obesity.

In our study Verruca and keratosis were seen 18% of children and was more frequent in Class II obesity.

In our study Plantar hyperkeratosis were seen in 15.8% of children and was more frequent in class II obesity. Valeria et al, have also reported an association between plantar hyperkeratosis and severe obesity.¹

Hirsutism was another cutaneous manifestation in our study group seen more among patients with 15.8% children belonging to Class II obesity. Ahsan et al. also noted a correlation between hirsutism and obesity and reported 16% frequency in obese patients.⁶

In our study 9% of children had acrochordons and were significantly seen in class II obese category. Valeria et al., also noted association between acrochordons and obesity due to skin-on-skin friction.⁷

5. Conclusion

As the prevalence of obesity is increasing among the children, the paediatricians and dermatologists should be

aware of its various manifestations including the cutaneous ones to ensure their early diagnoses and treatment, which are as common as in adults, and can be a source of great physical or psychological morbidity. Obesity in children is associated with numerous cutaneous manifestations. Understanding and thorough knowledge of these disorders is necessary for the early diagnosis and management, thereby improving the quality of life.

6. Conflicts of Interest

None.

7. Source of Funding

None.

References

- Hirschler V. Skin and obesity in childhood: an update. *AIMS Med Sci.* 2021;8(4):311–23. doi:10.3934/medsci.2021026.
- Babu VA, Hameed GMS. Dermatological manifestations in people with obesity. *J Evolution Med Dent Sci.* 2019;8(47):3549–53. doi:10.14260/jemds/2019/767.
- Boza JC, Trindade EN, Peruzzo J, Sachett L, Rech L, Cestari TF, et al. Skin manifestations of obesity: A comparative study. *J Eur Acad Dermatol Venereol.* 2012;26(10):1220–3.
- Stuart CA, Pate CJ, Peters EJ. Prevalence of acanthosis nigricans in an unselected population. *Am J Med.* 1989;87(3):269–72. doi:10.1016/s0002-9343(89)80149-4.
- Hud JA, Cohen JB, Wagner JM, Cruz PD. Prevalence and significance of acanthosis nigricans in an adult obese population. *Arch Dermatol.* 1992;128(7):941–4.
- Babu VA, Hameed GMS. Dermatological manifestations in people with obesity. *J Evolution Med Dent Sci.* 2019;8(47):3549–53. doi:10.14260/jemds/2019/767.
- Alam M, Hawlader M, Wahab A, Hossain MD, Nishat SA, Nishat SA, et al. Determinants of overweight and obesity among urban school-going children and adolescents international. *Int J Adolesc Med Health.* 2021;33(1). doi:10.1515/ijamh-2018-0034.

Author biography

Rakhee V Nair, Associate Professor  <https://orcid.org/0000-0002-0637-8974>

Sana Shams, Post Graduate  <https://orcid.org/0000-0003-1831-2320>

Rathish T Pillai, HOD

Febin Kallan, Senior Resident

Cite this article: Nair RV, Shams S, Pillai RT, Kallan F. Dermatoses among overweight and obese children attending a tertiary care centre - A prospective study. *IP Indian J Clin Exp Dermatol* 2022;8(3):192-194.