



## Original Research Article

# Role of intralesional Vitamin D in treatment of cutaneous warts

Noreen Munshi<sup>1,\*</sup>, Krishnendra Varma<sup>1</sup>

<sup>1</sup>Dept. of Dermatology, R. D. Gardi Medical College, Surasa, Madhya Pradesh, India



### ARTICLE INFO

#### Article history:

Received 20-10-2022

Accepted 01-11-2022

Available online 26-11-2022

#### Keywords:

Vitamin D3

Intralesional treatment

Cutaneous warts

### ABSTRACT

**Background:** The majority of treatments for skin warts include destructive techniques like electrocautery and cryotherapy. These techniques of treatment frequently result in recurrence and scarring. Examining the safety and efficiency of intralesional vitamin D3 injection in cutaneous warts is the goal of this study.

**Materials and Methods:** Total 50 people with recalcitrant warts of different dimensions, frequencies, and longevity participated in the study. 0.2 to 0.5 ml of vitamin D3 (600,000 IU, 15 mg/ml) were injected into the bases of warts. A maximum of 5 warts were administered per session, with sessions occurring every 2 weeks till the warts vanished, or for a total of 3 sessions. Following the final injection, individuals were monitored for six months to look for any recurrence.

**Results:** The trial was completed by 50 patients. Out of 50 patients, 35 (or 70%) showed a complete reaction, five (10%) showed a partial response, and ten (10%) showed no response. In every case, the distant warts completely disappeared.

**Conclusion:** A safe, effective, and affordable therapy option for resistant warts is intralesional vitamin D3.

This is an Open Access (OA) journal, and articles are distributed under the terms of the [Creative Commons Attribution-NonCommercial-ShareAlike 4.0 License](https://creativecommons.org/licenses/by-nc-sa/4.0/), which allows others to remix, tweak, and build upon the work non-commercially, as long as appropriate credit is given and the new creations are licensed under the identical terms.

For reprints contact: [reprint@ipinnovative.com](mailto:reprint@ipinnovative.com)

## 1. Introduction

Human papillomavirus causes benign growths of the skin and mucosa known as warts (HPV). Although warts frequently self-limit, the majority of patients seek treatment anyway because they are unsightly and frequently unpleasant.<sup>1</sup> Applying electrocoagulation, topical keratolytics, or laser therapy, to destroy warts locally is a very frequent practise.<sup>2</sup> All of these techniques are typically uncomfortable and may leave scars. Additionally, because they can only remove treated lesions and are ineffective for remote warts, these destructive methods are not appropriate to treat the many refractory warts. Therefore, over the past several years, immunotherapy has been tested to cure the warts in an effort to overcome these limitations. The fundamental idea behind

immunotherapy is to boost cell-mediated immunity in order to get rid of warts.<sup>3–6</sup> Rubella, mumps, Measles vaccination, tuberculin, Mycobacterium w (M.w) vaccine have all been tried as additional antigens.<sup>7</sup> In this report, we discuss the effectiveness of intralesional Vitamin D injections for the medication of skin warts.

## 2. Materials and Methods

The research was carried out at the R.D. Gardi Medical College's Department of Dermatology and Venereology. The institute's ethical review board gave the study its approval. The study included 50 participants who were accessible for analysis.

### 2.1. Study design

The study mainly included all participants, males and females, older than 10 years old, with skin warts. Individuals

\* Corresponding author.

E-mail address: [noreenmunshi10@hotmail.com](mailto:noreenmunshi10@hotmail.com) (N. Munshi).

with immunosuppression and a history of vitamin D hypersensitivity were not allowed to participate in the trial. Dermal warts were identified through clinical assessment and history. At the first appointment, a baseline assessment was conducted, and the demographic information was entered in a standardised questionnaire created for this study. Each visit resulted in the taking of pictures. The medical consequence was recorded by noting the reduction in wart size and quantity at each visit every two weeks for three sessions, as well as at two and six months following the final injection. The removal of all warts was deemed to be complete clearance, both nearby and far away.

Partial recovery depending on the frequency and depth of lesions were reduced by 50% to 100%. Only the bigger warts received vitamin D injections. Each session allowed for the injection of a maximum of 5 warts. Three injections in all were given, with intervals of two weeks between each. Before 3 injections, if entire clearance was attained, the treatment was halted, and the patient was monitored for recurrence. Every two weeks for the first two months, and then every month for the following six months, the treatment efficacy and side effects of all trial participants were assessed in order to monitor any recurrence.

The study's primary target population consisted of all patients—male and female—older than 10 years old with cutaneous warts who had not previously undergone therapy with topical or destructive procedures for at least 6 months. Patients who had immunosuppression or a history of vitamin D hypersensitivity were not allowed to participate in the trial. Clinical indicators and a history were used to identify skin warts. At the initial appointment, a baseline assessment was done, and a standardised questionnaire created for this study was used to record demographic information. Each visit resulted in the taking of pictures. A reduction in the quantity and diameter of warts was noted at every visit at 2-week intervals following three treatments, as well as two and six months after the last injection, to demonstrate clinical response. The total eradication of both the cured and remote warts was referred to as a complete cure. Partial response if the number and size of lesions decreased by 50% to 100%. The greater warts received vitamin D injections. Each session allowed for the injection of a maximum of 5 warts. A maximum of three injections were administered, with repeat doses spaced every two weeks. Before three injections, if complete resolution occurred, the treatment was halted, and the patient was tracked for recurrence. Every two weeks for the first two months, patients were evaluated for treatment effectiveness and side effects, and then once a month for the following six months to track any recurrence.

### 2.2. Injection of vitamin D delivery technique

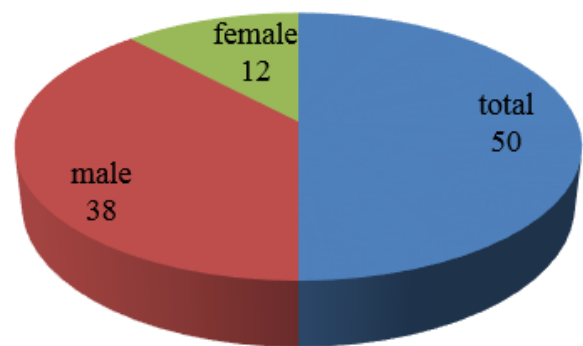
Vials of vitamin D injection are sold; each one contains 6,000 IU of cholecalciferol (15 mg). Before carefully

injecting Vitamin D into the base of each wart, 0.2–0.5 ml (depending on the diameter of the wart) of lignocaine (20 mg/ml) was initially injected into the selected warts. After the injection, the patients were instructed to abstain from using any oral or topical drugs.

### 3. Results

Injections of vitamin D were given to 50 individuals in total. There were 12 women and 38 men among the 50 patients. The patients' ages ranged from 10 to 70 years old. 29 patients (58%) had verruca vulgaris, 11 (22%) had palmo plantar warts, and 6 (12%) had filiform warts. Six patients out of 50 had a single wart, thirteen patients had two to five warts, and thirty-one patients had more than five warts. Out of 50 patients, the study found that 35 (about 70%) had full recovery, 5 (10%) had moderate recovery, and 10 (20%) had no reaction.

**Distribution of patients**



**Fig. 1:** Distribution of patients based on gender

There were 12 females and 38 males in the study. The patients were between the ages of 12 and 59, with a mean age of 29. Figure 1

**Table 1:** Response of medication in different kind of warts.

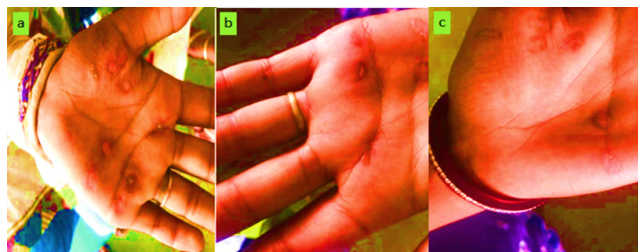
Response to treatment	Frequency	Percentage
Complete Clearance	35	70.0
Partial	5	10.0
No Response	10	20.0
Total	50	100

In 35 patients, the average number of intralesional injections needed for full clearance was 3. Table 1

In 44 (88%) of the patients, adverse effects were observed, however they were all mild and lacked significant consequences. In 43 (86%) of the patients, pain during injection was the most frequent side event, and it went away on its own. Throughout the subsequent 6-month period, 5 individuals experienced recurrence.

**Table 2:** Distribution of patients based on recurrence of warts

Recurrence	Frequency	Percentage
No	33	66.0
Yes	5	10
NR	12	24.0
Total	50	100.0

**Fig. 2:** a: Verruca vulgaris a common wart before treatment; b,c: Complete recovery following two doses

#### 4. Discussion

The removal of cutaneous warts (particularly many ones) needs several sessions and damaging procedures. These harmful operations are frequently accompanied by discomfort, scarring, and dyspigmentation. The rate of recurrence is also significant when a few warts are resistant to various treatment options. Therefore, immunotherapy is by far the best option for treating warts because it strengthens the immune system against the HPV virus, clearing both treated and untreated warts. In comparison to destructive approaches, the Rate of Recurrence is likewise significantly lower.<sup>8–10</sup> Numerous immunotherapeutic treatments, including the MMR vaccine, the BCG vaccine, PPD, bleomycin, and M.w vaccine, have been attempted.<sup>9,11</sup> Intralesional Vitamin D3, a relatively newer therapeutic approach, was used in this investigation. The effectiveness of topical Vitamin D for the management of anogenital and common warts has been demonstrated in numerous research.

By using a topical calcitriol solution, Moscarelli et al. successfully cured a refractory wart in a 41-year-old recipient of a kidney transplant.<sup>12–14</sup> Rind et al.<sup>11</sup> reported that calcipotriene ointment completely eliminated an anogenital wart in a baby. In these two case studies, it was hypothesised that the action of vitamin D3 derivatives on warts resulted from their capacity to control epidermal cell proliferation, differentiation, and cytokine generation. Plantar warts were treated with intralesional Vitamin D3 by Aktas et al. The study involved 20 patients, and by the end of 8 weeks, 80% of the patients had fully recovered.<sup>12</sup> The outcomes were similar to our study's (Table 3). Uncertainty exists over the precise mode of action of vitamin D in the treatment of warts. Hindering the expression of IL-6, IL-8, TNF is thought to have immunomodulatory effects. This effect is thought to be mediated through a VDR-dependent

pathway.<sup>15</sup>

**Table 3:** Comparison with other studies conducted on withintralesional Vitamin D3

Study	No. of patients	Maximum sessions	Adverse events (most common)
Present Study	50	3	Pain during injection
Aktas et al. 2014	20	2	Pain during injection
Kavya M et al. 2017	42	4	Swelling at injection site

#### 5. Conclusion

A novel approach to treating cutaneous warts is intralesional injection of vitamin D3. Multiple warts can be treated, and this is advantageous, safe, and economical. The results are positive despite the present study's small sample size and lack of randomization. Future research will need to examine the effectiveness of intralesional Vitamin D3 injections for the treatment of many cutaneous warts in larger, randomised, placebo-controlled clinical investigations.

#### 6. Source of Funding

None.

#### 7. Conflicts of Interest

There is no conflict of interest.

#### References

1. Sterling JC, Handfield-Jones S, Hudson PM. British Association of Dermatologists. Guidelines for the management of cutaneous warts. *Br J Dermatol.* 2001;144(1):4–11. doi:10.1046/j.1365-2133.2001.04066.x.
2. Gibbs S, Harvey I, Sterling J, Stark R. Local treatments for cutaneous warts: Systematic review. *BMJ.* 2002;325(7362):461.
3. Savant SS, Gore D. Electrosurgery. In: Savant S, Shah R, Gore D, editors. Textbook and Atlas of Dermatotomy and Cosmetology. Mumbai: ASCAD; 2005. p. 305–14.
4. Bourke JF, Berth-Jones J, Hutchinson PE. Cryotherapy of common viral warts at intervals of 1, 2 and 3 weeks. *Br J Dermatol.* 1995;132(3):433–6. doi:10.1111/j.1365-2133.1995.tb08678.x.
5. Tan OT, Hurwitz RM, Stafford TJ. Pulsed dye laser treatment of recalcitrant verrucae: A preliminary report. *Lasers Surg Med.* 1993;13(1):127–37. doi:10.1002/lsm.1900130120.
6. Gonçalves MA, Donadi EA. Immune cellular response to HPV: Current concepts. *Braz J Infect Dis.* 2004;8(1):1–9.
7. Nofal A, Nofal E. Intralesional immunotherapy of common warts: Successful treatment with mumps, measles and rubella vaccine. *J Eur Acad Dermatol Venereol.* 2010;24(10):1166–70. doi:10.1111/j.1468-3083.2010.03611.x.
8. Shaheen MA, Salem SA, Fouad DA, El-Fatah AA. Intralesional tuberculin (PPD) versus measles, mumps, rubella (MMR) vaccine in treatment of multiple warts: A comparative clinical and immunological study. *Dermatol Ther.* 2015;28(4):194–200. doi:10.1111/dth.12230.

9. Garg S, Baveja S. Intralesional immunotherapy for difficult to treat warts with Mycobacterium w vaccine. *J Cutan Aesthet Surg.* 2014;7(4):203–8. doi:10.4103/0974-2077.150740.
10. Majid I, Imran S. Immunotherapy with intralesional *Candida albicans* antigen in resistant or recurrent warts: A study. *Indian J Dermatol.* 2013;58(5):360–5. doi:10.4103/0019-5154.117301.
11. Rind T, Oiso N, Kawada A. Successful treatment of anogenital wart with a topical Vitamin D(3) Derivative in an infant. *Case Rep Dermatol.* 2010;2(1):46–9.
12. Aktas H, Ergin C, Demir B, Ekiz Ö. Intralesional Vitamin D injection may be an effective treatment option for warts. *J Cutan Med Surg.* 2016;20(2):118–22. doi:10.1177/1203475415602841.
13. Saoji V, Lade NR, Gadegone R, Bhat A. Immunotherapy using purified protein derivative in the treatment of warts: An open uncontrolled trial. *Indian J Dermatol Venereol Leprol.* 2016;82(1):42–6. doi:10.4103/0378-6323.171650.
14. Moscarelli L, Annunziata F, Mjeshtri A, Paudice N, Tsalouchos A, Zanazzi M. Successful treatment of refractory wart with a topical activated vitamin d in a renal transplant recipient. *Case Rep Transplant.* 2011;p. 368623. doi:10.1155/2011/368623.
15. Alghamdi K, Kumar A, Moussa N. The role of Vitamin D in melanogenesis with an emphasis on vitiligo. *Indian J Dermatol Venereol Leprol.* 2013;79(6):750–8. doi:10.4103/0378-6323.120720.

### Author biography

**Noreen Munshi**, Senior Resident

**Krishnendra Varma**, Professor and Head

**Cite this article:** Munshi N, Varma K. Role of intralesioal Vitamin D in treatment of cutaneous warts. *IP Indian J Clin Exp Dermatol* 2022;8(4):248-251.