



Review Article

Onychomycosis due to *Trichophyton violaceum* in HIV/AIDS patients of sub-Saharan Africa

Rameshwari Thakur¹, Avneet Singh Kalsi^{2,*}

¹Dept. of Microbiology, Shivam Orthocare Hospital, Una, Himachal Pradesh, India

²Dept. of Dermatology, Muzaffarnagar Medical College & Hospital, Muzaffarnagar, Uttar Pradesh, India



ARTICLE INFO

Article history:

Received 08-03-2023

Accepted 15-03-2023

Available online 04-04-2023

Keywords:

Onychomycosis

HIV/AIDS

Trichophyton violaceum

Lacto Phenol Cotton Blue (LPCB)

ABSTRACT

High prevalence of HIV/AIDS in sub-Saharan Africa is responsible for very high burden of mycotic infections. Also, most of the countries here have highly burdened health system compared to their health budget.

Onychomycosis is a chronic fungal infection of fingers and toenails. It is usually caused by dermatophytes, yeasts, and non-dermatophyte molds (NDM). Prevalence and severity of infection is more in immunosuppressed individuals, especially with HIV/AIDS. The laboratory diagnosis of the causative organism is very important to initiate the specific treatment. Persistence of infection can be the source of infection to the patient himself by autoinoculation and to others. The treatment of HIV/AIDS is mandatory. Onychomycosis in HIV/AIDS patients is usually due to *Trichophyton rubrum* and involve the toenails. The reports of onychomycosis due to dermatophytes from sub-Saharan Africa are scanty. There are only two reports, which have mentioned onychomycosis due to *Trichophyton violaceum* (*T.violaceum*) and involvement of fingernails in HIV/AIDS.

This is an Open Access (OA) journal, and articles are distributed under the terms of the [Creative Commons Attribution-NonCommercial-ShareAlike 4.0 License](https://creativecommons.org/licenses/by-nc-sa/4.0/), which allows others to remix, tweak, and build upon the work non-commercially, as long as appropriate credit is given and the new creations are licensed under the identical terms.

For reprints contact: reprint@ipinnovative.com

1. Introduction

Onychomycosis is due to chronic fungal infection of fingers and toenails. This infection is usually caused by dermatophytes, yeasts, and non-dermatophyte molds (NDM).¹⁻³ In different regions of the world, different dermatophytes are responsible for various clinical types of onychomycosis. It also depends upon the predominant species prevalent in that particular geographical region. Infection of toenails is common in HIV-positive patients. In HIV-uninfected population the distal subungual pattern is the most common and occurs when fungus invades the nail bed in the distal hyponychial area.⁴ Proximal white subungual onychomycosis is the rarest form of onychomycosis in the general population, but this form

has been associated with AIDS and is considered an early clinical marker of HIV infection.⁵

Earlier, the dermatophytes were divided into three genera: *Trichophyton*, *Epidermophyton* and *Microsporum*. But according to a recent study by Hoog et al., using multilocus sequencing, there are nine genera; *Arthroderma*, *Ctenomyces*, *Epidermophyton*, *Lophophyton*, *Microsporum*, *Nannizzia*, *Trichophyton*, *Guarromyces*, and *Paraphyton*.⁶ Onychomycosis is commonly due to *Trichophyton* species.

It has been estimated that 90% of toenails and 75% of fingernails onychomycosis are caused by dermatophytes especially *Trichophyton interdigitale* (*T. interdigitale*) and *Trichophyton rubrum* (*T. rubrum*).^{7,8} Dermatophytes are usually associated with 90% cases of onychomycosis of the toenails and about 50% of fingernail infections.⁹ The prevalence of onychomycosis has been found to be more in patients with HIV/AIDS and Onychomycosis

* Corresponding author.

E-mail address: avneet.singh.kalsi@gmail.com (A. S. Kalsi).

usually appears with a CD4 cell count of <450 cells/mm³.¹⁰ Multiple or ten fingernails involvement due to *T. violaceum* is a typical sign of HIV/AIDS.¹ [Figure 1A]

The prevalence of onychomycosis in the Canadian and Brazilian samples from patients, who were HIV positive, was 24.0% (96 of 400) and 20.0% (20 of 100) respectively.¹¹ In an Indian study, the prevalence was found to be 24% (60 of 250).¹²

Different recognized forms of onychomycosis are: distal and lateral subungual, superficial, proximal subungual, mixed, endonyx, totally dystrophic, and secondary onychomycosis.¹³

2. Laboratory Diagnosis

The fungal culture is considered to be the gold standard diagnostic technique. The subungual debris and nail clipping are collected after cleaning nails with soap and water and then scrubbing it with 70% alcohol. Sabouraud's dextrose agar (SDA) is used with chloramphenicol and the second plate with Chloramphenicol and cycloheximide. The one with both chloramphenicol and cycloheximide will encourage growth of dermatophyte and the one without cycloheximide will allow NDMs to grow. Culture also confirms the viability of the fungus (white, purple and brown variants) [Figure 1E,F,G]. The culture plates are incubated at 25⁰ C for 3 weeks and then morphology is studied by Lactophenol cotton blue mount (LPCB) [Figure 1B,C,D] and biochemical characteristics.

The other recent diagnostic techniques are dermoscopy, optical coherence tomography (OCT), confocal microscopy, Matrix-Assisted Laser Desorption Ionization-Time of Flight (MALDI-TOF), Polymerase chain reaction (PCR).

3. Discussion

Prevalence of onychomycosis in the general population varies from 2-18%.¹⁴ The prevalence onychomycosis in people with HIV/AIDS is much higher and has a prevalence of 20–44%.^{15,16}

There are not many studies on onychomycosis in sub-Saharan Africa. So, it's actual prevalence in HIV/AIDS patients is not known. But, in some of the countries of sub-Saharan Africa, *T. rubrum* is rare and the predominant species is *T. violaceum*, e.g. Botswana,¹ tinea unguium was found to be the most frequent clinical type of dermatophytosis. In almost all cases of onychomycosis due to *T. violaceum*, fingernail (multiple or ten) involvement was found, and the clinical type was endonyx or total dystrophic onychomycosis.

The infection of nails are permanent source of infection and morbidity and can put the patient in embarrassing position, and low self-esteem, especially when fingernails are involved. The danger of deep infections in patients are more if onychomycosis is due to *T. rubrum* especially in

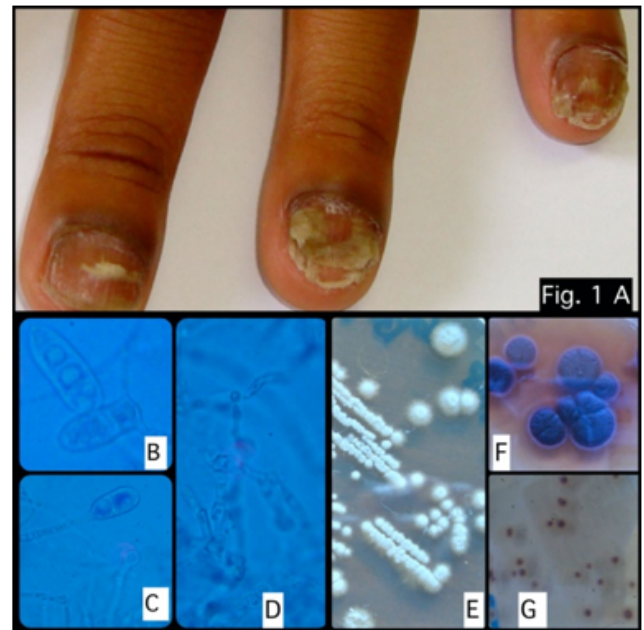


Fig. 1: A: Onychomycosis due to *T. violaceum* in a 10-year-old HIV positive male child; B,C,D: LPCB mount showing rare macroconidia; D: Septate hyphae; E Colonies of white variant; F: Violet colonies; G: Brown colonies of *T. violaceum*.

immunosuppressed individuals. Deep infections due to *T. violaceum* is rare even in patients of HIV/AIDS.

4. Conclusion

There is a very high prevalence of *T. violaceum* in Africa and especially in sub-Saharan Africa.¹⁷ Also, the prevalence of HIV/AIDS is very high in most of the countries. So, the patients with onychomycosis due to *T. violaceum* should be high. Onychomycosis should be investigated and patient's HIV status should be tested and, the treatment should be given accordingly.

It has been found that the incidence of onychomycosis has decreased in HIV/AIDS patients due to introduction of combined Antiretroviral therapy (cART, because it has enabled HIV- infected individuals to have undetectable viral load and high CD4 cell counts, so their immunity become close to normal.¹⁸

Additionally, it has been observed that the onychomycosis severity Index (OSI),¹⁹ decrease after treatment with cART²⁰ and use of prophylactic fluconazole indicated for invasive opportunistic fungal infections also contributes towards the cure of onychomycosis.²¹ Tinea capitis due to *T. violaceum*, or any other dermatophyte infection, if present, should be treated, because this can be a source of perpetual infection, especially due to frequent scratching with fingernails.

Table 1: Onychomycosis due to *Trichophyton violaceum* in patients of HIV/AIDS

S.No.	Author, Place and year	Immune status	Finger Nail	Toe nails	Type of involvement
1.	Thakur, Botswana, 2018 ¹	HIV+	Multiple & Ten	0	Endonyx, Total Dystrophic Onychomycosis
2.	Ravnborg, 1998 ²	HIV+	Fingernails	0	Endonyx, Total Dystrophic Onychomycosis

5. Source of Funding

None.


6. Conflict of Interest


None.

References

- Thakur R, Kalsi AS. Clinico-mycological study of onychomycosis in Botswana. *J Dermat Cosmetol*. 2018;2(6):95–100. doi:10.15406/jdc.2018.02.00095.
- Ravnborg L, Baastrup N, Svejgaard E. Onychomycosis in HIV-infected patients. *Acta Derm Venereol*. 1998;78(2):151–2. doi:10.1080/000155598433566.
- Husain A, Alam NM, Joarder Y. Correlation between clinical and mycological diagnosis of onychomycosis. *J Pak Assoc Dermatol*. 2017;27(3):220–5.
- Aly R, Berger T. Common superficial fungal infections in patients with AIDS. *Clin Infect Dis*. 1996;22(Suppl 2):S128–32.
- Weismann K, Knudsen EA, Pedersen C. White nails in AIDS/ARC due to *Trichophyton rubrum* infection. *Clin Exp Dermatol*. 1988;13(1):24–5. doi:10.1111/j.1365-2230.1988.tb00643.x.
- De Hoog G, Dukik K, Monod M, Packeu A, Stubbe D, Hendrickx M, et al. Toward a Novel Multilocus Phylogenetic Taxonomy for the Dermatophytes. *Mycopathologia*. 2017;182(1-2):5–31. doi:10.1007/s11046-016-0073-9.
- Gupta AK, Sibbald RG, Andriessen A, Belley R, Boroditsky A, Botros M. Toenail onychomycosis - A Canadian approach with a new transungual treatment: Development of a clinical path- way. *J Cutan Med Surg*. 2015;19(5):440–9. doi:10.1177/1203475415581310.
- Joyce A, Gupta AK, Koenig L, Wolcott R, Carviel J. Fungal diversity and onychomycosis: An analysis of 8,816 toenail samples using quantitative PCR and next-generation sequencing. *J Am Podiatr Med Assoc*. 2019;109(1):57–63.
- Bodman MA, Krishnamurthy K. Onychomycosis. StatPearls. Treasure Island (FL): StatPearls Publishing; 2022.
- Ravnborg L, Baastrup N, Svejgaard E. Onychomycosis in HIV-infected patients. *Acta Derm Venereol*. 1998;78(2):151–2.
- Gupta AK, Taborda P, Taborda V. Epidemiology and prevalence of onychomycosis in HIV-positive individuals. *Int J Dermatol*. 2000;39(10):746–53. doi:10.1046/j.1365-4362.2000.00012.x.
- Surjusha A, Kamath R, Oberai C, Saple D, Thakre M, Dharmshale S, et al. A clinical and mycological study of onychomycosis in HIV infection. *Indian J Dermatol Venereol Leprol*. 2007;73(6):397–401. doi:10.4103/0378-6323.37057.
- Hay RJ, Baran R. Onychomycosis: A proposed revision of the clinical classification. *J Am Acad Dermatol*. 2011;65(6):1219–27. doi:10.1016/j.jaad.2010.09.730.
- Farhi D, Savary J, Pansart S, Hesse S. Étude prospective des onychomycoses des pieds en France : prévalence, aspect clinique, impact et prise en charge en médecine générale Prospective study of feet onychomycosis in France: Prevalence, clinical aspect, impact and management in general practice. *J Mycol Med*. 2011;21(4):266–72. doi:10.1016/j.mycmed.2011.10.005.
- Gupta AK, Taborda P, Taborda V, Gilmour J, Rachlis A, Salit I, et al. Epidemiology and prevalence of onychomycosis in HIV- positive individuals. *Int J Dermatol*. 2000;39(10):746–53. doi:10.1046/j.1365-4362.2000.00012.x.
- Singh H, Singh P, Tiwari P, Dey V, Dulhani N, Singh A, et al. Dermatological manifestations in HIV-infected patients at a tertiary care hospital in a tribal (Bastar) region of Chhattisgarh, India. *Indian J Dermatol*. 2009;54(4):338–41. doi:10.4103/0019-5154.57609.
- Coulibaly O, L'Ollivier C, Piarroux R, Ranque S. Epidemiology of human dermatophytoses in Africa. *Med Mycol*. 2018;56(2):145–61. doi:10.1093/mmy/myx048.
- Moreno-Coutiño G. Onychomycosis in Patients Living with HIV/AIDS. *Curr Fungal Infect Rep*. 2019;13:169–74. doi:10.1007/s12281-019-00348-4.
- Carney C, Tosti A, Daniel R. A new classification system for grading the severity of onychomycosis: Onychomycosis Severity Index. *Arch Dermatol*. 2011;147(11):1277–82. doi:10.1001/archdermatol.2011.267.
- Ruíz-López P, Moreno-Coutiño G, Fernández-Martínez R, Espinoza-Hernández J, Rodríguez-Zulueta P, Reyes-Terán G, et al. Evaluation of improvement of onychomycosis in HIV-infected patients after initiation of combined antiretroviral therapy without antifungal treatment. *Mycoses*. 2015;58(9):516–21. doi:10.1111/myc.12350.
- Venkatesan P, Perfect J, Myers S. Evaluation and management of fungal infections in immunocompromised patients. *Dermatol Ther*. 2005;18(1):44–57. doi:10.1111/j.1529-8019.2005.05001.x.

Author biography

Rameshwari Thakur, Senior Microbiologist & Infection Control Consultant  <https://orcid.org/0000-0002-6739-6383>

Avneet Singh Kalsi, Researcher & Cosmetologist  <https://orcid.org/0000-0003-1014-3032>

Cite this article: Thakur R, Kalsi AS. Onychomycosis due to *Trichophyton violaceum* in HIV/AIDS patients of sub-Saharan Africa. *IP Indian J Clin Exp Dermatol* 2023;9(1):17-19.