



Case Report

Atypical erythema multiforme like pityriasis rosea manifestation following Covid vaccine

K Geetha^{1,*}, Puja²

¹Dept. of Dermatology,, All India Institute of Medical Sciences, Raebareli, Uttar Pradesh, India

²Dept. of Pharmacology, All India Institute of Medical Sciences, Raebareli, Uttar Pradesh, India



ARTICLE INFO

Article history:

Received 18-01-2023

Accepted 11-03-2023

Available online 04-04-2023

Keywords:

Erythema multiforme

Pityriasis rosea

Covid vaccine

ABSTRACT

Various cutaneous manifestations have been reported after receiving the COVID-19 vaccine of different types. The commonest reactions were delayed large local reactions, local injection site reactions, urticaria, and morbilliform eruptions following mRNA vaccines. There are very few reports of erythema multiforme (EM) and pityriasis rosea (PR) following Covid vaccines. Erythema multiforme (EM) is one of the commonest reaction following viral infections, drugs and vaccines. Here we are reporting a case of atypical erythema multiforme like pityriasis rosea manifestation following Covishield Covid vaccine second dose.

This is an Open Access (OA) journal, and articles are distributed under the terms of the [Creative Commons Attribution-NonCommercial-ShareAlike 4.0 License](https://creativecommons.org/licenses/by-nc-sa/4.0/), which allows others to remix, tweak, and build upon the work non-commercially, as long as appropriate credit is given and the new creations are licensed under the identical terms.

For reprints contact: reprint@ipinnovative.com

1. Introduction

The COVID-19 vaccine drive in India began on January 16, 2021. For emergency use, India has three vaccines approved (Covishield [ChAdOx1 nCoV-19; Oxford–AstraZeneca; manufactured by Serum Institute of India], Covaxin [BBV152; Bharat Biotech], and Sputnik V [Gam-COVID-Vac; Gamaleya Research Institute of Epidemiology and Microbiology]).¹ The most common cutaneous reactions reported after COVID-19 vaccination inoculation until now were urticaria, major local reactions, local injection site reactions, and morbilliform eruptions.²

Pityriasis rosae (PR) is a papulo squamous disorder characterized classically by the onset of single mother patch or herald patch which usually occurs 2 weeks prior to the other lesions over the trunk or extremities. This is followed by the onset of multiple small lesions all over the body especially over the upper trunk in a Christmas-tree pattern distribution. It is associated with pruritus and mild constitutional symptoms in few patients.³

About 20% of patients can present with atypical manifestations like vesicular, purpuric, urticarial, and generalized papular, lichenoid, erythrodermic, and EM-like PR. PR with EM-like lesions is rare atypical presentation. EM like presentation could be attributed due to the same causative viruses like HHV 6 or 7 as in pityriasis rosea.⁴

2. Case Report

A 34-year-old woman presented with a 7-day history of an itchy rash that consisted of multiple round to oval erythematous plaques, some having indistinct 2 to 3 zones of central dusky erythema, surrounded by pale zone of edema which in turn surrounded by bright erythema. Some plaques had an inner collarette of scaling. The lesions were distributed on the trunk, both limbs and palms (Figures 1 and 2). The patient had vaccination with Covishield 7 days ago, followed by myalgia for the initial 2 days. Later after 5 days she developed joint pain along with skin rashes. No other systemic manifestations. Blood investigations like complete blood count, WBC count were within normal limits. As the patient was reluctant for doing skin biopsy,

* Corresponding author.

E-mail address: geetharbl@outlook.com (K. Geetha).

biopsy was deferred. The skin eruption resolved with short course of oral prednisolone 20mg for 5 days along with topical emollients and oral antihistamines.

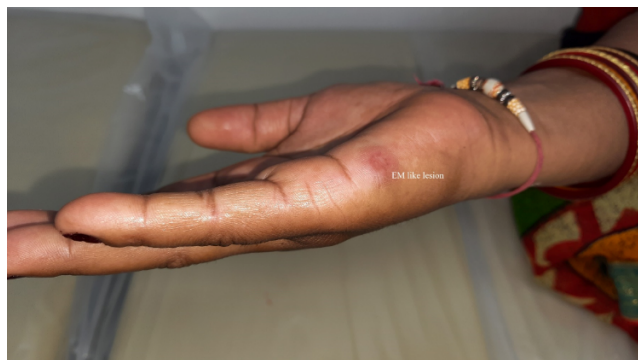

Fig. 1: Erythemamultiforme like lesion on palm



Fig. 2: Erythemamultiforme like lesion on upperlimb

3. Discussion

Vaccine-induced pityriasis rosea is a well-known condition that has been linked to a variety of vaccines, including influenza, H1N1, diphtheria, pneumococcus, small pox, hepatitis B, and the human papilloma virus.⁵ Although the specific pathophysiology is unknown, post-vaccination pityriasis rosea has been linked to HHV 6 and 7 reactivation following vaccination due to immunological stimulation.⁵ Another theory proposed is a cell-mediated immune response linked to molecular mimicry with a viral epitope.⁶

EM is a characteristic skin eruption resembling target-like annular erythematous lesions, most commonly

seen in children and young adults suffering from recurrent herpes simplex infections. Vaccines may trigger this characteristic dermatosis, which is most likely an immunogenic epiphenomenon to viral antigens. While erythema multiforme (EM) is a recognized rare adverse effect of many other vaccines, reports linking this reaction to covid vaccine are scant till present.⁷

Mild to moderate fever, myalgia, and injection site pain are the most common post-vaccination symptoms linked with CovishieldTM, according to the manufacturers, and are usually temporary and self-resolving.⁸ Hyperhidrosis, pruritus, and rash are examples of cutaneous symptoms that have been labelled as "uncommon" and "unsolicited" adverse reactions. The incidence of skin and cutaneous manifestations was about 0.7 percent in a post-approval prospective observational safety study of ChAdOx1 nCoV-19, and included such manifestations as psoriasis, rosacea, vitiligo, Raynaud 's phenomenon, cellulitis, pityriasis rosea and delayed large local reactions.⁹

The clinical picture and chronological relationship between the emergence of the lesion and the diagnosis of atypical erythema multiforme resembling pityriasis rosea manifestation following covid vaccination were used to make the diagnosis in our instance. Although pityriasis rosea has been documented as a Covid-19 manifestation, our patient had no history of Covid-19 or symptoms suggestive of the disease prior to immunisation. Furthermore, the rash's emergence so soon after vaccination makes the temporal association between the two seem highly feasible. As per the World Health Organisation – Uppsala Monitoring Centre (WHO-UMC) the causality assessment for this Adverse Event Following Immunisation (AEFI) was assessed as 'probable'.^[10] The skin eruption was treated with a 5-day course of oral steroids, topical emollients, and oral antihistamines, and the severity of the adverse event following immunisation (AEFI) was moderate, according to the WHO severity scale.⁹

This is a case of atypical erythema multiforme resembling pityriasis rosea following the administration of a recombinant vaccination against Covid-19. More such reports can provide significance and prevalence of such cutaneous manifestations (both uncommon and common) of COVID-19 vaccine.

4. Conflict of Interest

None.

5. Source of Funding


None.

References

1. Choudhary OP, Choudhary P, Singh I. India's COVID-19 vaccination drive: key challenges and resolutions. *Lancet Infect Dis.*

- 2021;21(11):1483–4.
2. Huang L, Yao Z, Zhang J, Das A, Sarkar TK, Chandra S, et al. Two cases of pityriasis rosea after the injection of coronavirus disease 2019 vaccine. *J Eur Acad Dermatol Venereol*. 2016;7(3):212–5. doi:10.4103/2229-5178.182374.
 3. Relhan V, Sinha S, Garg VK, Khurana N. Pityriasis rosea with erythema multiforme - like lesions: an observational analysis. *Indian J Dermatol*. 2013;58(3):242. doi:10.4103/0019-5154.110855.
 4. Adya KA, Inamadar AC, Albadri W. Post Covid-19 vaccination papulovesicular pityriasis rosea-like eruption in a young male. *Dermatol Ther*. 2021;34(5):e15040. doi:10.1111/dth.15040.
 5. Papakostas D, Stavropoulos PG, Papafragkaki D, Grigoraki E, Avgerinou G, Antoniou C, et al. An atypical case of pityriasis rosea gigantea after influenza vaccination. *Case Rep Dermatol*. 2014;6(1):119–23. doi:10.1159/000362640.
 6. Niebel D, Novak N, Wilhelmi J. Cutaneous Adverse Reactions to COVID-19 Vaccines: Insights from an Immunodermatological Perspective. *Vaccines (Basel)*. 2021;9(9):944. doi:10.3390/vaccines9090944.
 7. ChAdOx1 nCoV- 19 Corona Virus Vaccine (Recombinant). [Last accesses 29 February]. Available from: https://www.seruminstitute.com/pdf/covisheild_ChAdOx1_nCoV19_corona_virus_vaccine_insert.pdf2021.
 8. Kaur U, Ojha B, Pathak BK, Singh A, Giri KR, Singh A, et al. A prospective observational safety study on ChAdOx1 nCoV-19 corona virus vaccine (recombinant) use in healthcare workers- first results from India. *EClinicalMedicine*. 2021;38:101038. doi:10.1016/j.eclinm.2021.101038.
 9. Zaki SA. Adverse drug reaction and causality assessment scales. *Lung India*. 2011;28(2):152–3.

Author biography

K Geetha, Associate Professor  <https://orcid.org/0000-0002-0615-556X>

Puja, Assistant Professor  <https://orcid.org/0000-0001-8483-806X>

Cite this article: Geetha K, Puja. Atypical erythema multiforme like pityriasis rosea manifestation following Covid vaccine. *IP Indian J Clin Exp Dermatol* 2023;9(1):55-57.