

Content available at: <https://www.ipinnovative.com/open-access-journals>

IP Indian Journal of Clinical and Experimental Dermatology

Journal homepage: www.ijced.org/

Original Research Article

Efficacy of luliconazole combination shampoo in patients with seborrheic dermatitis

Aseem Sharma¹, Amarendra Pandey², Reshma Parekar³, Maneesha Khalse^{3*}¹Skin Saga Centre for Dermatology, Andheri West, Mumbai, Maharashtra, India²Cosmeasure Clinics, Pandey Hospital, Beoharbagh, Jabalpur, Madhya Pradesh, India³Lupin Ltd., Mumbai, Maharashtra, India

ARTICLE INFO

Article history:

Received 22-07-2023

Accepted 02-09-2023

Available online 17-10-2023

Keywords:

Luliconazole
Scalp erythema
Scalp itching
Scalp dryness
Dandruff

ABSTRACT

Introduction: Seborrheic dermatitis (SD) is a frequently occurring chronic inflammatory disease of the skin which causes scalp erythema, scaling and itching. Though it isn't a life-threatening skin condition, it significantly impacts the quality of life. Luliconazole is a newer antifungal agent with comparable or greater potency than existing agents with better tolerability. We aimed to evaluate its efficacy and tolerability as an initial active and maintenance regimen.

Materials and Methods: In this 12-week, prospective, non-comparative and single-center study, adult subjects with a valid clinical diagnosis of SD of the scalp with a combined score for scaling and erythema between 2 and 4 were included. The primary endpoint was a change in the degree of scaling using a 4-point scale; the secondary endpoints were a change in the degree of erythema and the degree of scalp itching on the scalp at week 4 and week 12. A clinical examination was also performed to assess the tolerability of the shampoo. A subjective self-assessment questionnaire was used to assess patient perception of the efficacy and tolerability of the product.

Results: At week 4 and week 12, the scalp scaling was significantly reduced by 69% and 78.6%, and erythema by 77.1% and 92.4%, respectively. Consequently, there was a progressive reduction in itching from 91.2% at week 4 to 94.7% by week 12. At week 4, 37.8% and week 12, 55.6% of the participants showed complete clearance of dandruff. Mean scalp dryness assessment scores decreased from 0.31 at week 4 to 0.16 by week 12. None of the subjects reported any symptoms of intolerance or recurrences.

Conclusion: The current 12-week study demonstrated significant effectiveness and tolerability of Luliconazole-containing shampoo in the active phase and maintenance treatment of SD with initial twice- and subsequently once-weekly regimens.

This is an Open Access (OA) journal, and articles are distributed under the terms of the [Creative Commons Attribution-NonCommercial-ShareAlike 4.0 License](https://creativecommons.org/licenses/by/4.0/), which allows others to remix, tweak, and build upon the work non-commercially, as long as appropriate credit is given and the new creations are licensed under the identical terms.

For reprints contact: reprint@ipinnovative.com

1. Introduction

Seborrheic dermatitis (SD) is a frequently occurring chronic inflammatory skin disease. It usually occurs in the scalp, face or trunk, which consists of numerous sebaceous glands.¹ In adults, SD (ASD) is prominently reported between the age of 30-60 years in approximately 14%.^{2,3} Among the various causes of scalp dermatoses,

18.7% of cases were attributed to SD in Indian adults primarily due to the *Malassezia* spp.⁴ The pathophysiology of SD likely involves a weak immune reaction to *Malassezia* spp. linked with a poor T-cell response and induction of the complement.⁵ This species may also degrade sebum and consume saturated fatty acids, consequently creating an imbalance in the dermal lipids.

India is a tropical country with extreme heat and humidity. These factors exacerbate SD symptoms,

* Corresponding author.

E-mail address: maneeshakhalse@gmail.com (M. Khalse).

particularly scalp itch and erythema. Thus, though SD is not a serious condition, these symptoms tend to impact the social interactions of the affected individuals.

Additionally, ASD displays a chronic pattern of skin disease typified by relapses and remissions. However, though not curable, it is a tractable condition. Therefore, an effective and well-tolerated maintenance therapy after the initial active treatment regimen is necessary for its management.

Most patients with SD are treatable with shampoos containing ketoconazole or zinc pyrithione (ZPTO), which act against the fungal infection due to *Malassezia* spp. Salicylic acid-containing treatments are effective for treating severe scaling. Nevertheless, the use of these agents is limited by a high incidence of resistance to theazole treatment, recurrent rates, and tolerability issues (increased skin redness or itching, burning sensation and hair loss) associated with their regular use.^{6,7} In-vitro studies have confirmed that the minimum inhibitory concentration (MIC) of luliconazole and itraconazole is comparable to ketoconazole and nearly four-fold more potent than bifonazole and terbinafine against *Malassezia* infections.⁸ Post-marketing reports have shown ketoconazole may be associated with hair discoloration or hair color changes.⁹

Recently, a randomized study reported the effectiveness of luliconazole, ZPTO and salicylic acid-containing shampoo as an initial active treatment regimen used thrice weekly in subjects with SD.¹⁰ In the present study, we aim to further corroborate its efficacy and tolerability not only as an initial active regimen but also as a maintenance regimen used once a week.

2. Materials and Methods

This was a 12-week, prospective, non-comparative and single-centre study from July 2021 to February 2022 in adult subjects of either gender aged between 18-55 years. The inclusion of the subjects was based on a valid clinical diagnosis of dandruff or SD of the scalp with a combined score for scaling and erythema between 2 and 4. Only subjects who provided written informed consent were included in the study.

The subjects with any skin condition that would interfere with the diagnosis or assessment of dandruff, e.g., psoriasis, acne and atopic dermatitis, were not included. Subjects with actinically damaged skin or having used an antidandruff agent or systemic antifungals, systemic steroids, systemic antibiotics, systemic anti-inflammatory agents, or cytostatic or immunomodulating drugs (e.g., cyclosporine, tacrolimus, pimecrolimus) or systemic retinoids or topical steroids, topical retinoids, topical anti-inflammatory agents, topical antibiotics or topical treatment of adherent dandruff (e.g., coal tar preparation, antidandruff shampoo/oils/gels/creams/conditioners, antihistamines in the past 14 days were also excluded. Subjects who could

not assure refraining from the use of other topical agents on the scalp were excluded.

Besides these, subjects who were pregnant or lactating had a history or presence of compromising dermatosis elsewhere on the skin, had a history or presence of serious conditions like Parkinson's disease, infections or disorders of the central nervous, clinically significant systemic diseases were also excluded.

The included subjects were instructed on the use of the Luliconazole combination shampoo [Luliconazole (1% w/v) + Salicylic Acid (3% w/v) shampoo + Zinc pyrithione (1% w/v)] shampoo, twice per week three days apart during the active treatment phase and once per week during the maintenance phase. (Figure 1)

2.1. Endpoints

The effectiveness and tolerability have been assessed using established symptom scoring scales and subjective self-assessment questionnaires described previously in several clinical comparative studies.

2.1.1. Effectiveness

2.1.1.1. Primary endpoint. The primary endpoint was a change in the degree of scaling using a 4-point scale as reference for evaluation (0 = None; 1 = slight, 2 = moderate, 3 = severe) on the scalp at two visits, one at week 4 and another at week 12 compared to baseline.¹¹

2.1.2. Secondary endpoint

The secondary endpoints were a change in the degree of erythema and the degree of scalp itching on the scalp at week 4 and week 12.

A subjective self-assessment questionnaire to assess patient perception of the efficacy of products according to the following scale: 1 = cleared (100%), 2 = marked improvement (75% to 99% clearance), 3 = moderate improvement (51% to 75% improvement), 4 = slight improvement, (50% clearance), 5 = no change, and 6 = exacerbation at week 4 and week 12.

2.1.3. Tolerability

Clinical Examination of Scalp condition for in-use tolerance for dryness using scale - (0 = None; 1 = mild, 2 = moderate, 3 = severe, 4 = very severe) at week 4 and week 12

A subjective self-assessment questionnaire to assess participant perception of the in-use tolerance of products captured reactions like tingling, burning sensation, allergic reactions or eye stinging using a scale: (0 = None; 1 = mild, 2 = moderate, 3 = severe, 4 = very severe) at week 4 and week 12.

The proportion of patients reporting recurrence at week 12 was defined as the sum of scores (erythema, scaling, pruritus) greater than 2 at the end of the study (week 12).

2.2. Statistical analysis

All statistical analyses were done using Statistical Package for the Social Sciences (SPSS Statistics for Windows, Version 10.0. Chicago: SPSS Inc). Continuous variables were summarized using summary statistics (number of observations, mean, standard deviation or median with minimum and maximum range). Wilcoxon Sign Rank Test and Mann Whitney U Test were used as tests of significance. A p-value of < 0.05 was considered to be statistically significant.

2.3. Ethics committee approval

The study was approved by the Institutional ethics committee and conducted in accordance with the Good Clinical Practice guidelines and the Declaration of Helsinki 1996.

3. Results

3.1. Effectiveness

Among the 80 subjects screened, 45 were found eligible according to the inclusion criteria. The mean age of the subjects included was 31.91 ± 6.88 years. The study population was predominantly male (N=32; 71.1%). The scalp scaling significantly reduced by 69% at week 4 and 78.6% at week 12 compared to baseline. The scalp erythema also reduced significantly by 77.1% at week 4 and 92.4% by week 12. Consequently, there was a progressive reduction in itching from 91.2% at week 4 to 94.7% by week 12. (Figure 2)

3.2. Subjective assessment of dandruff clearance

At week 4, 37.8% of the participants using luliconazole shampoo showed complete clearance of dandruff, while 62.2% showed marked clearance of dandruff. By week 12, the subjects with complete clearance of dandruff increased to 55.6%; consequently, those with marked clearance decreased to 44.4%.

3.3. Tolerability

Scalp dryness assessment scores (mean \pm SD) decreased from 0.31 at week 4 to 0.16 by week 12. None of the subjects reported any symptoms of intolerance like tingling, burning, allergic reaction and eye stinging. At the end of week 12, there were no subjects with a sum of scores (erythema, scaling, pruritus) greater than 2; therefore, no recurrences were recorded.

4. Discussion

Malassezia spp. is a type of yeast that constitute normal microflora of the human epidermis that reproduce in the presence of intrinsic (e.g., immunity) and extrinsic (e.g.,

tropical climate) predisposing factors in an individual. This leads to an inflammatory reaction against the yeast resulting in the development of SD.¹² Its symptoms, such as erythema and itch, affect the social well-being of the individual. ASD, a chronic condition with periodic relapses and remissions, necessitates the use of a treatment alternative which is effective and well-tolerated with prolonged use. Topical 1% to 2% ketoconazole, 1% ZPTO, and 1% hydrocortisone have been used for scalp SD treatment.⁵ Compared to Ketoconazole-containing shampoo, Luliconazole-containing shampoo is superior in terms of scalp-related quality of life, most commonly affected by subjective scalp itching.¹⁰ Further, the 4-week study also showed that luliconazole-containing shampoo had demonstrated better tolerability than ketoconazole-containing shampoo.¹⁰ Our 12-week study has further corroborated these effectiveness and tolerability results with a significant reduction in both erythema and itching associated with SD. Dryness of the scalp also reduced at 4 weeks and further at 12 weeks. There were no reports of adverse events such as hair loss or increased flaking with luliconazole during the 12-week study. Unlike luliconazole, ketoconazole has been reported to cause adverse events like contact dermatitis (reported in 10% of participants) and rashes with prolonged use.^{13,14} Moreover, it also can cause drug interactions due to its effects on CYP3A4 enzymes if used over an extended period.¹⁵ Long-term topical corticosteroid use may produce class-associated adverse reactions. Instead, the use of salicylic acid, which has proven anti-inflammatory activity and inhibitory effect on *Malassezia furfur*, improves the erythema of SD. Besides, with milder and fewer side effects, it could be tolerated for an extended time.¹⁶ Over five decades old, ZPTO is an antifungal agent inhibiting fungal growth. Its particles remain on the skin surfaces even when distributed from rinse-off products like shampoos.

5. Limitations

Though the study demonstrated a significant difference in scalp scaling, itching and erythema compared to the baseline, it is limited by a small sample size, single-centric design and absence of a control group. The single-centre study probably led to the recruitment of fewer participants, which may prevent the findings from being extrapolated. The absence of a randomly selected control group may have a risk of investigator bias.

6. Conclusions

Luliconazole, a relatively newer antifungal agent, is well-tolerated with no safety concerns and, therefore can be used for prolonged periods as maintenance treatment for a relapsing but controllable skin condition like SD with the other established constituents. The current 12-week

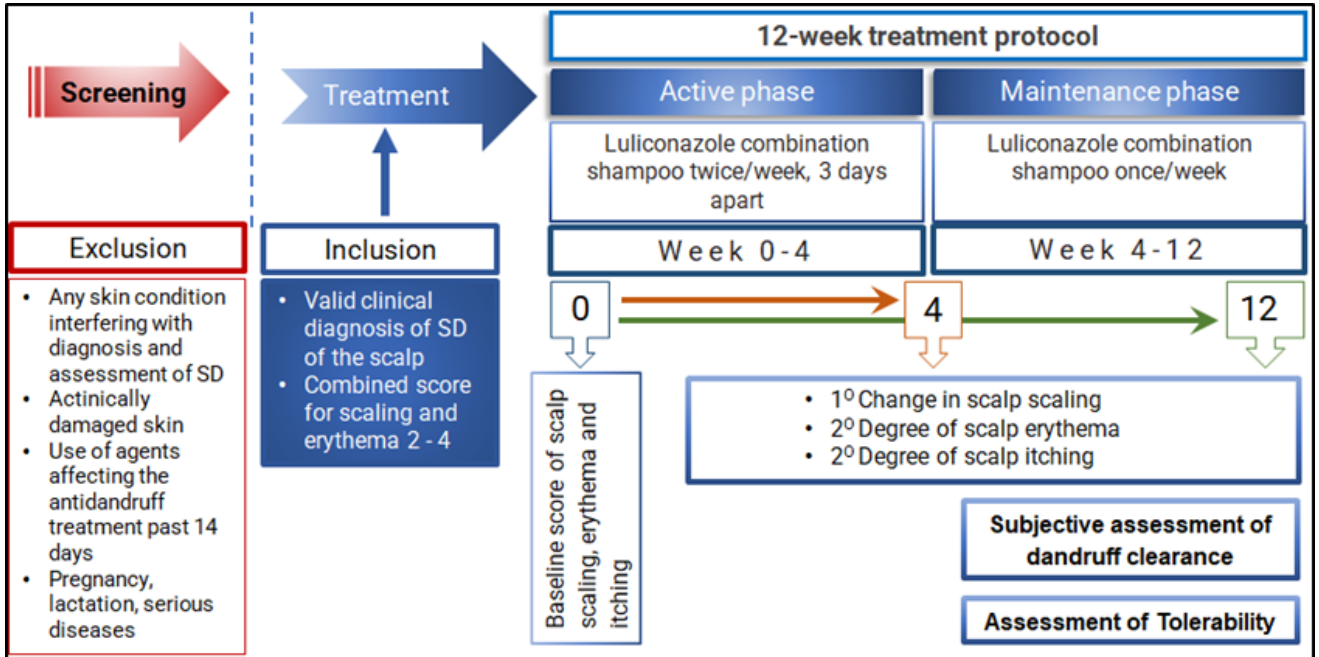


Figure 1: Study design

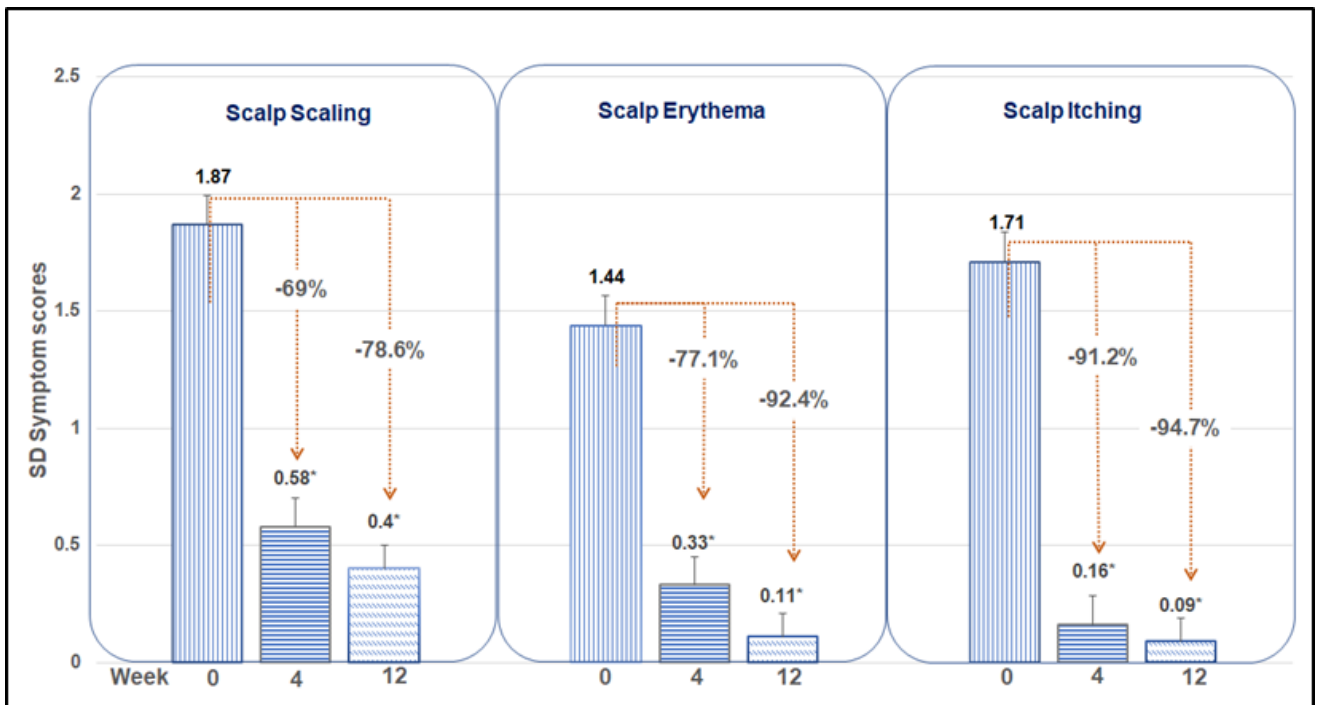


Figure 2: Effectiveness of luliconazole combination shampoo on symptoms of SD across 12 weeks * P = 0.001 vs baseline, SD-Seborrheic dermatitis

study demonstrated significant effectiveness and tolerability of Luliconazole-containing shampoo in the active phase and maintenance treatment of ASD with initial twice- and subsequently once-weekly regimens.

7. Conflicts of Interest

None of the authors has any conflicts of interest to declare

8. Source of Funding

The study was sponsored by Lupin Ltd.

9. Acknowledgement


The medical writing support was provided by Miss Seema Kalel at Intersect Communications, India.

References

- Cheong WK, Yeung CK, Torsekar RG, Suh DH, Ungpakorn R, Widaty S, et al. Treatment of Seborrheic Dermatitis in Asia: A Consensus Guide. *Skin Appendage Disord*. 2016;1(4):187–96.
- Sanders MGH, Pardo LM, Franco OH, Ginger RS, Nijsten T. Prevalence and determinants of seborrheic dermatitis in a middle-aged and elderly population: the Rotterdam Study. *Br J Dermatol*. 2018;178(1):148–53.
- Zander N, Sommer R, Schäfer I, Reinert R, Kirsten N, Zyriax BC, et al. Epidemiology and dermatological comorbidity of seborrheic dermatitis: population-based study in 161 269 employees. *Br J Dermatol*. 2019;181(4):743–8.
- Pillai J, Okade R. A clinical spectrum of scalp dermatoses in adults presenting to a tertiary referral care centre. *Int J Biol Med Res*. 2014;5(4):4434–9.
- Tucker D, Masood S. Seborrheic Dermatitis. [Updated 2022 Aug 1]. vol. 2022. StatPearls [Internet]. Treasure Island (FL): StatPearls Publishing; 2022. Available from: <https://www.ncbi.nlm.nih.gov/books/NBK551707/>.
- Okokon EO, Verbeek JH, Ruotsalainen JH, Ojo OA, Bakhoya VN. Topical antifungals for seborrheic dermatitis. *Cochrane Database Syst Rev*. 2015;2(5):CD008138. doi:10.1002/14651858.CD008138.
- Park M, Cho YJ, Lee YW, Jung WH. Genomic Multiplication and Drug Efflux Influence Ketoconazole Resistance in *Malassezia restricta*. *Front Cell Infect Microbiol*. 2020;10:191. doi:10.3389/fcimb.2020.00191.
- Khanna D, Bharti S. Luliconazole for the treatment of fungal infections: an evidence-based review. *Core Evid*. 2014;9:113–24. doi:10.2147/CE.S49629.
- Product Information. Nizoral (ketoconazole). Janssen Pharmaceuticals; 2002. [accessed on 2 Aug 2023]. Available from: <https://www.medicines.org.uk/emc/product/1510/smpc#greflast>.
- Parasramani SG, Vishwanath V, Ghia D, Gandhi MR, Dhoot D, Barkate H, et al. Prospective, Open-Label, Multi-Centre, Randomized Study to Compare the Effectiveness, Safety, and Tolerability of Lulican™ Shampoo Versus Ketoconazole Shampoo in Indian Adult Patients With Mild to Moderate Scalp Seborrheic Dermatitis (LEAD Study). *Cureus*. 2022;14(11):32035. doi:10.7759/cureus.32035.
- Kim YR, Kim JH, Shin HJ, Choe YB, Ahn KJ, Lee YW, et al. Clinical Evaluation of a New-Formula Shampoo for Scalp Seborrheic Dermatitis Containing Extract of *Rosa centifolia* Petals and Epigallocatechin Gallate: A Randomized, Double-Blind, Controlled Study. *Ann Dermatol*. 2014;26(6):733–8.
- Zisova LG. *Malassezia* species and seborrheic dermatitis. *Folia Med*. 2009;51(1):23–33.
- Sinawe H, Casadesus D. Ketoconazole. Treasure Island (FL): StatPearls Publishing; 2023. Available from: <https://www.ncbi.nlm.nih.gov/books/NBK559221/>.
- Kubicki SL, Damanpour S, Mann R. Ketoconazole shampoo-induced hair discoloration. *Int J Womens Dermatol*. 2019;6(2):121–2.
- El-Garf A, Mohie M, Salah E. Trichogenic effect of topical ketoconazole versus minoxidil 2% in female pattern hair loss: a clinical and trichoscopic evaluation. *Biomed Dermatol*. 2019;3(8):1–8. doi:10.1186/s41702-019-0046-y.
- Gu RL, Wang SQ. Clinical study on treatment of facial seborrheic dermatitis with intense pulsed light combined with 30% supramolecular salicylic acid. *Clinics (Sao Paulo)*. 2020;75:e1875. doi:10.6061/clinics/2020/e1875.

Author biography

Aseem Sharma, Assistant Professor  <https://orcid.org/0000-0001-5873-227X>

Amarendra Pandey, Consultant Dermatologist  <https://orcid.org/0000-0002-9076-2417>

Reshma Parekar, Medical Advisor  <https://orcid.org/0009-0001-7831-4865>

Maneesha Khalse, Medical Advisor  <https://orcid.org/0000-0002-8613-6448>

Cite this article: Sharma A, Pandey A, Parekar R, Khalse M. Efficacy of luliconazole combination shampoo in patients with seborrheic dermatitis. *IP Indian J Clin Exp Dermatol* 2023;9(3):142–146.