

Content available at: <https://www.ipinnovative.com/open-access-journals>

IP Indian Journal of Clinical and Experimental Dermatology

Journal homepage: www.ijced.org/

Case Report

Case report: Pseudoxanthoma elasticum

Ritika Gujrati^{1,*}

¹Dept. of Dermatology, Dhar District Hospital, Dhar, Madhya Pradesh, India



ARTICLE INFO

Article history:

Received 05-08-2023

Accepted 09-19-2023

Available online 17-10-2023

Keywords:

Pseudoxanthoma elasticum

Fundoscopy

ABSTRACT

Introduction: Pseudoxanthoma elasticum (PXE) is a rare multisystem disorder of autosomal recessive inheritance. It is characterized by progressive mineralization and fragmented, calcified elastic fibres of skin, eye and cardio-vascular system (CVS). It is due to the loss of functional mutation ABCC6 gene.

We report such a rare case of PXE with earliest skin manifestation and with no other ophthalmological and CVS findings.

Case Description: This is a case report of 26 years old female complaining of 1 year history of asymptomatic yellow-orange raised lesions on right lateral side of neck.

On clinical examination, yellow-orange micro-papules coalescing to form plaques were noticed over right lateral side of neck. Fundoscopy revealed bilateral myopic degenerative changes with no other specific findings. Histopathology of said lesions showed atrophic epidermis with abnormal elastic fibres in the mid-dermis confirming the diagnosis. Course and prognosis were explained to the patient and she was advised regular follow-up.

Conclusion: PXE is rare in occurrence, with no definite and effective treatment. It has a good prognosis if retinal and cardio-vascular complications are regularly monitored and prevented.

This is an Open Access (OA) journal, and articles are distributed under the terms of the [Creative Commons Attribution-NonCommercial-ShareAlike 4.0 License](https://creativecommons.org/licenses/by-nc-sa/4.0/), which allows others to remix, tweak, and build upon the work non-commercially, as long as appropriate credit is given and the new creations are licensed under the identical terms.

For reprints contact: reprint@ipinnovative.com

1. Introduction

Pseudoxanthoma Elasticum is a rare autosomal recessive multisystem disorder also known as Grönblad-Strandberg syndrome. There is pathological fragmentation and mineralization of elastic fibres in the dermis. It mainly involves the connective tissue of skin, tunica media and intima layer of blood vessel and Bruch's membrane of retina.

The leading cause of this disorder is the lack of functional ATP binding cassette transporter gene multidrug resistance associated protein 6 [ABCC6], which has been mapped to chromosome 16p13. This further causes the deposition and accumulation of calcium with other minerals in the elastic tissue.

* Corresponding author.

E-mail address: gujrati.ritika10@gmail.com (R. Gujrati).

2. Case Report

A 26 years old female presented with yellow-orange asymptomatic lesions on right lateral side of neck of 1 year duration and was increasing in size. The patient had no complaints of pain or inflammatory signs on and around the lesions with no history of treatment.

Past history, family history, personal history and drug history were non-contributory.

2.1. Clinical examination

On local examination - yellow-orange micro papules coalescing to form plaques of size ranging from 1 x 1 cm² to 1.5 x 2 cm² in dimension, well circumscribed, smooth surface, firm in consistency, shiny lesions were noticed over right lateral side of neck. [Figure 1]

Hair, nails, mucous membranes and other systemic examinations were normal.

Fundoscopy revealed bilateral myopic degenerative changes (lattice degeneration) and peau d'orange appearance of retina with no other specific findings. [Figure 2]

2.2. Investigation

Routine haematological investigation, urine analysis, liver function tests, renal function tests, blood pressure measurement, electrocardiogram, examination of arterial stiffness and abdominal echography were done, which were within the normal limits.

Histopathology: It showed atrophic epidermis with abnormal bright pink elastic fibres in the mid-dermis. [Figure 3]

2.3. Treatment

Patient was explained about the course and prognosis of the disease and she was advised regular follow-up.

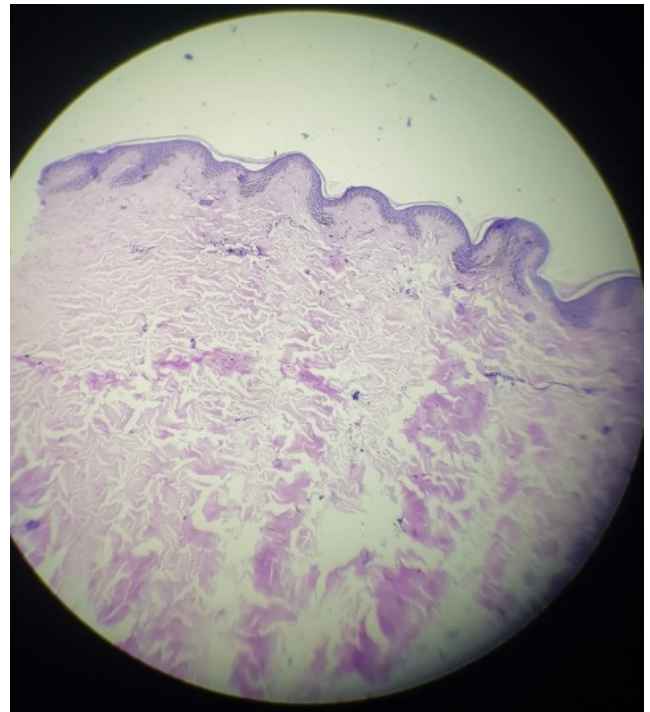


Fig. 3: Histopathology

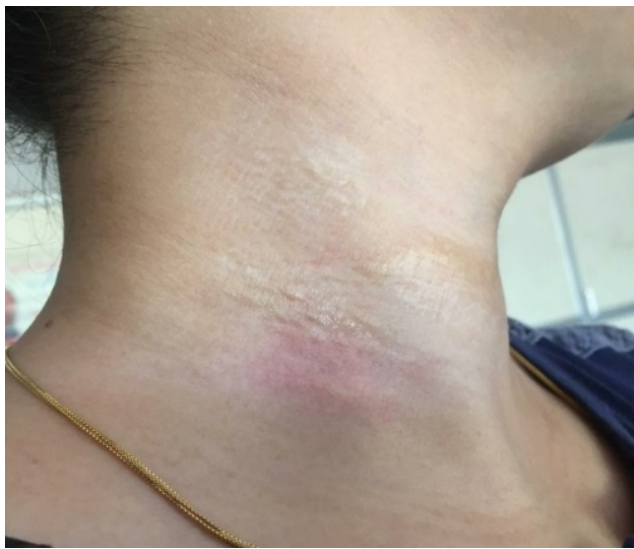

Fig. 1: Yellow-orange papules over neck

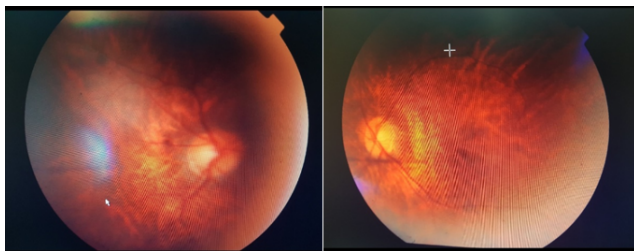


Fig. 2: Right and left retina

3. Discussion

Pseudoxanthoma elasticum is a rare inherited multisystem disorder characterized by pathological calcification of the elastic connective tissue, involving predominantly the skin, eyes (retina Bruch's membrane) and cardiovascular system. The precise prevalence of this illness is unknown; however, a variable involvement between 1:25,000-100,000 inhabitants worldwide is estimated, with slight predominance of females.¹

More than 120 different mutations in *ABCC6* have been identified, and PXE is now considered to be recessively inherited in most cases. *ABCC6* is predominantly expressed in the liver and kidneys, suggesting that transporter dysfunction may lead to accumulation of an unknown substrate in the blood causing secondary dystrophic changes of elastic tissues. Therefore, PXE would not seem to be a primary disorder of elastic fibres, rather than a systemic metabolic disease.²

At initial stage, skin lesion manifests as flesh coloured to yellow-orange papules which progressively coalesce to form plaque; which is seen in this case. Later the affected skin becomes lax and redundant. It mainly involves the flexure area starting from sides of neck followed by armpits, cubital and popliteal region, groin and periumbilical area.³

Eye lesion manifests as orange peel retina due to calcification of Bruch's membrane presents as dark spots at peripheral zone of retina.^{4,5} Comet lesion which is pathognomonic of PXE are chorio-retinal atrophic spots.³

Angioid streaks due to rupture and mineralization of Bruch's membrane is the characteristic eye sign of PXE. It also involves neovascularization leading to subretinal haemorrhage and scar formation resulting in loss of vision.⁵

The major cause of morbidity is the CVS manifestation. It manifests as hypertension, angina pectoris to cardiac arrest and strokes at an early age. There are some gastrointestinal symptoms such as melena and hematemesis may also be present.⁶

Histopathology shows elastorrhexis in the middle dermis with positive Von Kossa and Verhoeff-Van Gieson stain for calcification and elastic tissue respectively.⁷ Deposits are mainly of hydroxyapatite and calcium biphosphate, but iron, phosphate, and carbonate with abnormal collagen fibres and proteoglycans may also be observed.⁸

PXE is diagnosed on the basis of clinical, histopathological and genetic analysis. It requires multi-disciplinary approach which consist of regular monitoring of cardio-vascular and ophthalmological complications.

It is an incurable disease. Although, some laser therapy, photodynamic therapy, macular translocation surgery for cosmetic satisfaction and anti-endothelial growth factor to improve and delay the loss of vision may be of some benefit.

4. Conclusion

Being rare in occurrence, diagnosis is further challenging in patients with earliest focal skin lesions. Due to lack of specific management regular follow-up of these patients is very vital.

5. Patient Consent

A written and informed consent were obtained from the patient for sharing the clinical pictures and details.

6. Conflict of Interest

Author has no conflict of interest to declare.

7. Source of Funding

No funding source.

References

1. Finger RP, Issa PC, Ladewig MS, Götting C, Szliska C, Scholl HPN, et al. Pseudoxanthoma elasticum: genetics, clinical manifestations and therapeutic approaches. *Surv Ophthalmol.* 2009;54(2):272–85.
2. Baglieri F, Scuderi G. Pseudoxanthoma elasticum: description of a late onset case. *Indian J Dermatol Venereol Leprol.* 2010;76(4):448. doi:10.4103/0378-6323.66608.
3. Gass JD. Comet" lesion: an ocular sign of pseudoxanthoma elasticum. *Retina.* 2003;23(5):729–30.
4. Hu X, Plomp AS, Soest S, Wijnholds J, de Jong P, Bergen AAB, et al. Pseudoxanthoma elasticum: a clinical, histopathological, and molecular update. *Surv Ophthalmol.* 2003;48(4):424–38.
5. Naouri M, Boisseau C, Bonicel P, Daudon P, Bonneau D, Chassaing N, et al. 5.Naouri M BCBPDPBDCN et al. Manifestations of pseudoxanthoma elasticum in childhood. *Br J Dermatol.* 2009 Sep;161(3):635–9. . *Br J Dermatol.* 2009;161(3):635–9.
6. Braun SA, Finis D, Helbig D. Pseudoxanthoma elasticum. More than a skin problem. *Hautarzt.* 2013;64(4):222–4.
7. Roach ES, Islam MP. Pseudoxanthoma elasticum. *Case Rep Dermatol.* 2015;13(1):215–7. doi:10.1016/B978-0-444-62702-5.00015-9.
8. Marconi B, Bobyr I, Campanati A, Molinelli E, Consales V, Brisigotti V, et al. Pseudoxanthoma elasticum and skin: Clinical manifestations, histopathology, pathomechanism, perspectives of treatment. *Intractable Rare Dis Res.* 2015;4(3):113–22.

Author biography

Ritika Gujrati, Consultant

Cite this article: Gujrati R. Case report: Pseudoxanthoma elasticum. *IP Indian J Clin Exp Dermatol* 2023;9(3):163-165.