

Content available at: <https://www.ipinnovative.com/open-access-journals>

IP Indian Journal of Clinical and Experimental Dermatology

Journal homepage: www.ijced.org/

Case Report

Unstable solar lentigo mimicking lentigo maligna melanoma: A case report

Benazir Hakim¹, Oindrila Dutta¹, Madhobendra Nath Sarkar¹, Chinjitha T Davis¹, Soumi Biswas², Smriti Choudhary³, Arun Achar^{1,*}, Bhaskar Mitra⁴

¹Dept. of Dermatology, Venereology and Leprosy, NRS Medical College, Kolkata, West Bengal, India

²Dept. of Dermatology, NRS Medical College, Kolkata, West Bengal, India

³Bokaro District Hospital, Bokaro, Jharkhand, India

⁴Drs Tribedi and Roy Diagnostic Laboratory, Kolkata, West Bengal, India



ARTICLE INFO

Article history:

Received 25-08-2023

Accepted 30-09-2023

Available online 17-10-2023

Keywords:

Solar lentigo

Lentigo maligna melanoma

Unstable lentigo

Melanoma

ABSTRACT

Solar lentigo (SL) is a hyperpigmented macule that develops due to chronic ultraviolet exposure. A 35-year-old housewife, presented with an asymptomatic pigmented patch on the right side of her nose for the last 10 years, with a rapid increase in size and variability in pigmentation over the last 3 years. She had no history of excessive sun exposure. Upon examination, there was a solitary, hyperpigmented, well to ill-defined patch of irregular shape and margin, measuring 3 cm * 2.5 cm, with variability in colour and areas of regression, almost covering Right side of nose. The patch appeared light brown with areas of dark brown and black. Differential diagnoses considered were Lentigo maligna melanoma (LMM), Solar Lentigo (SL), and flat seborrheic keratosis. Dermoscopy (Polarised illuco IDS-1100 dermoscope) revealed diffuse brown pigmentation with a faint pigmented network, along with dark brown to black globules and blotches. Due to the asymmetry of pigmentation, a punch biopsy was performed from the area of darkest pigmentation to rule out LMM. In Histology, the epidermis exhibited hyperkeratosis, follicular plugging, acanthosis, and downward elongation of the rete ridges. There was hyperpigmentation of the basal layer, an increased number of melanocytes, and the presence of melanophages in the papillary dermis. The biopsy report was consistent with Solar Lentigo (SL), and we concluded it as unstable solar lentigo (USL). This case is presented due to its clinical and dermoscopic resemblance to LMM and to increase awareness of USL and the importance of periodic surveillance.

This is an Open Access (OA) journal, and articles are distributed under the terms of the [Creative Commons Attribution-NonCommercial-ShareAlike 4.0 License](https://creativecommons.org/licenses/by-nc-sa/4.0/), which allows others to remix, tweak, and build upon the work non-commercially, as long as appropriate credit is given and the new creations are licensed under the identical terms.

For reprints contact: reprint@ipinnovative.com

1. Introduction

Solar lentigo is a hyperpigmented macule that develops due to chronic ultraviolet exposure.¹ Solar lentigo or lentigo senilis or old age spot senile freckles are blemishes on the skin associated with aging and exposure to ultraviolet radiation from the sun. They range in color from light brown to red or black and are located in areas most often exposed to sun, particularly the hands, face, shoulders, arms, forehead and scalp if the person having bald.

* Corresponding author.

E-mail address: arunachar1967@gmail.com (A. Achar).

An unstable solar lentigo is a solar lentigo which has areas of melanocytic hyperplasia not extending past the margin of the specific lesion. They are discrete, macular, pigmented lesions arising on sun-damaged skin and a subset of typical solar lentigos. Clinically they differ from usual solar lentiginos in often being solitary or larger and darker than adjacent solar lentiginos. These lesions are of clinical importance as they can arise in close proximity to lentigo maligna and in a single lesion there can be demonstrated changes of solar lentigo, unstable solar lentigo and lentigo maligna. Solar lentigo is a benign lesion which can be treated

by either physical therapy and topical therapy. Physical therapy includes cryotherapy, laser therapy, pulsed light and chemical peel. Topical therapy consists of depigmenting agent such as kojic acid, azelaic acid but the treatment response is not satisfactory. As unstable solar lentigo can change into lentigo maligna melanoma, so periodic surveillance along with treatment is necessary.

So an unstable solar lentigo is an atypical entity which is characterized by solitary, hyperpigmented macules over chronic sun-damaged skin mainly face, hands, neck, V area of chest etc due to melanocytic proliferation. This lesion can masquerade lentigo maligna. We report a 35 year old woman of unstable solar lentigo which mimicked as lentigo maligna.

2. Case Report

A 35 year old Indian home-maker presented with asymptomatic hyperpigmented patch on the right side of nose since 10 years. She noticed a rapid increase in size and extending to upper part of nose with variability of pigmentation over last 3 years. Average photo-exposure times were about 2-4 hours due to some house-hold work. She did not have any co-morbidities, drug history or family history. On examination, 3*2.5 cm sized pigmented patch presents over mainly right side of nose. The lesion has variability in pigmentation, which is ranging from light to deep brown to brownish black pigmentation (Figure 1). Differential diagnosis was kept as Lentigo Maligna Melanoma, Solar lentigo, flat seborrheic keratosis. Dermoscopy (Polarised illuco IDS-1100 dermoscopy) revealed black to brown blotches, globules in the background of diffuse brown pigmentation (Figure 2A,B). Punch biopsy has been done. Histopathology shows hyperkeratosis, follicular plugging, acanthosis, and elongation of rete ridges, hyperpigmentation of basal layer, increased number of melanocyte, increased number of melanophages over papillary dermis. A sprinkling of inflammatory cells was also observed (Figure 3A,B). Histology was consistent with solar lentigo, and due to its clinical appearance, we conclude it as unstable solar lentigo. The patient was placed on periodic surveillance.

3. Discussion

Solar lentigo presents as an irregular brown or tan macule with well-defined margin on sun-exposed areas of face and hands in fair-skinned elderly individuals mainly over 40 years of age who have had excessive sun exposure.² Early stages of solar lentigo shows accumulation of melanin and intricate rete ridges, whereas later stage shows accumulation of melanin and rete ridges projects into epidermis and dermis.¹ Dermoscopy shows diffuse brown pigmentation; fine regular pigment network, light-brown finger-print like structure.²

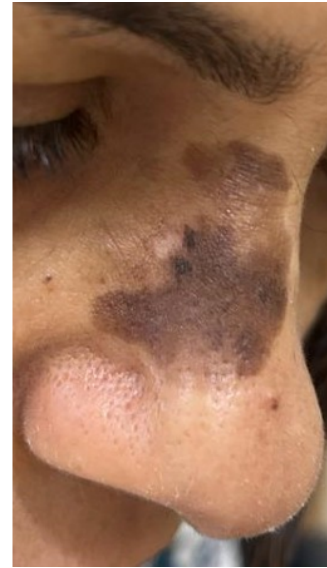

Fig. 1: Clinical image of solar lentigo (Right side of nose)

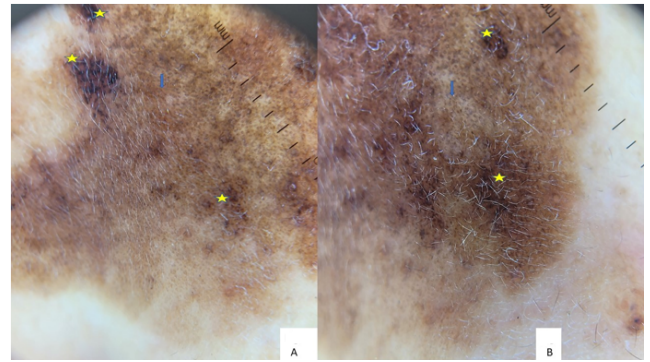


Fig. 2: Dermoscopy images (Polarised illuco IDS-1100 dermoscope) 2A, 2B showing diffuse brown pigmentation with a faint pigmented network (blue arrow), along with dark brown to black globules and blotches (yellow star).

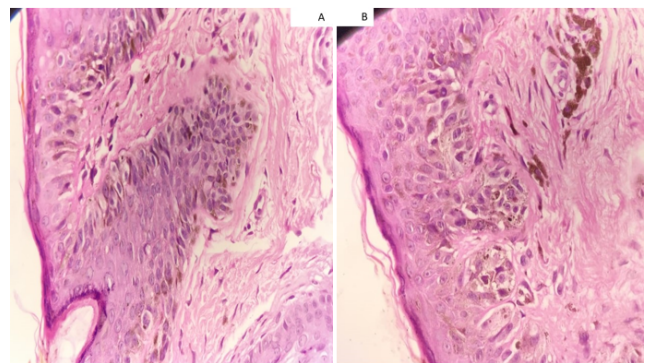


Fig. 3: Histopathology (Hematoxylin eosin stain, 40x High power view) showing epidermis exhibited hyperkeratosis, acanthosis, and downward elongation of the rete ridges. There were hyperpigmentation of the basal layer, an increased number of melanocytes, presence of melanophages in the papillary dermis and sprinkling of inflammatory cells.

A typical solar lentigo is composed of enlarged and proliferating keratinocyte, along with elongation of rete ridges and epidermal hyperplasia. Whereas, unstable solar lentigo characterises by both keratinocyte and melanocyte proliferation.

Lentigo maligna has no keratinocyte component. Atypical melanocyte proliferated at the dermo epidermal junction and poorly formed melanocytic nests scatter along the dermo epidermal junction. This atypical melanocyte extends into hair follicles and eccrine duct. Papillary dermis shows marked solar elastosis with epidermal atrophy. But lentigo maligna usually does not have any distinct margin.

Unstable solar lentigo is a subtype of solar lentigo, characterised by solitary, larger than solar lentigens, variable pigmentation, more irregular on a solar damaged skin. Background erythema, areas of regression may be present.² Dermoscopy findings may show perifollicular pigment asymmetry, pseudonetwork pattern of pigmentation, blue-gray areas.^{3,4} Histological hallmarks are hyperpigmentation of the epidermis with or without elongated rete ridges. On the other hand, Lentigo maligna also presents as a variable pigmented macule but much darker than Solar lentigo.⁵ Lentigo maligna can transform into invasive melanoma but progression is very slow. If invasive melanoma arises out of lentigo melanoma, then the type is predominantly desmoplastic or spindle cell type. Dermoscopic features of lentigo maligna include atypical pseudo- network pattern of pigmentation, asymmetrical pigmented follicular opening, rhomboidal, annular or granular structures along with grey pseudo- network. Histopathological hallmarks of diagnosis of lentigo maligna melanoma is irregular distribution of atypical melanocyte on the basal layer. However immunohistochemistry like staining with HMB 45 or Melan-A can differentiate lentigo maligna melanoma from solar lentigines. Newer imaging techniques like Reflectance confocal microscope, optical coherence tomography can differentiate solar lentigo⁶ and the main advantage of these technique is that these are noninvasive.

There are many hypothesis about the pathophysiology of solar lentigo. One such hypothesis states that upregulation of endothelial (EDN)-1/ Endothelial B receptors(EDNBRs), Stem cell factor (SCF)/c-KIT and Tumor necrosis factor (TNF)-alpha from damaged keratinocytes induced by UVB exposure, leads to continuous stimulation of melanocytes, causing solar lentigo.⁷ Other study have suggested that cytokine released from dysfunctional keratinocyte along with loss of heparan sulfate at dermoepidermal junction due to heparanase activation causes melanocytic hyperplasia leading to solar lentigo.⁸ Another study suggests that abnormal expression of KRT 5 and KRT 10 is responsible for development of solar lentigo in UV damaged skin.⁹

Unstable solar lentigo is considered as a precursor of lentigo maligna melanoma, warranted biopsy and periodic surveillance. Shatkin et al.⁵ reported a case of lentigo

maligna melanoma developed over unstable solar lentigo.

We report this case as dermatologists should be aware of this entity of solar lentigo and importance of periodic surveillance.

4. Conclusion

Solar lentigo is a common condition which we frequently seen in our day to day practices. But while it suddenly increase in size with irregular pigmentation, then confusion arise regarding its transformation into malignancy or not. Even dermoscopic examination doesn't elicit the proper diagnosis. Then we have to do the histopathological examination for confirmation. We report this case as dermatologist should aware of this entity of solar lentiginosis and importance of periodic surveillance.

5. Conflict of Interest

Author has no conflict of interest to declare.

6. Source of Funding

No funding source.

References

1. Goorochurn R, Viennet C, Granger C, Fanian F, Varin-Blank N, Roy CL, et al. Biological processes in solar lentigo: insights brought by experimental models. *Exp Dermatol*. 2016;25(3):174–7.
2. Byrom L, Barksdale S, Weedon D, Muir J. Unstable solar lentigo: A defined separate entity. *Australas J Dermatol*. 2016;57(3):229–34.
3. Bartolomeo LD, Guarneri F, Moretti G. Treatment of solar lentigo with imiquimod 3.75% cream: A dermoscopic study. *J Cosmet Dermatol*. 2022;21(11):6487–9.
4. Park JH, Lee JH, Chung BY, Kim JE, Shin JH, Oh SH, et al. Can we predict postinflammatory hyperpigmentation after laser treatment based on dermoscopic findings of solar lentigo. *Lasers Med Sci*. 2023;38(1):130.
5. Shatkin M, Helm MF, Muhlbauer A, Chung CG. Solar lentigo evolving into fatal metastatic melanoma in a patient who initially refused surgery. *North Am J Med Sci*. 2020;1(1):28–31.
6. Masarutanaka M, Sawada M, Kobayashi K. Ken Kobayashi Key points in dermoscopic differentiation between lentigo maligna and solar lentigo. *J Dermatol*. 2011;38(1):53–8.
7. Imokawa G. Melanocyte Activation Mechanisms and Rational Therapeutic Treatments of Solar Lentigos. *Int J Mol Sci*. 2019;20(15):3666. doi:10.3390/ijms20153666.
8. Aoki H, Moro O, Tagami H, Kishimoto J. Gene expression profiling analysis of solar lentigo in relation to immunohistochemical characteristics. *Br J Dermatol*. 2007;156(6):1214–23.
9. Choi W, Yin L, Smuda C, Batzer J, Hearing VJ, Kolbe L, et al. Molecular and histological characterization of age spots. *Exp Dermatol*. 2017;26(3):242–8.

Author biography

Benazir Hakim, Junior Resident


Oindrila Dutta, Junior Resident

Madhobendra Nath Sarkar, Junior Resident

Bhaskar Mitra, Consultant Pathologist

Chinjitha T Davis, Senior Resident

Soumi Biswas, Junior Resident

Smriti Choudhary, Consultant Dermatologist  <https://orcid.org/0000-0001-9430-2939>

Arun Achar, Professor and HOD  <https://orcid.org/0000-0002-9982-2738>

Cite this article: Hakim B, Dutta O, Sarkar MN, Davis CT, Biswas S, Choudhary S, Achar A, Mitra B. Unstable solar lentigo mimicking lentigo maligna melanoma: A case report. *IP Indian J Clin Exp Dermatol* 2023;9(3):169-172.