



Original Research Article

Methotrexate toxicity encountered in dermatology department: A retrospective study at tertiary care center in western India

Bhavana Bharatbhai Bhabhor¹, Jay Dhirajlal Modha^{1*}, Bharati Kamlesh Patel¹, Neela Vishanjibhai Bhuptani¹

¹Dept. of Dermatology, PDU Medical College & Hospital, Rajkot, Gujarat, India



ARTICLE INFO

Article history:

Received 21-07-2023

Accepted 30-10-2023

Available online 05-01-2023

Keywords:

Methotrexate toxicity

Overdosing

Organ toxicity

Management of methotrexate-induced toxicity

Treatment

ABSTRACT

Background: Methotrexate (MTX) is considered a relatively safe drug when prescribed at dose ranging from 7.5mg-30mg per week. Severe acute toxicity is rare and present with mucositis, cutaneous ulceration and pancytopenia. Most cases occur as the result of inadvertent overdosing due to erroneously taking the drug daily.

Materials and Methods: A retrospective study of 10 cases of acute methotrexate toxicity in patients attending the dermatology OPD at P. D. U govt. medical College and hospital, Rajkot during a period of 1 year was done.

Results: Out of 10 patients, 7 had both oral and cutaneous involvement, 4 had genital mucosal involvement while 2 cases had only oral ulcerations. Organ-specific toxicities include pancytopenia in all cases, as well as hepatotoxicity, renal toxicity, and GI toxicity in 3 patients. Additionally, cutaneous toxicity was observed in 6 cases. "Of the 10 patients, 2 recovered after stopping methotrexate with supportive care. The remaining 8 received injectable folinic acid, resulting in recovery for 6 patients, but 2 patients unfortunately died during treatment.

Conclusion: Although MTX appears to be a safe and effective medication when used at low-dose, acute MTX toxicity can be a life-threatening emergency when comorbidities are not addressed. Sensitization amongst doctors, general practitioners and resident doctors is of paramount importance to identify possible MTX toxicity in early phases and in a way ensure earliest management.

This is an Open Access (OA) journal, and articles are distributed under the terms of the [Creative Commons Attribution-NonCommercial-ShareAlike 4.0 License](https://creativecommons.org/licenses/by-nc-sa/4.0/), which allows others to remix, tweak, and build upon the work non-commercially, as long as appropriate credit is given and the new creations are licensed under the identical terms.

For reprints contact: reprint@ipinnovative.com

1. Introduction

Methotrexate, due to its effectiveness and inexpensive cost, is still one of the most widely recommended systemic immunosuppressive drugs in dermatology. Methotrexate causes acute toxicity by blocking DNA synthesis in rapidly proliferating cells such as the gastrointestinal (GI) tract, haematopoietic cells, and cells on psoriatic lesions. Hence, acute methotrexate toxicity causes low blood counts, nausea, vomiting, black stools, skin and mucosal erosion and ulceration.¹ The risk of toxicity is greater if

additional methotrexate is administered sooner than the usual scheduled weekly dose.²

The present case series focuses on the aforementioned elements, as well as clinical presentations, systemic consequences, methotrexate toxicity risk factors, and case outcomes.

2. Case Report

Total 10 patients are included in case series, out of which 5 were males and 5 were females. The cases are pertaining to three diseases i.e. Psoriasis, rheumatoid arthritis and discoid lupus erythematosus. Age of the patients ranged

* Corresponding author.

E-mail address: drmodhajay@gmail.com (J. D. Modha).

from 38-70 years with mean age of 64 years. 7 cases had both oral and cutaneous involvement, 4 had genital mucosa involvement, while only oral ulceration was present in 2 cases. Organ specific toxicities were observed in our case series. 7 patients had cutaneous toxicity. Pancytopenia and mucositis were seen in all cases, while hepatotoxicity and acute renal failure in 3 cases. Demographic details, clinical manifestations, Skin and mucosa findings, various reasons for overdosing, acute cumulative dose resulting in toxicity and duration to achieve acute toxic cumulative dose of all cases have been illustrated in Table 1. Systemic complications, risk factors and outcome of the cases have been described in Table 2.

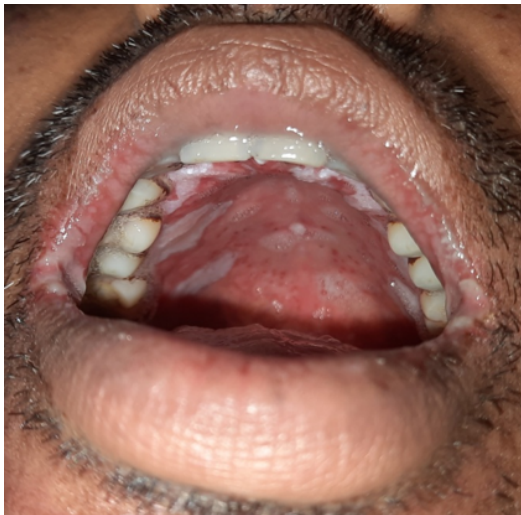

Figure 1: Multiple ulcers present in oral cavity

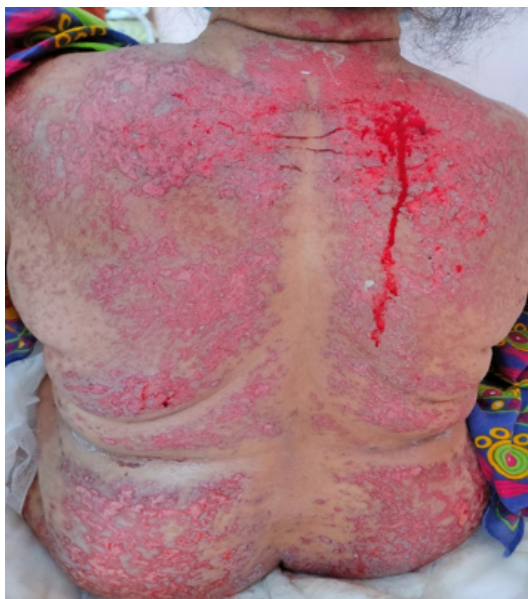

Figure 2: Ulceration over psoriatic plaques.

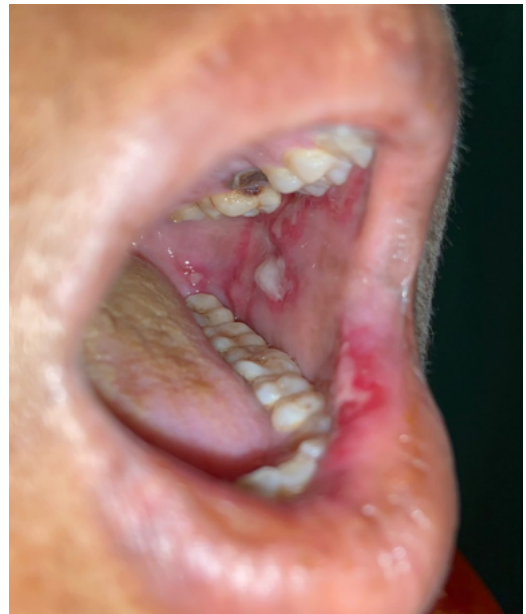

Figure 3: Multiple erosion presents over buccal mucosa.

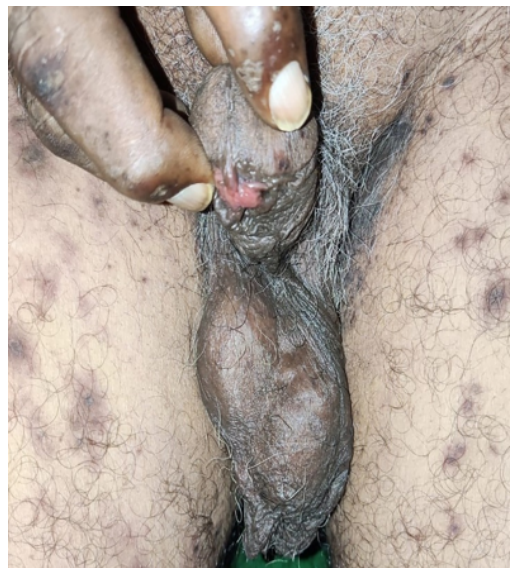

Figure 4: Perilesional erythema along with ulceration over psoriatic plaques.

Daily monitoring of serum methotrexate level could not be done due to cost factor and unavailability of the investigation at our institute. 8 patients were given injection folinic acid and 4 of them were also given injection filgrastim 300mcg/day subcutaneously till total leucocyte count came to 4000/cumm. Skin erosions were managed with aseptic barrier dressing using vaselinated gauze. None of our patients presented at day 1 with skin manifestations. In spite of all the treatment measures 2 patients died due to grossly deranged liver function, renal function and

Table 1: Demographic details, Acute Cumulative toxic dose, duration, Skin and mucosal signs and Reasons for consuming toxic dose of Methotrexate

Case number	Indication of Methotrexate	Age/sex	Acute cumulative dose	Duration of intake of acute cumulative dose	Skin and mucosa findings	Reasons for overdosing
1	Psoriasis	70/M	30mg (5mg/day)	6 days	Skin- erosion within psoriatic plaques on the trunk, both upper & lower limbs along with palms & soles. Mucosa-oral & genital mucosal ulcerations.	General physician prescription error
2	Psoriasis	38/M	30mg(10mg/day)	3 days	Skin- superficial erosion within psoriatic plaques on 50% of body surface area. Mucosa- oral& genital mucosal ulcerations	Out of frustration, self-medication because of prolonged disease course
3	Rheumatoid arthritis	65/F	30mg(10mg/day)	3 days	Skin- erosion within psoriatic plaques on the necklines, abdomen, both upper & lower limbs Mucosa-oral ulcerations	Accidental overconsumption
4	Rheumatoid arthritis	50/F	200MG (50mg/week)	1 Month	Skin- nil Mucosa- Oral& genital ulcerations	Did not understand the dosing schedule
5	Psoriasis	50/M	17.5mg (2.5mg /day)	7 days	Skin-nil Mucosa-oral ulcerations	Accidental consumption
6	DLE	51/M	37.5mg (7.5mg/week 1pulse, 15mg/week2pulse)	1 week	Skin-nil Mucosa-oral & genital ulcerations	Unidentified
7	Psoriasis	63/F	35mg (Injection folitrax 15mg/ml, tablet MTX 5mg alternate day)	2 Week	Skin-Ulcerated erythematous psoriatic plaques on 50% of body surface area. Mucosa-oral ulcerations	Did not understand the dosing schedule
8	Psoriasis	45/M	22.5m(7.5mg /day for 3days for 1 week)	3days	Skin-erythema, ulcerations and bleeding from psoriatic plaques. Mucosa- oral ulcerations	Accidental consumption
9	Psoriasis	50/F	15MG(7.5mg/day)	2 days	Skin-erosion within psoriatic plaques on the trunk, both upper & lower limbs along with palms & soles Mucosa-ulcerations	Advised by physician
10	Rheumatoid arthritis	48/F	52.5MG(7.5mg/day)	1week	Skin-nil Mucosa-Oral ulceration	Advised by physician

pancytopenia leading to septicemia. In other cases, skin & mucosal erosions with ulcerations improved with treatment. Average duration for recovery was 2 weeks. All patients received counseling regarding the disease course, dosing schedule of methotrexate and possible consequences of methotrexate overdosing.

3. Discussion

Methotrexate (MTX), an antineoplastic drug, has been used successfully in the treatment of a number of dermatologic diseases. MTX can be taken orally, subcutaneously, or intramuscularly, and depending on the therapeutic reason,

it can be given once weekly or in three twelve hourly doses. The medication is a folate analogue that inhibits the enzyme dihydrofolate reductase that reduces thymidylate synthesis and, eventually, pyrimidine biosynthesis, a key nucleic acid base that produces cytosine, thymine, and uracil. It gets polyglutaminated to active form inside cell and thereby it stays in cell for a long period when taken daily or in divided doses. The cells that effectively polyglutamate methotrexate includes leukemic myeloblasts, macrophages, lymphoblasts and dividing epithelial cells.³ MTX functions as an anti-inflammatory and immunomodulator at low doses. It works as an antimetabolite at large dosage.

Table 2: Hematological changes and treatment out come in acute methotrexate toxicity

Case number	Systemic abnormalities	Risk factors	Outcome
1	Hemoglobin level 8.5-g/dl, Total Leucocyte count- 750/cumm Thrombocytopenia-80,000/cumm, Serum urea-70mg/dl(N-15-40mg/dl), Serum creatinine-4.2mg/dl(N-0.7-1.3mg/dl) , SGOT-120U/L(N-0-37U/L) SGPT-180U/L (N-0-40 U/L)	Old age	Death
2	Hemoglobin level-10.6g/dl, Total Leucocyte count- 4500/cumm Thrombocytopenia-1,00,000/cumm,	Administered drug sooner than the usual scheduled weekly dose.	Recovered
3	Hemoglobin level-10g/dl, Total Leucocyte count- 2500/cumm Thrombocytopenia-1,20,000/cumm,	Intake of diclofenac along with methotrexate for joint pain	Recovered
4	Hemoglobin level-8.0g/dl, Total Leucocyte count- 800/cumm Thrombocytopenia-92,000/cumm, Serum urea-60mg/dl(N-15-40mg/dl), Serum creatinine-3.2mg/dl(N-0.7-1.3mg/dl) SGOT-48U/L(N-0-37U/L) SGPT-60U/L (N-0-40 U/L),	Intake of diclofenac along with methotrexate for joint pain	Recovered
5	Hemoglobin level-9.6g/dl, Total Leucocyte count- 2500/cumm Thrombocytopenia-82,000/cumm,	-	Recovered
6	Hemoglobin level-11g/dl, Total Leucocyte count- 4700/cumm Thrombocytopenia-86,000/cumm,	-	Recovered
7	Hemoglobin level-11.6g/dl, Total Leucocyte count- 3500/cumm Thrombocytopenia-92,000/cumm	Old age	Recovered
8	hemoglobin level-7.4g/dl, Total Leucocyte count- 2900/cumm Thrombocytopenia-44,000/cumm	Administered drug sooner than the usual scheduled weekly dose.	Recovered
9	hemoglobin level-8.0g/dl, Total Leucocyte count- 500/cumm Thrombocytopenia-1,40,000/cumm, Serum urea-50mg/dl(N-15-40mg/dl), Serum creatinine-11.2mg/dl(N-0.7-1.3mg/dl), SGOT-48U/L(N-0-37U/L) SGPT-60U/L (N-0-40 U/L)	Pre-existing chronic renal failure	DEATH
10	hemoglobin level-9.6g/dl, Total Leucocyte count- 5000/cumm Thrombocytopenia-56,000/cumm,	Administered drug sooner than the usual scheduled weekly dose.	Recovered

SGPT = Serum glutamate pyruvate transaminase, SGOT = Serum glutamate oxaloacetate transferase

Because of its mechanism of action, MTX can cause a variety of side effects and should be taken with caution. Methotrexate toxicity is rare with low dose and can be avoided with correct scheduling of the dose and adherence to the recommended guidelines.⁴

Acute renal failure, hypoalbuminemia, and concomitant use of medications known to interact with MTX are risk factors for developing MTX toxicity. Salicylates and nonsteroidal anti-inflammatory medications (NSAIDs) can increase blood level of MTX by reducing MTX renal clearance and tubular secretion, while trimethoprim/sulfamethoxazole can enhance the cytotoxic effects of MTX as trimethoprim is an antifolate reductase inhibitor.⁵ In present case series 2 patients had a history of concomitant intake of paracetamol and diclofenac for joint pain which could have increased the blood level of methotrexate by decreasing renal excretion which is similar

to the 2 cases reported by Jariwala et al.¹ One patient of chronic renal failure was given tab methotrexate without awareness of renal profile by Rural Medical practitioner that ultimately led to the MTX toxicity.

Overdosing, whether unintentional or due to self-medication, was discovered to be the most frequent cause of drug toxicity. 9 patients were taking the drug above the prescribed dose due to poor understanding of the regimen. Prior to starting the drug, patients must be counselled on the course of the disease, the drug regimen, and the side effects.⁶

Other risk factors that contribute to methotrexate toxicity include renal insufficiency (Methotrexate is excreted via renal system), infection, pustular psoriasis, and age >55 years.⁷ In our study, 3 cases (1, 3 and 7) where age is >55 years which could be an additional risk factor for toxicity along with overdosing.

3.1. Mtx induced organ toxicity

MTX toxicity affects critical organs and tissues in the body, including the skin, gastrointestinal mucosa, kidney, liver, and bone marrow. Manifestation in various multiple systemic forms includes hepatotoxicity, pulmonary toxicity, acute renal failure, stomatitis, ulceration/erosion of the gastrointestinal tract and pancytopenia.⁸

3.1.1. Hematological toxicity

All patients had MTX induced pancytopenia which manifested as oral ulcers fever, fatigue, vomiting, abdominal pain, diarrhea, nasal and gum bleeding. Injection filgrastim was given to 4 patients (1, 4, 7 and 9) while injection folic acid, higher antibiotics, antifungal, and symptomatic treatment was given to all patients following which 8 patients (case 2, 3, 4, 5, 6, 7, 8 and 10) had recovered and 2 (case 1 and 9) patients died due to acute renal failure. Pancytopenia can occur early, within 1–2 months of starting MTX, possibly due to an idiosyncratic reaction; however, most of the time it occurs late, suggesting a cumulative effect.⁹ In our case series all patients presented with pancytopenia within 2 months after starting of treatment. Although we did not study genetic polymorphism due to limited resources, previous studies have shown association of cytopenia with C677T and 1298A A polymorphism.^{10,11} Pancytopenia may occur even after years of treatment; 4 patients (case 2, 3, 5 and 7) in present case series had received MTX for more than 4 years which similar to study done by S. Ajmani et al. Thus, monitoring is crucial even in patients who are on MTX for long periods.

3.1.2. Renal toxicity

MTX-induced renal dysfunction either by precipitation of MTX and its metabolites in the renal tubules or directly toxic effect to the kidney and delay MTX clearance may increase the risk of renal toxicities and subsequently promote systemic toxicities such as GI, hematological, hepatic, and dermatological toxicities.^{12,13} our study 3 patients (case 1, 4 and 9) had renal toxicities in form of acute renal failure, elevated creatinine and urea level which manifested as breathlessness, drowsiness and oliguria. The dose of MTX used orally was ranged from 15 to 200mg. All patients were treated with folic acid, filgrastim, diuretics and supportive care. In spite all treatment measures 2 (case 1 and 9) patients died due to acute renal failure and 1 (case 4) patient recovered.

3.1.3. Hepatic toxicity

Hepatic toxicity, often observed in clinical practice with oral methotrexate (MTX) therapy, is the most common adverse effect, presenting as elevated liver enzymes. Additionally, long-term MTX administration can lead to liver cirrhosis and hepatic fibrosis. Several studies have reported the occurrence of liver cirrhosis and fibrosis after 4 years

of MTX use.^{14,15} Here, Hepatic toxicity was seen in 3 cases (case 1, 4 and 9) where 2 (case 1 and 4) had fatty liver changes and all 3 had elevated liver enzymes. All were given injection folic acid, filgrastim, symptomatic treatment, supportive care, following which 1 patient (case 4) recovered and 2 patients (case 1 and 9) died due to acute renal failure.

3.1.4. Cutaneous toxicity

Low dose MTX-induced cutaneous adverse effect including cutaneous erosions and ulceration seems to be very rare.¹⁶ In our study 7 (case 1, 2, 3, 4, 7, 8 and 9) patients had MTX induced cutaneous toxicities in form of cutaneous ulcers and skin rash. The dose of MTX used orally was ranging from 15mg to 200mg, with dosing frequency ranging from daily once to weekly once. On examination mucocutaneous ulcers were seen over the buccal cavity, face, trunk, abdomen lower and upper limbs. Injection folic acid, filgrastim, higher antibiotics and symptomatic treatment was given to all patients, while injection filgrastim was given to 4 patients (1, 4, 7 and 9) following which 5 (case 2, 3, 4, 7 and 8) patients recovered and 2 (Case 1 and 9) died due to acute renal failure.

3.1.5. GI toxicity

Methotrexate (MTX) can cause gastrointestinal (GI) toxicity, which may result in symptoms such as mucositis, nausea, loose stool, stomatitis and peptic ulcer.^{17,18} In our study 3 patients (case 2, 9, and 10) had GI toxicities in the form of oral mucositis, dysphagia, abdominal pain and ulcerative stomatitis. The dose of MTX used orally was ranged from 15 to 50mg. Injection folic acid, higher antibiotics, antifungal, and symptomatic treatment was given to all three patients were injection filgrastim was given to only one patient (case 9) following which 2 (case 2 and 10) patients recovered and another (case 9) died due to acute renal failure.

Treatment of methotrexate toxicity is usually by folic acid Rescue therapy. Ideally, the dose of folic acid is usually decided according to level of serum methotrexate and duration of overdosing.¹⁹ Several studies have reported that the lack of an initial increase in leucovorin dosage led to fatalities.^{19–22} Methotrexate toxicity is usually treated with three standard approaches: maintain MTX serum levels, ensuring proper hydration and enhancing MTX excretion. Average duration for recovery was 2 weeks. However, acute cumulative toxic dose and duration required to achieve the toxic cumulative dose of methotrexate is unclear. In present cases series we observed acute cumulative dose of methotrexate ranging from 15 mg to 200 mg. The most common cause of drug overdose is due to self – medication of tablet methotrexate to achieve rapid or permanent cure from disease. This is similar to the cases reported by Agarwal et al. and Jariwala et al.

4. Conclusion

Based on the current experience, we believe that counselling about the course of disease, methotrexate dosing schedule, and the consequences of methotrexate overdosing should be mandatory for all patients in countries like India, where drug regulation is lax and patients frequently buy medications over-the-counter and resort to self-medication. Also, sensitization of physicians and dermatologists are of paramount importance to clinch the signs of MTX toxicity at the earliest to avoid morbidity and mortality.

5. Source of Funding

None.

6. Conflict of Interest


None.

References

1. Agarwal KK, Nath AK, Thappa DM. Indian J Dermatol Venereol Leprol. *Indian J Dermatol*. 2008;74(5):481–4.
2. Bleyer WA. Methotrexate: clinical pharmacology, current status and therapeutic guidelines. *Cancer Treatment Rev*. 1977;4(2):87–101.
3. Roenigk HH, Auerbach R, Maibach HI, Weinstein GD. Methotrexate in psoriasis. *Arch Dermatol*. 1972;105(3):363–5.
4. Morgan SL, Baggott JE, Vaughn WH, Austin JS, Veitch TA, Lee JY, et al. Supplementation with folic acid during methotrexate therapy for rheumatoid arthritis. A double-blind, placebo-controlled trial. *Ann Intern Med*. 1994;121(11):833–41.
5. Bourré-Tessier J, Haraoui B. Methotrexate drug interactions in the treatment of rheumatoid arthritis: A systematic review. *J Rheumatol*. 2010;37(7):1416–21.
6. Pradhan S, Sirka CS, Rout AN, Dash G, Sahu K. Acute methotrexate toxicity due to overdosing in psoriasis: A series of seven cases. *Indian Dermatol Online J*. 2019;10(1):64–8.
7. Pearce HP, Wilson BB. Erosion of psoriatic plaques: An early sign of methotrexate toxicity. *J Am Acad Dermatol*. 1996;35(5 Pt 2):835–8.
8. Olsen EA. The pharmacology of methotrexate. *J Am Acad Dermatol*. 1993;25(2 Pt 1):300–18.
9. Grove ML, Hassell AB, Hay EM, Shadforth MF. Shadforth MF Adverse reactions to disease-modifying anti-rheumatic drugs in clinical practice. *QJM*. 2001;94(4):309–19.
10. Ulrich CM, Yasui Y, Storb R, Schubert MM, Wagner JL, Bigler J, et al. Pharmacogenetics of methotrexate: toxicity among marrow transplantation patients varies with the methylenetetrahydrofolate reductase C677T polymorphism. *Blood*. 2001;98(1):231–4.
11. Berkun Y, Levartovsky D, Rubinow A, Orbach H, Aamar S, Grenader T, et al. Methotrexate related adverse effects in patients with rheumatoid arthritis are associated with the A1298C polymorphism of the MTHFR gene. *Ann Rheum Dis*. 2004;63(10):1227–31.
12. Weidmann A, Foulkes AC, Kirkham N, Reynolds NJ. Methotrexate toxicity during treatment of chronic plaque psoriasis: A case report and review of the literature. *Dermatol Ther (Heidelb)*. 2014;4(2):145–56.
13. Strang A, Pullar T. Methotrexate toxicity induced by acute renal failure. *J Theroyal Soc Med*. 2004;97(11):536–7.
14. Romão VC, Lima A, Bernardes M, Canhão H, Fonseca JE. Three decades of low-dose methotrexate in rheumatoid arthritis: Can we predict toxicity? *Immunol Res*. 2014;60(2-3):289–10.
15. Osuga T, Ikura Y, Kadota C, Hirano S, Iwai Y, Hayakumo T, et al. Significance of liver biopsy for the evaluation of methotrexate-induced liver damage in patients with rheumatoid arthritis. *Int J Clin Exp Pathol*. 2015;8(2):1961–6.
16. Tekur VK. Methotrexate-induced nonhealing cutaneous ulcers in a nonpsoriatic patient without pancytopenia. *Indian Dermatol Online J*. 2016;7(5):418–20.
17. Chen Y, Zou K, Sun J, Yang Y, Liu G. Are gene polymorphisms related to treatment outcomes of methotrexate in patients with rheumatoid arthritis? A systematic review and meta-analysis. *Pharmacogenomics*. 2017;18(2):175–95.
18. Chamorro-Petronacci C, García-García A, Lorenzo-Pouso AI, Gómez-García FJ, Padín-Iruegas ME, Gándara-Vila P, et al. Management options for low-dose methotrexate-induced oral ulcers: A systematic review. *Med Oral Patol Oral Cir Bucal*. 2019;24(2):181–9.
19. Madke B, Singh AL. Acute methotrexate toxicity. *Indian J Drugs Dermatol*. 2015;1(1):46–9.
20. Bateman DN, Page CB. Antidotes to coumarins, isoniazid, methotrexate and thyroxine, toxins that work via metabolic processes. *Br J Clin Pharmacol*. 2016;81(3):437–45.
21. Howard SC, McCormick J, Pui CH, Buddington RK, Harvey RD. Preventing and managing toxicities of high-dose methotrexate. *Oncologist*. 2016;21(12):1471–82.
22. Widemann BC, Adamson PC. Understanding and managing methotrexate nephrotoxicity. *Oncologist*. 2006;11(6):694–703.

Author biography

Bhavana Bharatbhai Bhabhor, Resident

Jay Dhirajlal Modha, Assistant Professor  <https://orcid.org/0000-0003-0932-6982>

Bharati Kamlesh Patel, Professor and Dean

Neela Vishanjibhai Bhuptani, Professor and HOD

Cite this article: Bhabhor BB, Modha JD, Patel BK, Bhuptani NV. Methotrexate toxicity encountered in dermatology department: A retrospective study at tertiary care center in western India. *IP Indian J Clin Exp Dermatol* 2023;9(4):216–221.