



## Case Report

# Lamotrigine induced toxic epidermal necrolysis in an epileptic child: A wrath of polypharmacy? - A case report

Divya EJ<sup>1</sup>, Poorana B<sup>2</sup>, Chidambaranathan S<sup>1</sup>, P K Kaviarasan<sup>3\*</sup>

<sup>1</sup>Dept. of Paediatrics, Govt. Cuddalore Medical College, Chidambaram, Tamil Nadu, India

<sup>2</sup>Dept. of Dermatology, Govt. Cuddalore Medical College, Chidambaram, Tamil Nadu, India

<sup>3</sup>Dept. of Dermatology Venereology and Leprosy, Rajah Muthiah Medical College and Hospital, Annamalai University, Chidambaram, Tamil Nadu, India



## ARTICLE INFO

### Article history:

Received 05-10-2023

Accepted 27-11-2023

Available online 05-01-2023

### Keywords:

Adverse drug reaction

Lamotrigine

Sodium Valproate

TEN

Toxic epidermal necrolysis

## ABSTRACT

Toxic Epidermal Necrolysis (TEN) is a severe form of adverse drug reaction (ADR) characterized by extensive areas of necrotic blisters, erosions of the skin and mucosal membranes. Antiepileptics are the leading cause of TEN. We report a five and half year old male child, a known case of seizure disorder "Juvenile myoclonic epilepsy" since 2 years. The child was treated with sodium valproate (VPA), levetiracetam and lamotrigine(LTG). This triple combination therapy dramatically controlled the seizures. But within three weeks, there were extensive urticarial rashes, which rapidly become necrotic, haemorrhagic, vesiculobullous suggestive of TEN involving more than 40% body surface area (BSA). The child was managed successfully, by conservative measures, without IVIG or biologics, simply by stopping the AEDs, corticosteroids, and wound care with wet collagen dressings, in a rural set up, was a challenging scenario. Hence we report this case. Conclusion: Childhood TEN is rare but preventable. VPA inhibits LTG clearance, cause TEN and can worsen the prognosis.

This is an Open Access (OA) journal, and articles are distributed under the terms of the [Creative Commons Attribution-NonCommercial-ShareAlike 4.0 License](https://creativecommons.org/licenses/by-nc-sa/4.0/), which allows others to remix, tweak, and build upon the work non-commercially, as long as appropriate credit is given and the new creations are licensed under the identical terms.

For reprints contact: [reprint@ipinnovative.com](mailto:reprint@ipinnovative.com)

## 1. Introduction

Lamotrigine (LTG) is a common antiepileptic drug (AED) is effective against focal and generalized form of seizure disorders (SD). Myoclonic seizures known as "juvenile myoclonic epilepsy" (JME), results from abnormal neuronal activation of cortical or subcortical region of brain. JME is characterized by sudden, brief, non-sustained involuntary jerks, lasting for less than 100 msec.<sup>1</sup> JME is treated with AEDs include, levetiracetam, piracetam, valproic acid, clonazepam, zonisamide, pirimidone, cabamazepine and lamotrigine (LTG). LTG is used as a first-line drug for primary focal or generalized tonic-clonic seizures, include simple and complex partial seizures.<sup>2</sup> Concomitant

therapy of AEDs can cause Stevens-Johnson Syndrome (SJS) and Toxic Epidermal Necrolysis (TEN). TEN is a potentially fatal disorder affecting skin and mucosa causing widespread epidermal necrosis, associated with mortality rate 15% to 25%.<sup>3</sup>

## 2. Case Report

A Five-year male child, born to nonconsanguineous parent, was diagnosed as a case of "juvenile myoclonic epilepsy" (JME) since 2 years of age. The child was initially treated with VPA at 20 mg /kg/day for nearly 2 years. The frequency and severity of JME was increased and each episode was lasting for 15-30 secs. Levetiracetam (LEV) (20 mg/kg/day), was added to VPA since 6 months. In spite of dual AED therapy his JME continued to worsen.

\* Corresponding author.

E-mail address: [kaviderm@gmail.com](mailto:kaviderm@gmail.com) (P. K. Kaviarasan).

Lamotrigine (LTG) 25 mg (adjuvant therapy) alternate days for initial two weeks and increased to 50 mg for next 2 weeks. Within 3 weeks of triple regimen, the child suddenly developed urticarial rash involving the face, upper limb, trunk was treated with antihistamines [Figure 1]. On day 5 of illness the child was brought to paediatric casualty. The child was lethargic, febrile, dehydrated. On examination, widespread large necrotic blisters, erosions, haemorrhagic crusting involving skin, oral, eyes and anogenital mucosae (>40% of body surface) was suggestive of TEN [Figure 2A,B,C]. Nikolsky sign was positive. Target lesions were seen over acral skin, palms and soles [Figure 3]. Electroencephalography (EEG) revealed, bilateral generalised epileptiform discharges with hypersarrhythmia. Computed tomography (CT), and magnetic resonance imaging (MRI) of the brain both were normal. Tzanck smear was negative for acantholytic cells.<sup>3</sup>

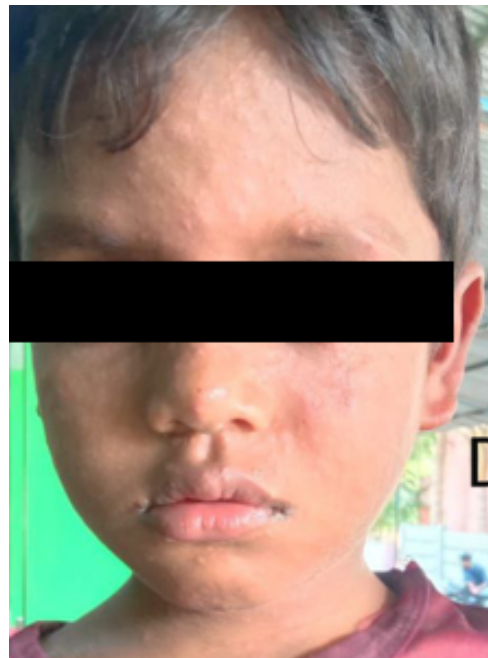The child was managed in paediatric at intensive care unit with strictly barrier nursing measures. Investigational workup revealed anaemia (Hb- 9gms/dl), mild leucocytosis, eosinophilia and no atypical cells. All the biochemical, microbiological and urine analysis tests were normal except raised acute phase reactants. Screening for HIV, HBV, HCV and HSV serology were negative. Bacterial culture and sensitivity of pus, blood and urine revealed no growth.

Genetic analysis with whole genome sequencing was done which showed a heterozygous nonsense variant in Exon 11 of CILK1 gene and a heterozygous missense variant in Exon 9 of KCNQ3 gene. LTG was stopped immediately on the basis of Alden score (LTG -Alden score of 6 probable cause). The child was treated with diazepam and topiramate 25mg/ day, hydrocortisone (12.5 mg/m<sup>2</sup> IV every 6 hours), antibiotics, and adequate hydration for the initial five days. Two units of packed cells were given. Skin lesions were managed with wet collagen sheets, silver sulfadiazine impregnated paraffin gauze dressing, following normal saline compresses. Appropriate mouth care (oral washes with sodium borate) and eye care (tobramycin ophthalmic drops) were given.

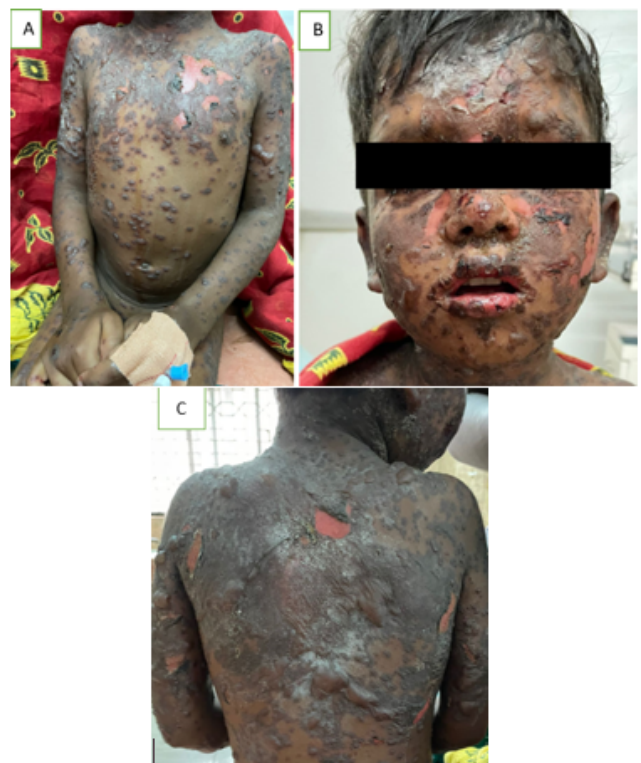The child was provided paraffin coated banana leaf to minimize the friction. With all these measures, from day five (day 10 of illness) onwards, the child started recovering, and become better, started taking oral fluids and there were no blisters or erosions. All the lesions resolved post inflammatory pigmentary changes [Figure 4]. The patient was discharged with VPA and L-carnitine after 15 days of treatment.

### 3. Discussion

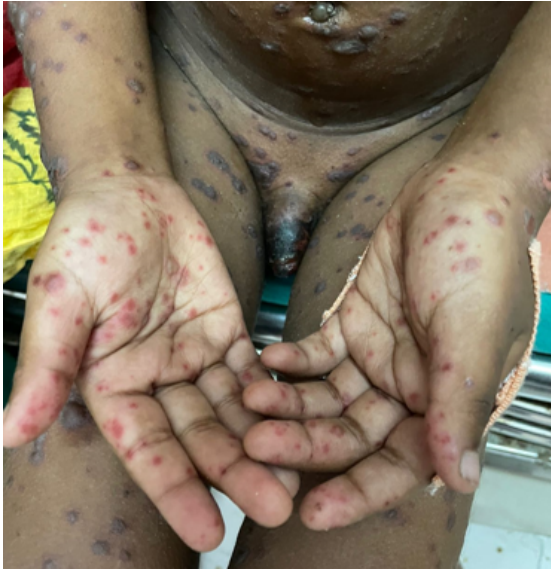TEN is also well known as Lyell syndrome first described by Alan Lyell in 1956. Mortality of TEN ranging from 15% to 25%.<sup>3</sup> Various drugs can precipitate TEN (65% to 80% cases), like antiepileptic drugs (AED), antimicrobials, allopurinol, and analgesics. Immune



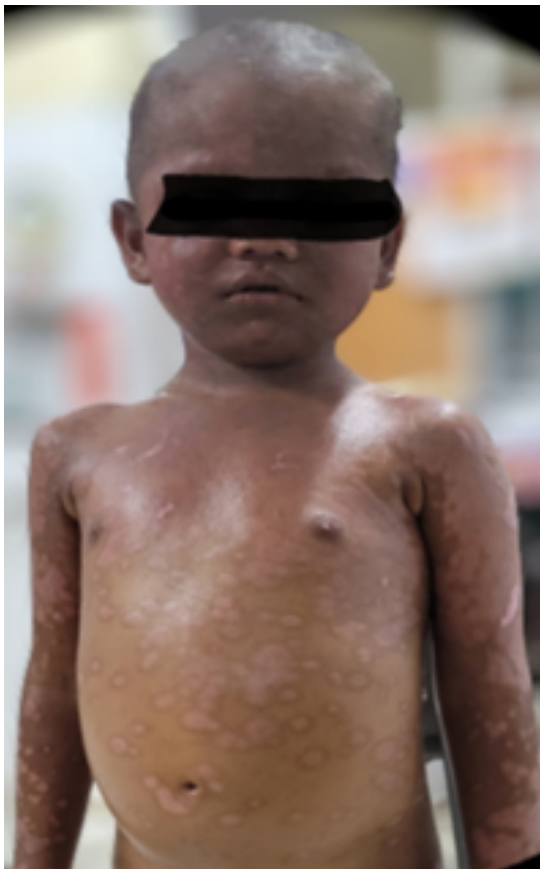**Figure 1:** Represents clinical presentation on Day 1– Maculopapular rashes in face, bilateral upper limbs



**Figure 2:** A: TEN lesions on day 5 reveal extensive necrotic blisters with exfoliation affecting upper trunk and arms; B: Severe TEN lesions affecting face, lips and conjunctiva on day 5; C: Extensive TEN lesions, manifested as large hemorrhagic blisters and erosions on day 5 of illness.



**Figure 3:** Targetoid lesions of TEN appearing over palms and soles on Day 5 illness



**Figure 4:** Completed recovery of Lamotrigine induced TEN on day 10 reveal post inflammatory pigmentary changes.

dysregulation, infections, vaccination, active malignancy rarely cause TEN in genetically predisposed individuals.<sup>4</sup> Median duration for LTG causing TEN is 17 days and dosage is 50 mg for SJS and 87.5 mg for TEN. Lamotrigine toxicity occurs with 16 g/ day dose, develop seizures, coma, conduction abnormalities and death. Combining LTG with Valproic acid (VPA) causes SJS in 74% and TEN in 64% cases. The exact mechanism was poorly understood. Monotherapy with LTG, almost 55% bound to plasma proteins will be in circulation for 25–30 hours. VPA inhibits LTG glucuronidation, impair LTG clearance and increase the half-life of LTG to 60 hours. Arene oxide is a LTG metabolite (minor cytochrome P450 enzyme pathway), is toxic to nucleic acids, DNA, and RNA, leading to cellular damage in TEN. VPA further inhibits arene oxide detoxification by microsomal epoxide hydrolase (EPHX) and/or GSH-S-transferases and deplete glutathione levels.<sup>5,6</sup>

Screening for HLA-B\*15:02 allele (prevalent among South-East Asians) is essential. Sudden withdrawal of all AEDs at a time and rechallenging with newer AEDs will be the most challenging part. Adverse events are rare in children, mortality is also lesser 15% to 30%. Similarly recovery is also faster. Infection, sepsis and multi organ failure are common causes of mortality.

In polypharmacy induced TEN, early suspicion, timely withdrawal of the culprit drug, intensive unit care, barrier nursing, adequate hydration, early institution of systemic corticosteroids, high-dose intravenous immunoglobulins (IVIG), ciclosporin, TNF antagonists, may improve the prognosis. Recovery is indirectly proportional to TEN severity, may take a period of 14-28 days.<sup>7,8</sup> In developing countries like India, even in Govt hospitals, especially in rural areas, IVIG, plasmapheresis, biologics are not available. We successfully managed this child with TEN, following LTG polypharmacy complicated Juvenile myoclonic seizures without IVIG, by timely withdrawal, and supportive wound care, in southern district of India, was a real challenge. Hence we report this case report.

#### 4. Conclusion

Polypharmacy of various AEDs become an unavoidable option in managing recalcitrant seizure disorders, responsible for severe adverse events like TEN. Concomitant therapy with VPA and LTG, in the absence of monitoring serum drug levels, enzymes, metabolites can worsen the outcome of SJS/TEN. Early suspicion, timely intervention, and multi-disciplinary approach are the mainstay in managing such critical cases.

#### 5. Declaration of Patient Consent

The authors certify that they have obtained all appropriate patient consent forms. In the form, the patient(s) has/have

given his/her/their consent for his/her/their images and other clinical information to be reported in the journal. The patients understand that their names and initials will not be published and due efforts will be made to conceal their identity, but anonymity cannot be guaranteed.

## 6. Limitations

Skin biopsy, Serum levels of anticonvulsants, enzyme levels could not be performed.

IVIG could not be given as it was not available

## 7. Conflicts of Interest

There are no conflicts of interest.

## 8. Source of Funding

None.

## References


1. Ross S, Jankovic J. Palatal myoclonus: an unusual presentation. *Mov Disord.* 2005;20(9):1200–3.
2. Mir A, Alghamdi A, Alotaibi W, Samreen D, Alotaibi M, Albaradie R, et al. A systematic review of the efficacy of perampanel as treatment for myoclonic seizures and symptomatic myoclonus. *Epileptic Disord.* 2022;24(4):633–46.
3. Gleghorn KL, Voigt C, Kelly B. Toxic epidermal necrolysis and Stevens-Johnson syndrome/toxic epidermal necrolysis overlap in pediatric patients with a focus on newer antiepileptic drugs: A 25-year retrospective study at a single tertiary care center. *Pediatr Dermatol.* 2021;38(4):812–8.
4. Shukla S, Rastogi S, Abdi SAH, Dhamija P, Kumar V, Kalaiselvan V, et al. Severe cutaneous adverse reactions in Asians: Trends observed in culprit anti-seizure medicines using VigiBase®. *Seizure.* 2021;91:332–8. doi:10.1016/j.seizure.2021.07.011.
5. Vázquez M, Maldonado C, Guevara N, Rey A, Fagiolino P, Carozzi A, et al. Lamotrigine-Valproic Acid Interaction Leading to Stevens–Johnson Syndrome. *Case Rep Med.* 2018;p. 5371854. doi:10.1155/2018/5371854.
6. Nanau RM, Neuman MG. Adverse drug reactions induced by valproic acid. *Clin Biochem.* 2013;46(15):1323–38.
7. Mcpherson T, Exton LS, Biswas S, Creamer D, Dziewulski P, Newell L, et al. British Association of Dermatologists’ guidelines for the management of Stevens-Johnson syndrome/toxic epidermal necrolysis in children and young people. *Br J Dermatol.* 2018;181(1):37–54.
8. Hasegawa A, Abe R. Recent advances in managing and understanding Stevens-Johnson syndrome and toxic epidermal necrolysis. *F1000Res.* 1000;9:F1000 Faculty Rev–612. doi:10.12688/f1000research.24748.1.

## Author biography

**Divya EJ**, Post Graduate, Paediatrics

**Poorana B**, Assistant Professor

**Chidambaranathan S**, Associate Professor

**P K Kaviarasan**, Professor and Head of Department  
 <https://orcid.org/0000-0003-1476-9120>

**Cite this article:** Divya EJ, Poorana B, Chidambaranathan S, Kaviarasan PK. Lamotrigine induced toxic epidermal necrolysis in an epileptic child: A wrath of polypharmacy? - A case report. *IP Indian J Clin Exp Dermatol* 2023;9(4):222-225.