

Content available at: <https://www.ipinnovative.com/open-access-journals>

IP Indian Journal of Clinical and Experimental Dermatology

Journal homepage: www.ijced.org/

Original Research Article

A clinical study of Geriatric dermatoses at Tertiary care center in South India

Anupama Manohar Prasad¹, Lalitha C^{2*}, Aneeha Ramesh Babu³¹The Oxford Medical College and Research Center, Bengaluru, Karnataka, India²Siddaganga Medical College and Research Institute, Tumkur, Karnataka, India³Citizen Skin Clinic, Malleswaram, Bengaluru, Karnataka, India

ARTICLE INFO

Article history:

Received 02-01-2024

Accepted 14-02-2024

Available online 12-03-2024

Keywords:

Geriatric
Dermatosis
Xerosis
Pruritus
Eczema

ABSTRACT

Introduction: Geriatric health care has become a worldwide concern as advance in medical science has contributed to increase in average life span of an individual. Cutaneous dermatoses constitute one of the major comorbidities of elderly.**Objective:** To determine the prevalence of various skin conditions in elderly patients.**Materials and Methods:** A Total of 200 patients aged 60 and above attending Dermatology OPD at tertiary care centre for a period of six months from March to August were assessed for cutaneous dermatosis, routine investigations and histopathological examination done for relevant cases.**Results:** Out of 200 patients included in study group 128 were males (64%) and 72 females (36%), majority were in age group of 65 to 70 yrs. All patients recruited were from rural area. wrinkling was seen in >95% of cases, Generalized pruritus and xerosis was seen in 56 patient (28%) and 85 patients (42.5%) respectively, eczematous skin condition seen in 41 patients (21%) and psoriasis in 17 patients (8.5%) fissure foot in 15 (7.5%) patients. Fungal infection is the most common infection noted (7.5%) followed by viral infection herpes zoster and post herpetic neuralgia (4%), pyoderma (3.5%) and scabies (2.5%). Benign tumors like acrochordons, Dermatitis Papulosis nigra and seborrheic keratosis seen in 28% of cases. Nails changes was seen in 45% of patients.**Conclusion:** The increasing prevalence of skin condition in elderly especially pruritus and eczema, emphasizes the importance of health education regarding skin care concerning appropriate use of emollients, foot care, proper hygiene, sun protection and for early diagnosis and management of the same, such that the process of senescence allowed to live hail and healthy.This is an Open Access (OA) journal, and articles are distributed under the terms of the [Creative Commons Attribution-NonCommercial-ShareAlike 4.0 License](https://creativecommons.org/licenses/by-nc-sa/4.0/), which allows others to remix, tweak, and build upon the work non-commercially, as long as appropriate credit is given and the new creations are licensed under the identical terms.For reprints contact: reprint@ipinnovative.com

1. Introduction

Geriatric health care has become a worldwide concern as advance in medical science has contributed to increase in average life span.¹ According to 2016 report by ministry for statistics, India has 103.9 million elderly above 60yrs, constitutes about 8.5% of total population.² With life expectancy in India going up to 64yrs in males and 66.9yrs in females there is considerable rise in elderly patients

seeking dermatological opinion. Cutaneous dermatoses has become one of the major comorbidities of elderly owing to intrinsic and extrinsic skin changes in aging. This study is done to evaluate the spectrum of skin changes both physiological and pathological in the elderly population of a tertiary care hospital, the present study gives an insight into different types of dermatological problems of the aged and their incidence.

* Corresponding author.

E-mail address: drilily05@gmail.com (Lalitha C).

2. Materials and Methods

A cross sectional observational study conducted, all patients aged 60yrs and above attending Dept of dermatology venereology and leprosy at tertiary care centre between March to August were screened for cutaneous dermatoses and patients with skin lesions were included in the study, detailed history and dermatological examination was done. Routine investigations and HPE done for relevant cases. Clinical photograph and written consent taken from all patients. Institutional ethical clearance was taken.

3. Results

Out of 200 patients included in study group 128 males (64%) and 72 females (36%), majority were in age group of 65 to 70 yrs. All the recruited patients were residing at rural area, and about 65% had a poor personal hygiene practice.

Among systemic diseases 54% of patient had associated medical problems like Diabetes, 61% Hypertension and 3% had thyroid disorder.

Physiological skin changes like wrinkling and greying of hairs was seen in >95% of cases, atrophy in 27.5%, dermatoheliosis in 15% and lentigenes in 3.5% (Figures 1 and 2). Generalised pruritus and xerosis was seen in 56 patient (28%) and 85patients (42.5%) respectively.

Eczematous skin condition seen in 41 patients (21%). Figure 3 [Asteatotic eczema seen in 50% of patients followed by LSC 24% and stasis eczema 20%, infective eczema and contact dermatitis was seen in 2 and 4% respectively].

Psoriasis was seen in 17 patients (8.5%) [Palmoplantar psoriasis (11patients) was most common followed by chronic plaque psoriasis (6)]. Fissure foot in 15(7.5%) patients.

Cutaneous infections noted in 17.5% of patients, Fungal infection is the most common infection noted (7.5%) [onychomycosis (4), tinea (5), candida intertrigo (6)] followed by viral infection herpes zoster and post herpetic neuralgia (4%), pyoderma (3.5%) and scabies (2.5%) (Figures 4 and 5).

Most common pigmentary disorder seen was idiopathic guttate hypomelanosis followed by macular amyloidosis and seborrheic melanosis.

Benign tumours like acrochordons, DPN and seborrheic keratosis seen in 12% of cases.

Nail changes (Table 2) and oral pigmentations seen in 45% and 8% respectively. Hair changes seen are greying >90%, androgenic alopecia 10%, hypertrichosis of pinna 1% and hirsutism in 3% of patients (Table 2).

Other miscellaneous condition seen in our study are senile purpura, bullous pemphigoid, vitiligo, pemphigus vulgaris, benign lichenoid keratosis and basal cell carcinoma (fig 6). The various dermatosis in study group depicted in Table 1, Figure 7.

Table 1: various dermatoses seen in the study population:

Xerosis	85(42.5%)
Generalized pruritus	56(28%)
Eczema	42(21%)
Infections	35(17.5%)
Psoriasis	17(8.5%)
Fissure feet	15(7.5%)
Pigmentary disorder	
• IGH	50(25%)
• Amyloidosis	24(12%)
• Others	8(4%)
Benign tumors	
• Seborrheic keratosis	56(28%)
• DPNs	50(25%)
• Acrochordons	40(20%)
• Cherry angioma	34(17%)
Malignant/premalignant tumors	2(1%)
Others	5(2.5%)

Table 2: Various nail changes and hair changes seen in the study group:

Nail changes	Percentage
Ridging	70%
Loss of luster	85%
Onychomycosis	15%
Dystrophy	4%
Beaus line	3%
Nail psoriasis	10%
Hair changes	
Greying of hairs	>90%
Androgenic alopecia	10%
Hypertrichosis of pinna	1%
Hirsutism	3%

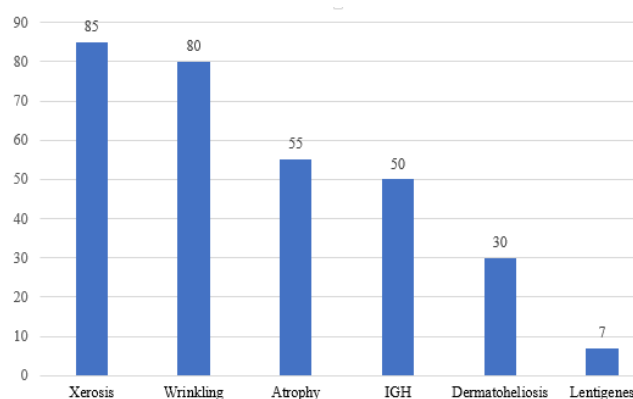


Figure 1: Physiological changes of aging

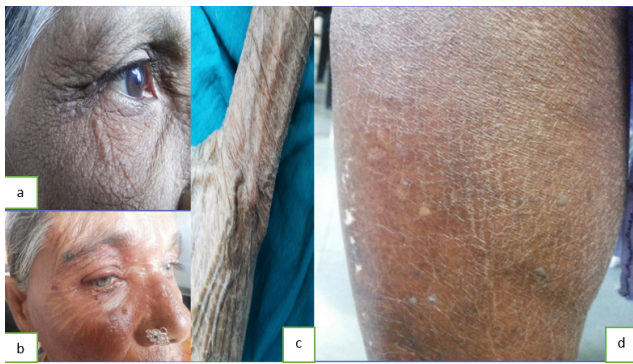


Figure 2: a: Wrinkling; b: Photoaging; c: Atrophy of the skin; d: Xerosis

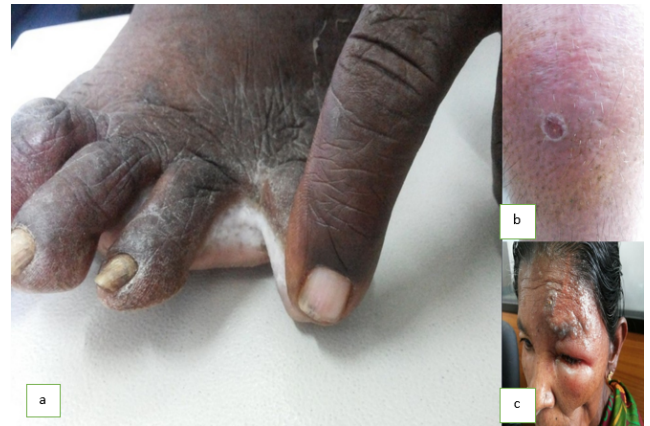

Figure 5: a: Intertrigo toe cleft; b: Furuncle; c: Herpes zoster

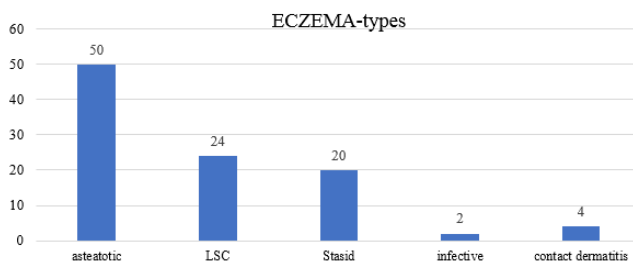


Figure 3: Graphical representation of different types of eczemas seen in the study group

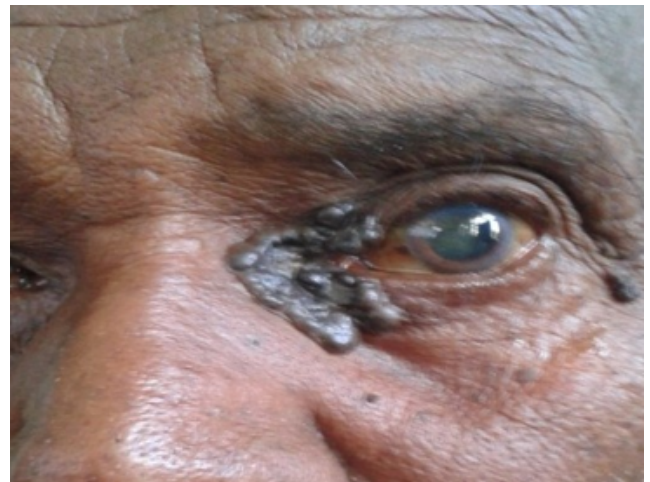

Figure 6: Basal cell carcinoma over left medial canthus.

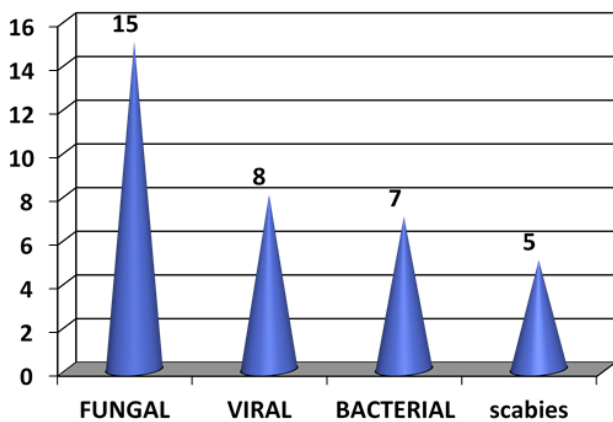


Figure 4: Pattern of Infections seen in study population.

4. Discussion

The present study was carried out on 200 patients aged 60 years and above. All patients were from rural area, the males outnumbered the females (1.7:1) which was similar to observation done by Patange S V, Fernandez R J.¹

Systemic disease association was seen in 54 % of patients which was comparable to study done by Agarwal et al,^{3,4} Development of comorbidities adds a lot of financial and psychological stress on the wellbeing of elderly patients.

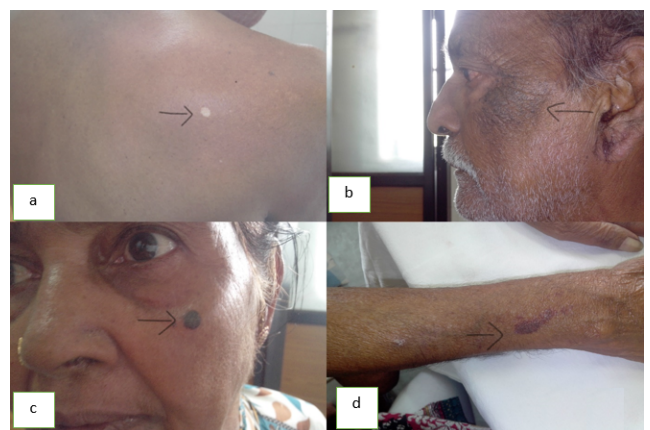

Figure 7: a: Idiopathic guttate hypomelanosis (IGH); b: Favre-Racouchot syndrome (senile comedones); c: Seborrheic keratosis; d: Senile purpura

The physiological changes seen in our study were xerosis (42.5%), atrophy (27%), followed by dermatoheliosis (15%), Which was comparable to other studies.

In our study Pruritus (28%) constituted major complaint due to xerosis and atrophic skin and due to associated dermatoses, which was lower than study conducted by Patange et al¹ (76%) and comparable to study done by Beaugard and Gilchrist⁴⁻⁶ (29%) and higher than study done by Grover S, Narasimhalu C (18.5%).⁷

Psoriasis was seen in 17 patients (8.5%) [Palmoplantar psoriasis (11patients) was most common followed by chronic plaque psoriasis (6 Patients)]. Which is slightly higher when compared to study done by Jindal R et al,⁸ where the incidence of psoriasis was found to be 5.4%.

Eczematous skin condition was seen 21% of cases which was comparable with other studies [1,6,7,15], but outnumbered the cases of asteatotic eczema (50%).The prevalence of erythemato-squamous disorders in various studies has ranged from 14.1% to 76.2%.⁹⁻¹²

The infective dermatoses constituted 17.5% of the total dermatoses. Higher than the study done by Adarsh chopra 4.5%¹³ and lower than the study done by Jindal R et al [29%]. Fungal infections (42.8% vs 17.5%) was the commonest infection noted, followed by bacterial (20% vs 8.5%) and viral (22.8% vs 5%).¹³ Aged skin is predisposed to infections due to its impaired barrier function. Maintaining proper hygiene and hydration will reduce most of these infections and infestations by improving the barrier function of the skin.^{3,9}

Fissure foot was noticed in 7.5% of patients, lower than study done by Patange et al (30%).¹

Nail changes was seen in 45% of patients the most common being lustreless and thinning of nails. In the study by Durai et al.,¹⁴ the most common nail finding observed was the loss of luster present in 254 (50.8%) individuals.

Our study was comparable with other studies in seborrheic keratosis (28% vs 34%), outnumbered in acrochordons trailed in cherry angioma and solar lentigines.^{1,3-5}

Malignant/premalignant lesion seen in 2 cases and drug reactions 2 cases which is similar to other studies.^{4,8,15}

5. Conclusion

The most common Geriatric dermatoses seen in our study are senile pruritus, xerosis, eczema, followed by infections and benign tumors like seborrheic keratosis, and acrochordons. Higher Incidence of senile pruritus and eczema emphasizes the importance of health education regarding routine skin care concerning appropriate use of emollients, foot care, proper hygiene and sun protection.

6. Source of Funding

None.

7. Conflict of Interest


None.

References

1. Patange SV, Fernandez RJ. A study of geriatric dermatoses. *Indian J Dermatol Venereol Leprol.* 1995;61(4):206–8.
2. Situation Analysis of Elderly in India. Central Statistics Office, Ministry of Statistics and Programme Implementation, Government of India; 2011. Available from: http://mospi.nic.in/mospi_new/upload/elderlyinindia.pdf.
3. Ali SY, Reddy GS, Sravanthi P. A clinical study of dermatological manifestations in geriatric patients in Shadan Institute of Medical Sciences and Teaching Hospital and Research Centre, Hyderabad, Telangana, India. *Indian J Dermatol.* 2017;3(1):24–8.
4. Agarwal R, Sharma L, Chopra A, Mitra D, Saraswat N. A Cross-Sectional Observational Study of Geriatric Dermatoses in a Tertiary Care Hospital of Northern India. *Indian Dermatol Online J.* 2019;10(5):524–9.
5. Beaugard S, Gilchrist BA. A survey of skin problems and skin care regimens in the elderly. *Arch Dermatol.* 1987;123(12):1638–43.
6. Kshetrimayum S, Thokchom NS, Vanlalhratpuii Hafi NAB. Pattern of geriatric dermatoses at a tertiary care center in North-East India. *Int J Res Dermatol.* 2017;3(4):527–34.
7. Grover S, Narasimhalu CRV. A clinical study of skin changes in geriatric population. *Indian J Dermatol.* 2009;75(3):305–6.
8. Jindal R, Jain A, Roy S, Rawat SD, Bhardwaj N. Skin Disorders Among Geriatric Population at a Tertiary Care Center in Uttarakhand. *J Clin Diagn Res.* 2016;10(3):6–8.
9. Kandwal M, Jindal R, Chauhan P, Roy S. Skin diseases in geriatrics and their effect on the quality of life: A hospital-based observational study. *J Family Med Prim Care.* 2020;9(3):1453–8.
10. Ghosh A, Jahan G, Choubey P, Chaudhary SS. Spectrum of Geriatric Dermatoses in Jharkhand. *J Dent Med Sci.* 2017;16(7):59–62.
11. Yalcin B, Tamer E, Toy GG, Oztas P, Hayran M, Alli N, et al. The prevalence of skin diseases in the elderly: analysis of 4099 geriatric patients. *Int J Dermatol.* 2006;45(6):672–6.
12. Talukdar K, Mitra D. A cross sectional observational study to evaluate various cutaneous manifestations in geriatric age group. *Int J Med Res Rev.* 2016;4(2):186–92.
13. Chopra A. Skin diseases in the elderly. *Indian J Dermatol Venereol Leprol.* 1999;65(5):245–6.
14. Durai PC, Thappa DM, Kumari R, Malathi M. Aging in elderly: chronological versus photoaging. *Indian J Dermatol.* 2012;57(5):343–52.
15. Raveendra L. A clinical study of geriatric dermatoses. *Our Dermatol Online.* 2014;5(3):235–9.

Author biography

Anupama Manohar Prasad, Associate Professor

Lalitha C, Associate Professor  <https://orcid.org/0000-0001-9347-7067>

Aneeha Ramesh Babu, Consultant Dermatologist

Cite this article: Prasad AM, Lalitha C, Babu AR. A clinical study of Geriatric dermatoses at Tertiary care center in South India. *IP Indian J Clin Exp Dermatol* 2024;10(1):19-22.