



Original Research Article

Place in therapy of topical amorolfine in the management of onychomycosis and tinea pedis: A survey to understand Indian dermatologists' perspective

Goutam Bag¹, Syed Mubashir², Dyotona Sen³, Sameer Jadhwar^{4*}¹Senior Consultant Dermatologist, Wizderm, Kolkata, West Bengal, India²Senior Consultant Dermatologist, Cosmoderm Clinic, Srinagar, Jammu & Kashmir, India³Head of medical affairs, Galderma India Pvt Ltd, Mumbai, Maharashtra, India⁴Medical Affairs Manager, Galderma India Pvt Ltd, Mumbai, Maharashtra, India

ARTICLE INFO

Article history:

Received 18-03-2024

Accepted 04-04-2024

Available online 01-06-2024

Keywords:

Nail infections

Antifungals

Amorolfine

Nail lacquer

Cream

Co-infection

ABSTRACT

Background: Several lines of evidence show that conditions like onychomycosis and tinea pedis often tend to co-exist. While topical antifungal therapy remains the cornerstone for the management of these conditions individually, data is largely scarce on effective treatment options for coexisting cases of onychomycosis and tinea pedis.

Materials and Methods: A total of 218 healthcare professionals (dermatologists and cosmetologists) participated in the online survey on amorolfine 5% nail lacquer and 0.25% cream. Through the survey, the perspectives of these healthcare professionals (dermatologists and cosmetologists) on the management of onychomycosis tinea pedis coexistence, their views on amorolfine as a treatment option, and their patient experiences were recorded.

Results: The healthcare professionals (dermatologists and cosmetologists) reported that more than 50% of the patients had recurrent onychomycosis and tinea pedis co-infection. Most patients (72.45%) were prescribed the amorolfine cream given the lower chances of resistance, and due to the synergistic effect it provides with oral antifungals. As for the amorolfine nail lacquer, good patient compliance, lower chances of infection relapse, and better penetration properties compelled healthcare professionals to prescribe the product to most patients (82.18%). Overall, good clinical and patient experiences were noted with amorolfine products.

Conclusion: This survey-based study helped us understand the healthcare professionals' take on the management of tinea pedis and onychomycosis co-infection and it revealed that amorolfine cream and nail lacquer were effective in reducing the key symptoms of tinea pedis and onychomycosis, including lesion clearance and discoloration reduction.

This is an Open Access (OA) journal, and articles are distributed under the terms of the [Creative Commons Attribution-NonCommercial-ShareAlike 4.0 License](https://creativecommons.org/licenses/by-nc-sa/4.0/), which allows others to remix, tweak, and build upon the work non-commercially, as long as appropriate credit is given and the new creations are licensed under the identical terms.

For reprints contact: reprint@ipinnovative.com

1. Introduction

Tinea pedis in general infects the sole, heel, or dorsum of the foot or areas suffering from recurring and troublesome blistering.^{1,2} Onychomycosis, on the other hand, is an infection of the nail unit, characterized by discoloration, thickening, and hardening of nails.^{3,4} *Trichophyton rubrum*

is the most common causative agent, responsible for the highest number of onychomycosis cases.⁴ In India, the prevalence of tinea infections is estimated from 36.6% to 78.4%.⁵ Onychomycosis cases account for nearly 50% of all nail disorders and it impacts around 5.5% of the global population.^{4,6}

According to a study, onychomycosis is most likely diagnostically associated with tinea pedis ($p < 0.001$).^{6,7} In addition, a survey-based study with 2700 patients

* Corresponding author.

E-mail address: sameer.jadhwar@galderma.com (S. Jadhwar).

having toenail onychomycosis concluded that 42.8% of the population had co-existence of tinea infection wherein the incidence of tinea pedis was approximately 33.8%.⁸ According to a study conducted by Pierard G, it was observed that onychomycosis was more common in men and was estimated to increase with age accounting for nearly 25.7% in elderly patients.⁹

Untreated onychomycosis and tinea pedis combined can lead to different co-morbid conditions including cellulitis, wounds, secondary bacterial infections, and pain. In addition, the recurrence of infections is another major factor in 10% to 53% of cases in general.⁶ Lack of awareness regarding the co-existence of infection is another crucial factor to consider while treating or managing these infections.⁶

As far as management is concerned, topical therapy is one of the strategies used for both tinea pedis and onychomycosis due to their superior pharmacokinetic profile.^{1,4} Typically, tinea pedis is managed via the application of topical anti-fungal cream for 4 weeks.¹ Topical antifungals include azoles, allylamines, ciclopirox, tolnaftate, and amorolfine.¹ A cream or ointment preparation is mostly preferred for dry and scaly hyperkeratotic tinea pedis.⁵ Onychomycosis management is somewhat complex due to its underlying pathophysiology, the growth pattern of fungus, and susceptibility factor. For onychomycosis, both oral (e.g., Itraconazole, Ketoconazole) and topical (e.g., Amorolfine 5% nail lacquer and Ciclopirox 8% nail lacquer) strategies are utilized.⁴ Topical antifungals are a highly safer and patient-compliant option with reasonable efficacy.⁴ However, combining topical and oral therapy benefits in achieving the optimum efficacy and safety levels.⁴

Amorolfine, an antifungal and fungistatic topical agent works by inhibiting the synthesis of ergosterol in two different levels i.e., delta 14 reductase and delta 7-8 isomerase thereby inhibiting the synthesis of the cell membrane, reduction of ergosterol, and accumulation of non-typical spherical sterols in the cell membrane.^{10,11} It is indicated against dermatophytes like *Trichophyton* spp, *Microsporum* spp, and *Epidermophyton* spp. The pharmacokinetics of amorolfine promotes penetrability from the nail to the nail bed and its absorption into circulation is quite low. Treatment duration primarily depends on the severity of the infection and growth of the nail plate ranging from 6 to 12 months.¹⁰ Amorolfine is commonly available in two formulations: 0.25% cream base and 5% nail lacquer.¹⁰ Studies have shown the efficacy of 5% amorolfine nail lacquer in patients with toe-nail onychomycosis where the expected mycological cure rate was achieved.¹⁰ Combination therapy, sequential therapy, or extended therapy should be considered according to patient profile and therapeutic response.^{10,12} In the post-treatment phase, a prophylactic regimen comprising a

twice-weekly application of a topical antifungal solution is recommended. Additionally, the prophylactic use of amorolfine lacquer, administered once every two weeks for three years has demonstrated efficacy in minimizing the risk of recurrence.¹²

Through this survey, we tried to gauge the healthcare professionals' (dermatologists and cosmetologists) perspectives on the prevalence and management of coexisting cases of onychomycosis and tinea pedis infections. Additionally, we have also considered their opinion on amorolfine cream and nail lacquer as a topical therapeutic agent for these infections.

2. Materials and Methods

A total of 218 healthcare professionals (dermatologists and cosmetologists) participated in the survey on amorolfine, and their viewpoints regarding the patient experience with the products (5% nail lacquer and 0.25% cream) were evaluated.

2.1. Study tool

A structured questionnaire with 18 questions was used for data collection purposes. The questionnaire has been added in Appendix I for reference.

2.2. Data collection

The survey link was rolled out in 2 phases: June and October (2022) and the healthcare professionals (dermatologists and cosmetologists) responses were recorded.

2.3. Data analysis

The data analysis was carried out using Microsoft Excel Spreadsheets version 2021 and descriptive statistics were calculated using predefined Excel formulas.

3. Results

3.1. Recurrence of co-existing tinea pedis and onychomycosis infection and prior treatments

The survey results revealed that among the 1151 sample respondents, 54.12% of patients were male and 45.88% were females. The healthcare professionals reported that recurrent cases of co-existing tinea pedis and onychomycosis infections were found in 53% of patients. When enquired about any prior treatment taken for the infection, it was found that almost 55.34% of patients did so and the remaining 44% did not.

3.2. Duration of therapy

The healthcare professionals reported that in most patients, the duration of therapy was between 3 to 6 weeks (41.7%)

followed by >6 weeks (26.41%) and 2 to 3 weeks (24.06%).

3.3. Amorolfine cream and nail lacquer

When the healthcare professionals were asked about the reason for prescribing amorolfine cream, the top-most commonly reported reason was that the cream yielded better results than any other amorolfine brands available in the market in most patients (12.42%). Other reasons reported were the reduction of resistance of other antifungals (5.47%), synergistic effects with oral antifungals (6.52%), and its drug class (3.13%). For the majority of the patients (72.45%), all the above reasons compelled them to prescribe amorolfine cream for tinea pedis and onychomycosis co-existing infection (Figure 1).

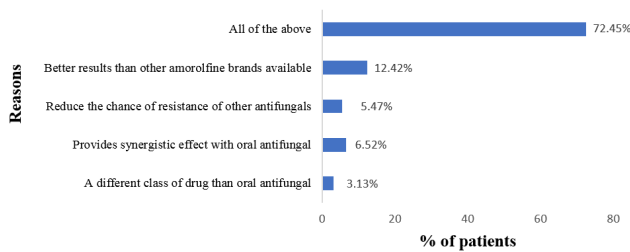


Figure 1: Reasons healthcare professionals prescribe amorolfine cream

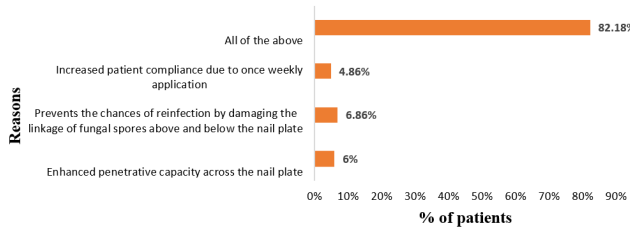


Figure 2: Reasons healthcare professionals choose amorolfine nail lacquer

When healthcare professionals were asked about amorolfine nail lacquer, they reported that the second most common reason driving its prescription for most patients (6.86%) was that it prevents the chances of reinfection by damaging the linkage of fungal spores above and beneath the nail plate. In 4.86% of patients, it was prescribed due to increased compliance owing to its once-weekly application schedule. Another reason it was prescribed to some patients (6%) was its enhanced penetrative capacity across the nail plate. In most of the patients (82.18%) all of the above reasons compelled them to prescribe amorolfine nail lacquer (Figure 2).

3.4. Co-prescription with an oral antifungal and duration for reduction of key symptoms

Around 61.16% of patients were prescribed oral anti-fungal drugs alongside amorolfine cream. The key symptoms of tinea pedis such as itching and erythema reduced within 2-3 days among a few patients and in 1 week in >30% of them. Key symptoms resolved over 2 weeks in most patients (51.95%) (Figure 3).

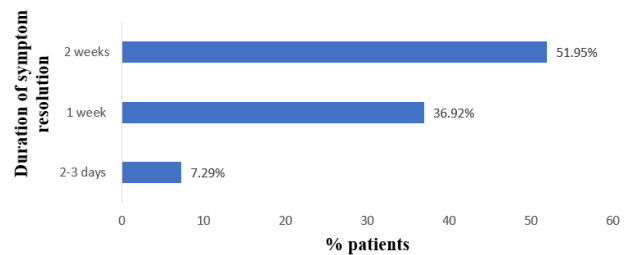


Figure 3: Duration of tinea pedis symptom resolution

3.5. Clearance of lesions and discolorations

In most patients (44.48% and 45.52%) with the co-infection, the clearance of tinea pedis and onychomycosis lesions, and discoloration of the infected area took around 4 weeks (Figures 4 and 5). In 2 weeks the clearance of tinea pedis and onychomycosis lesions were observed in 20.85% and 16.15% of patients respectively. Whereas by the end of 3 weeks, 29.45% of patients showed clearance in tinea pedis. In 36.31% of patients, the clearance of onychomycosis lesions and discoloration took 6-8 weeks. Less than half of the patient population (45.26%) were recommended to stop amorolfine cream after tinea pedis was cured.

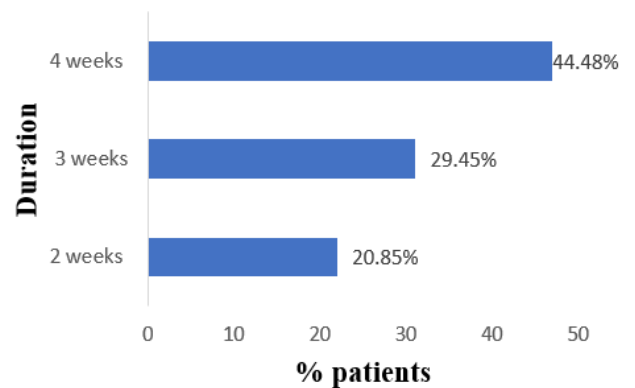


Figure 4: Clearance of tinea pedis lesion

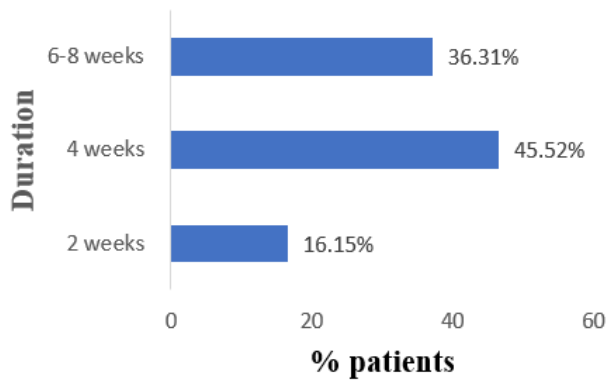


Figure 5: Clearance of onychomycosis lesion and discoloration

3.6. Patient compliance with amorolfine cream and nail lacquer

When healthcare professionals were enquired about patient compliance, they reported that nearly half of the patient population (48.21%) were compliant with the treatment.

3.7. Clinical assessment of amorolfine cream and nail lacquer by healthcare professionals

According to the clinical assessment of healthcare professionals, amorolfine cream and nail lacquer were rated as excellent, based on their effect on most patients (47.61% and 55%, respectively) (Figure 6).

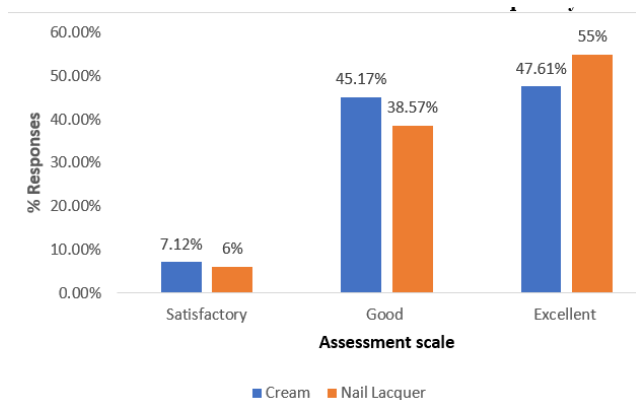


Figure 6: Healthcare professionals clinical assessment of amorolfine cream and nail lacquer

3.8. Assessment of efficacy and satisfaction with amorolfine cream and nail lacquer by patients

Similar results were observed in terms of patients' experience with amorolfine cream and nail lacquer. Most patients rated the effectiveness of amorolfine cream and nail lacquer as excellent (48.74% and 55.86%, respectively) (Figure 7).

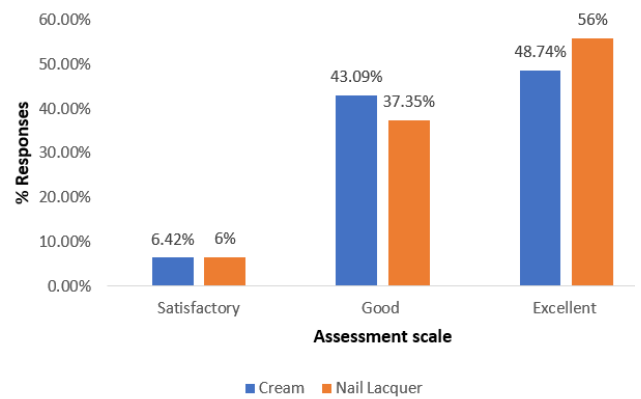


Figure 7: Patients' experience with Amorolfine cream and nail lacquer

3.9. Patients' levels of satisfaction with amorolfine cream and nail lacquer

Most patients (55.86% and 50.73%) rated the level of satisfaction with amorolfine nail lacquer and cream to be excellent (Figure 8).

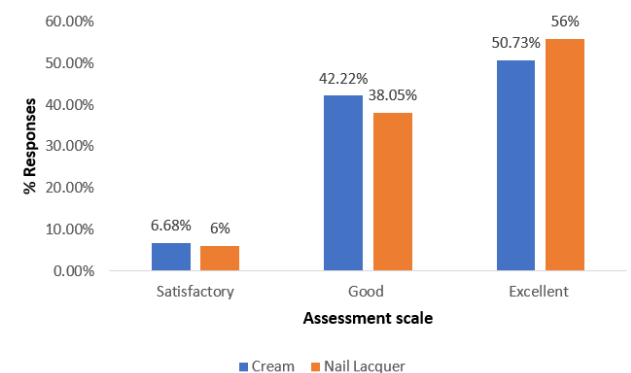


Figure 8: Patient satisfaction with Amorolfine cream and nail lacquer

4. Discussion

Onychomycosis is strongly associated with tinea pedis. However, there are still limited studies for understanding the prevalence and management of co-existing cases of tinea pedis and onychomycosis. The survey-based analysis carried out by Szepietowski *et al.* 2006, enrolled around 2761 patients with toenail onychomycosis. It was found that 42.8% of patients were suffering from concurrent fungal skin infections wherein tinea pedis (33.8%) was the most common.⁸ Another study carried out by Walling *et al.* 2007, showed that among the histologically positive population size of 150 cases, 23 patients (15.33%) were found to have tinea pedis and onychomycosis co-association.⁷ A similar

rate of prevalence was observed in a posthoc analysis of two multicenter, randomized, double-blind studies, in which around 21.3% of patients with onychomycosis were diagnosed with tinea pedis co-infection.¹³

In terms of management, this survey is one of its kind to highlight amorolfine cream and nail lacquer as effective therapeutic options for managing the co-existing tinea pedis and onychomycosis infection. The results obtained in terms of prescription showed that the healthcare professionals obtained better treatment results with amorolfine cream than other brands (12.42%) (Figure 1) which gave us an idea regarding its acceptance by healthcare professionals in India. In addition, even the amorolfine nail lacquer with its increased patient compliance due to once-weekly application and other reasons such as how it prevents the chances of coinfection and enhances penetrative capabilities across the nail plate made it a drug of choice (Figure 2).

Another point was the reduction in the duration of key symptoms of tinea pedis i.e., itching and erythema wherein the reduction was achieved in between 1 to 2 weeks in nearly 90% of cases with the amorolfine cream (Figure 3). Lesion clearance and reduction of discoloration took just around 4 weeks in around 50% of the patients with the amorolfine cream and nail lacquer (Figures 4 and 5). Similar results were seen in a retrospective study carried out by Bunyaratavej *et al.*, that focused on understanding the effect of 5% amorolfine nail lacquer in *N. dimidiatum* onychomycosis-infected patients.¹⁴ The results of the study demonstrated that the 5% amorolfine group resulted in a higher complete cure rate (50%, $p=0.023$) compared to the topical urea group.¹⁴ Also, a 50% clinical improvement was seen in 85.7% of patients ($p=0.003$).¹⁴ In another study, the prophylactic effect of 5% amorolfine nail lacquer on onychomycosis compared to untreated groups was studied for 36 months. It was found that around 66.7% of subjects were free of disease among the population size of 26 subjects.¹⁵ In terms of clinical assessment and levels of satisfaction of patients in the current survey, amorolfine cream, and nail lacquer received excellent remarks from both healthcare professionals and patients (Figures 6, 7 and 8). Similarly, a study comparing the effects of the 5% amorolfine and ciclopirox 8% nail lacquers on onychomycosis reported better patient adherence to the amorolfine treatment regime (85%), with high patient satisfaction (95%).¹⁶

We faced some challenges with the present survey like limited response from specific regions' doctors, a less than 100% response rate, missing patient demographics, and no data on side effects or cost-effectiveness. Addressing these challenges could help improve study reliability and relevance.

5. Conclusion

Toenail onychomycosis is commonly associated with pre-existing tinea pedis infection. There are few clinical studies

and surveys that focus on understanding the above concept. However, there is still a dearth of literature that specifically tackles the prevalence and management of co-existing tinea pedis and onychomycosis infection. Additionally, the lack of awareness regarding its co-existence is another major pain point in managing the infection. This survey-based study was not only able to successfully trace the prevalence of cases but also put forth amorolfine cream and nail lacquer as effective and preferred treatment options for managing these infections. Observations indicate that amorolfine cream and nail lacquer are effective in reducing key symptoms of tinea pedis and onychomycosis, including lesion clearance and discoloration reduction.

6. Source of Funding

This research was funded by Galderma Laboratories.

7. Conflict of Interest

The authors declare no conflicts of interest.

Acknowledgment

We acknowledge the medical writing support provided by Medicca Press Ltd.

References

1. Sahoo AK, Mahajan R. Management of tinea corporis, tinea cruris, and tinea pedis: A comprehensive review. *Indian Dermatol Online J.* 2016;7(2):77–86.
2. Leung AK, Barankin B, Lam JM, Leong KF, Hon KL. Tinea pedis: an updated review. *Drugs Context.* 2023;12:2023–5–1. doi:10.7573/dic.2023-5-1..
3. Leung AKC, Lam JM, Leong KF, Hon KL, Barankin B, Leung AAM, et al. Onychomycosis: An Updated Review. *Recent Pat Inflamm Allergy Drug Discov.* 2020;14(1):32–45.
4. Aggarwal R, Targotra M, Kumar B, Sahoo PK, Chauhan MK. Treatment and management strategies of onychomycosis. *J Mycol Med.* 2020;30(2):100949. doi:10.1016/j.mycmed.2020.100949.
5. Rajagopalan M, Inamdar A, Mittal A, Miskeen AK, Srinivas CR, Sardana K, et al. Expert Consensus on The Management of Dermatophytosis in India (ECTODERM India). *BMC Dermatol.* 2018;18(1):6. doi:10.1186/s12895-018-0073-.
6. Lipner SR, Scher RK. Management of onychomycosis and co-existing tinea pedis. *J Drugs Dermatol.* 2015;14(5):492–4.
7. Walling HW, Sniezek PJ. Distribution of toenail dystrophy predicts histologic diagnosis of onychomycosis. *J Am Acad Dermatol.* 2007;56(6):945–8.
8. Szepietowski JC, Reich A, Garlowska E, Kulig M, Baran E. Factors influencing coexistence of toenail onychomycosis with tinea pedis and other dermatomycoses: a survey of 2761 patients. *Arch Dermatol.* 2006;142(10):1279–84.
9. Piérard G. Onychomycosis and other superficial fungal infections of the foot in the elderly: a pan-European survey. *Dermatology.* 2001;202(3):220–4.
10. Tabara K, Szewczyk AE, Bienias W, Wojciechowska A, Pastuszka M, Oszukowska M, et al. Amorolfine vs. ciclopirox-lacquers for the treatment of onychomycosis. *Postepy Dermatol Alergol.* 2015;32(1):40–5.
11. Hossain CM, Ryan LK, Gera M, Choudhuri S, Lyle N, Ali KA, et al. Antifungals and Drug Resistance. *Encyclopedia.* 2022;2(4):1722–37.


12. Mahajan K, Grover C, Relhan V, Tahiliani S, Singal A, Shenoy MM, et al. Nail Society of India (NSI) Recommendations for Pharmacologic Therapy of Onychomycosis. *Indian Dermatol Online J.* 2023;14(3):330–41. doi:10.4103/idoj.idoj_355_22.
13. Markinson B, Caldwell B. Efinaconazole topical solution, 10%: efficacy in patients with onychomycosis and coexisting tinea pedis. *J Am Podiatr Med Assoc.* 2015;105(5):407–11.
14. Bunyaratavej S, Leeyaphan C, Rujitharanawong C, Surawan TM, Muanprasat C, Matthapan L, et al. Efficacy of 5% amorolfine nail lacquer in Neoscytalidium dimidiatum onychomycosis. *J Dermatolog Treat.* 2016;27(4):359–63.
15. Sigurgeirsson B, Olafsson JH, Steinsson JT, Kerrouche N, Sidou F. Efficacy of amorolfine nail lacquer for the prophylaxis of onychomycosis over 3 years. *J Eur Acad Dermatol Venereol.* 2010;24(8):910–5.
16. Schaller M, Sigurgeirsson B, Sarkany M. Patient-reported outcomes from two randomised studies comparing once-weekly application of amorolfine 5% nail lacquer to other methods of topical treatment in distal and lateral subungual onychomycosis. *Mycoses.* 2017;60(12):800–7.

Author biography

Goutam Bag, Senior Consultant Dermatologist

Syed Mubashir, Senior Consultant Dermatologist

Dyotona Sen, Head of Medical Affairs

Sameer Jadhwar, Medical Affairs Manager  <https://orcid.org/0000-0002-0257-4791>

Cite this article: Bag G, Mubashir S, Sen D, Jadhwar S. Place in therapy of topical amorolfine in the management of onychomycosis and tinea pedis: A survey to understand Indian dermatologists' perspective. *IP Indian J Clin Exp Dermatol* 2024;10(2):149-154.