



Original Research Article

Role of platelet rich plasma therapy in the treatment of alopecia areata and atrophic acne scars

Sumana Manjunath¹, Jiya Vijaykumar Popat², Deval Nitinbhai Vora¹,
Amisha Ravjibhai Gabani^{1*}, Ravindrakumar Vishnubhai Patel¹

¹Dept. of Skin, V. D & Leprosy, Shri M. P. Shah Government Medical College, Jamnagar, Gujarat, India
²Shri M. P. Shah Government Medical College, Jamnagar, Gujarat, India



ARTICLE INFO

Article history:

Received 10-03-2024

Accepted 28-03-2024

Available online 01-06-2024

Keywords:

PRP

Alopecia areata

Acne scars

ABSTRACT

Backgrounds: Alopecia areata and atrophic acne scars are conditions that significantly impact patients' quality of life. Platelet-rich plasma (PRP) therapy has emerged as a promising treatment modality due to its high concentration of growth factors. This study aimed to evaluate the efficacy of PRP in alopecia areata and acne scars.

Materials and Methods: This was a prospective observational study conducted on 50 patients each of alopecia areata and atrophic acne scars treated with intradermal PRP injections at monthly intervals for 6 months. Alopecia areata severity was assessed using a SALT score. Acne scars were graded as per Goodman and Baron's quantitative scar grading system.

Results: In alopecia areata patients, the mean SALT score reduced significantly from 35 ± 6 at baseline to 22 ± 3 at 6 months post-treatment ($p < 0.001$). At the study's conclusion, 66% of patients had complete hair regrowth, while 20% had partial and 14% had no regrowth. Higher grade 3 and 4 scars reduced significantly from 86% to 8% ($p < 0.001$). For acne scars, patients with grade 1 scars increased from 0% to 74% after PRP therapy. Mild adverse effects like pain and erythema were seen.

Conclusion: PRP therapy showed statistically significant improvement in SALT scores in alopecia areata and acne scar grades over 6 months. It was well-tolerated. PRP can be considered an effective, safe, and economic treatment modality for chronic alopecia areata and atrophic acne scars with sustained benefits.

This is an Open Access (OA) journal, and articles are distributed under the terms of the [Creative Commons Attribution-NonCommercial-ShareAlike 4.0 License](https://creativecommons.org/licenses/by-nc-sa/4.0/), which allows others to remix, tweak, and build upon the work non-commercially, as long as appropriate credit is given and the new creations are licensed under the identical terms.

For reprints contact: reprint@ipinnovative.com

1. Introduction

Alopecia areata is a non-scarring, autoimmune, inflammatory disorder characterized by hair loss on the scalp and/or body. It is the most common condition to cause inflammation-induced hair loss. Hair loss can be patchy, confluent or diffuse, with the scalp being the most common site affected.^{1,2} Since most patients are relatively young and the disease burden is commonly substantial, it may lead to psychological stress.³

Acne vulgaris is an inflammatory skin condition involving the pilosebaceous gland that predominantly affects adolescents. Various factors such as environment, genetics, and hormonal changes can play a role in its pathogenesis.^{4,5} This leads to significant morbidity with residual scarring and psychological disturbances. Acne scars can be classified as atrophic or hypertrophic, with atrophic scars further categorized into ice pick, rolling and boxcar types based on their morphology.⁶

Platelet-rich plasma (PRP) therapy has emerged as a promising treatment modality due to its high concentration of growth factors like platelet-derived

* Corresponding author.

E-mail address: amishagabani123@gmail.com (A. R. Gabani).

growth factor (PDGF), transforming growth factor (TGF-beta), vascular endothelial growth factor (VEGF), epidermal growth factor (EGF), and others.^{7,8} These growth factors promote angiogenesis, epithelialization, cell proliferation, chemotaxis, and synthesis of collagen and matrix components, thereby aiding wound healing and repair.⁷⁻⁹ PRP is also known as an autologous source of bioactive proteins that enhance tissue regeneration.¹⁰

As PRP is derived from the patient's blood, there is a decreased probability of adverse reactions and transfusion-transmitted infections, making it a safe therapeutic option.⁷ PRP has been utilized in treating various dermatological conditions like vitiligo, androgenic alopecia, skin ulcers, post-traumatic scars, acne scars, alopecia areata, melasma, striae distensae, and lichen sclerosis.⁷

With this context, the present study aimed to evaluate the effect of PRP on alopecia areata and acne scars.

2. Materials and Methods

2.1. Study design

This prospective observational study was carried out in the Department of Skin V. D. & Leprosy at tertiary care hospital, in Gujarat over 2 years.

2.2. Sample size

The study spanned one year, initially enrolling approximately 68 patients with alopecia areata and 60 patients with acne scars. However, 8 patients with alopecia areata and 10 patients with acne scars were lost to follow-up due to migration or a change of mind. Consequently, 50 patients with each condition were further monitored. All participants were duly informed about the nature, course, and prognosis of their respective conditions. They were also briefed on the importance of treatment consistency. Informed consent was obtained from all patients, and approval for conducting the study was granted by the institutional ethical committee.

2.3. Sampling technique

Consecutive sampling.

2.4. Inclusion criteria

1. Patients who were willing to give verbal and informed consent.
2. Patients of age between 20 to 35 years and of both sexes.
3. Patients coming for regular follow-up.

2.5. Exclusion criteria

1. Patients with unrealistic expectations.
2. Pregnant and lactating women.

3. Patients are not willing to give consent.
4. Patient on long-term immunosuppressive treatment.
5. Patient with a history of bleeding disorders and on anti-coagulants.
6. Patient having an active infection at the site of the procedure.

2.6. Data collection tool

Various grading systems have been used to assess the severity of alopecia namely the SALT score, ALODEX score, and alopecia areata grading scale.^{11,12}

For data collection, the study utilized validated and objective grading scales. The Severity of Alopecia Tool (SALT) score was employed to quantify the extent and density of scalp hair loss in alopecia areata patients. The entire scalp was divided into four quadrants (top, posterior, right side, left side) based on surface area. The percentage of hair loss in each area was visually assessed and multiplied by the respective area percentage. The products were then summed to obtain the final SALT score from 0-100, with higher scores indicating more extensive hair loss.^{13,14}

For acne scars, the Goodman and Baron quantitative scar grading system was used, which scores scars based on lesion counting and morphological severity. Lesion counting assigns points from 1-3 based on the number of lesions (<10, 11-20, >20). Severity grading gives points from 1-4 for the degree of atrophy (mild, moderate, severe) or hypertrophy. The lesion count and severity scores are multiplied and then summed for a total score ranging from 0-84, which determines the final scar grade from 1 (mildest) to 4 (most severe).¹⁵

2.7. Procedure

Regarding procedures, PRP was prepared using double spin-method. 10 cc of whole blood was withdrawn in a 10ml syringe under aseptic precautions. Then it was divided into 2 sodium citrate vacutainer (it has an anticoagulant which prevent platelet activation) each containing 5 ml of blood. The citrated blood was centrifuged at 1500 rpm for 5 minutes known as soft spin. At the end of centrifugation, the whole blood was divided into 3 parts: the bottom layer contained most of red blood cells, a upper layer which contained few platelets and white blood cells and the third part in between them is known as buffy coat which is rich in platelets and white blood cells. Using a micropipette, the upper layer and superficial buffy coat were carefully moved into two sterile test tubes. Following this, they were subjected to another centrifugation at 3000 rpm for an additional 5 minutes, commonly known as a hard spin. Once the hard spin was completed, the resulting platelet concentrate consisted predominantly of platelet-poor plasma in the upper two-thirds and platelet-rich plasma in the lower one-third. This lower portion of platelet-rich

plasma was then delicately drawn into two insulin syringes, with each syringe containing a solution of 0.2 ml/ml calcium chloride.^{8,15,16}

For alopecia areata, PRP was injected intradermally into the areas of hair loss in subfollicular plane after topical anaesthetic application. It was injected in a grid-like pattern where 0.1 ml of PRP was given 1 sq cm apart at monthly intervals for 6 months.

To address acne scars, the targeted area underwent gentle cleansing followed by application of a thick layer of topical anaesthetic cream (2.5% lignocaine and 2.5% prilocaine), which was left under occlusion for 30 to 45 minutes to ensure adequate anaesthesia. PRP was injected into and around the scars through multiple punctures at 4-week intervals over 6 months. Standardized clinical photographs were taken at baseline and each follow-up visit by trained personnel to objectively document results over time. Patients were advised not to vigorously rub face for 12 hours. All patients were closely monitored for adverse effects throughout the treatment course.^{16,17}

2.8. Data analysis

Here is a detailed description of the data analysis and statistical analysis methods used in the study:

All data was systematically recorded and analyzed using SPSS statistical software (version 26.1). Both descriptive and inferential statistical analysis were performed.

2.8.1. For alopecia areata patients

1. Baseline demographic data like age and gender were analyzed using descriptive statistics (mean, frequencies, percentages, etc.)
2. The SALT scores, quantifying scalp hair loss extent and density were calculated at baseline and each follow-up visit by:
 - (a) Visually assessing the percentage of hair loss in each scalp quadrant
 - (b) Multiplying the percentage by the area fraction for that quadrant
 - (c) Summing the products across all four quadrants
3. The mean SALT scores pre- and post-treatment were compared using paired t-tests to evaluate the statistical significance of the change. A p-value < 0.05 was considered statistically significant.
4. The percentage of patients achieving complete hair regrowth, partial regrowth and no regrowth after 6 months were calculated and reported as proportions.

2.9. For acne scar patients

1. Baseline demographics were analyzed using descriptive statistics.
2. The Goodman and Baron quantitative scar grading involved:
 - (a) Counting acne scar lesions and grading 1-3 points based on number
 - (b) Grading scar severity from 1 (mildest) to 4 (most severe).
 - (c) Multiplying the lesion count and severity scores
 - (d) Summing the product to get a total score (range 0-84).
 - (e) Allocating a final scar grade of 1-4 based on the total score.
3. The distribution of patients across the four scar grades (1-4) was determined at baseline and post-treatment.
4. Changes in the distribution pre- and post-treatment were analyzed using chi-square tests, with p<0.05 indicating statistical significance.
5. Percentages of patients experiencing each type of adverse effect (pain, erythema, hyperpigmentation, etc.) were calculated.

Standardized clinical photographs at baseline and follow-ups were independently assessed by blinded evaluators to minimize observer bias and variability.

Both quantitative data (e.g. SALT scores) and categorical data (e.g. scar grades) were analyzed appropriately. Quantitative variables were reported as mean ± standard deviation, while frequencies and percentages were used for categorical variables.

The results were presented using descriptive text, tables, and graphs. Statistical tests like paired t-tests and chi-square were employed to compare pre-and post-treatment outcomes and determine the significance of the observed changes.

Overall, a combination of descriptive and inferential statistics following standard methods was utilized to analyze the data in an objective and statistically robust manner using SPSS software.

3. Results

Table 1: Goodman and baron’s qualitative assessment of post treatment reduction of acne scars

Grade	No. of patients Before treatment (at beginning) N=50	No. of patients After treatment (at 6 months) N=50	p value
1	0	37(74%)	<0.001
2	7(14%)	9(18%)	<0.001
3	26(52%)	4(8%)	<0.001
4	17(34%)	0	<0.001

Table 1 shows the Goodman and Baron’s qualitative assessment of acne scar grades before and after PRP treatment. At baseline, no patients (0%) had grade 1 (macular) scars. After 6 months of PRP treatment, the percentage of patients with grade 1 scars increased

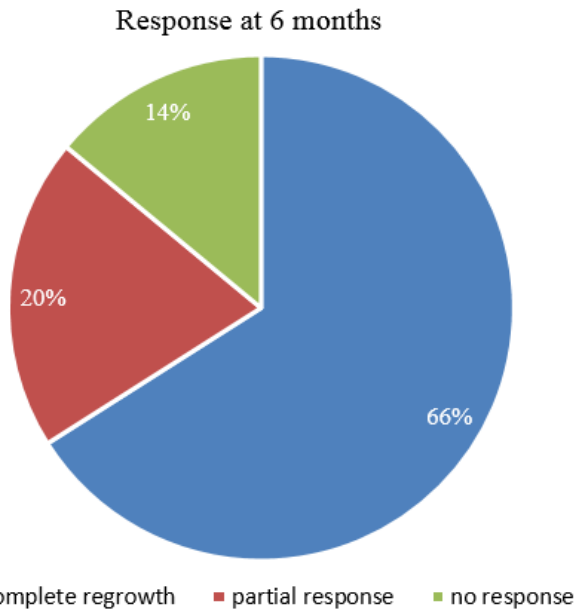


Figure 1: Response after 6 months of PRP therapy in alopecia areata

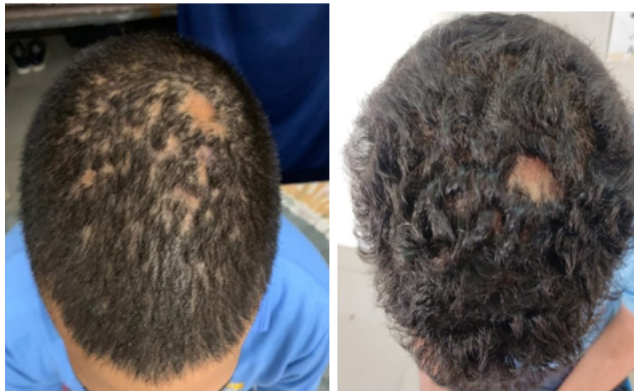

Figure 2: Pre-treatment post-treatment, Before and after 6 sessiond of PRP

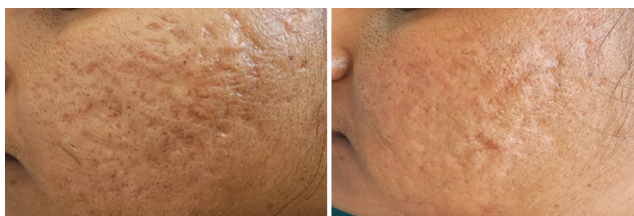

Figure 3: Pre-treatment, Post-treatment, Before and after 6 sessions of PRP

Table 2: Adverse effects following PRP therapy

Adverse effects of PRP therapy	Acne Scars (% of patients)	Alopecia areata (% of patients)
Transient Pain/ Mild discomfort	64	58
Erythema	86	74
Post-inflammatory hyperpigmentation	4	0
Burning sensation	14	28

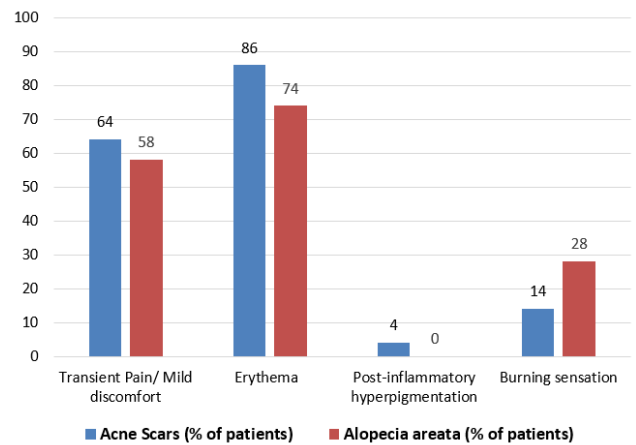


Figure 4: Adverse effects following PRP therapy

significantly to 74% ($p < 0.001$). For grade 2 (mild) scars, 14% of patients had this grade at baseline which increased slightly to 18% post-treatment ($p < 0.001$). The percentage of patients with grade 3 (moderate) scars reduced significantly from 52% pre-treatment to only 8% post-treatment ($p < 0.001$). Grade 4 (severe) scars were present in 34% of patients initially but no patients had this severity grade after completing PRP therapy ($p < 0.001$).

Figure 1 represents the response of alopecia areata patients to PRP therapy at 6 months in the form of a pie chart. 66% of patients achieved complete regrowth of pigmented hair, while 20% had partial regrowth and 14% did not experience any regrowth.

The clinical photographs in Figures 2 and 3 illustrate the effects of PRP therapy on representative cases of alopecia areata and acne scars respectively before and after 6 treatment sessions. Marked improvement in hair regrowth and scar appearance can be appreciated.

Table 2 summarizes the adverse effects experienced by patients after PRP injections for acne scars and alopecia areata. Transient pain or mild discomfort occurred in 64% of acne scar patients and 58% of alopecia areata patients. Erythema was the most common side effect, seen in 86% of acne scar patients and 74% of alopecia areata patients. Post-inflammatory hyperpigmentation developed in 4% of acne scar patients but no alopecia areata patients. Burning

sensation was reported by 14% of acne scar patients and 28% of alopecia areata patients. Figure 4 depicts these adverse event percentages graphically.

Overall, the data in the tables and figures demonstrates the significant clinical improvement in both alopecia areata and acne scar grades with PRP therapy, supported by p-values <0.001. Subjective and objective assessment tools were utilized. Adverse effects were minor and self-limiting.

4. Discussion

The results of this study demonstrate the significant therapeutic benefits of platelet-rich plasma (PRP) therapy for both alopecia areata and atrophic acne scars over a treatment period of 6 months.

In the alopecia areata patients, the mean SALT score, which quantifies the extent and density of scalp hair loss, reduced markedly from 35 ± 6 at baseline to 22 ± 3 post-treatment ($p < 0.001$). This translates to a clinically appreciable improvement in hair regrowth. At study conclusion, 66% of patients achieved complete regrowth of pigmented terminal hair, while 20% experienced partial regrowth and only 14% did not respond to PRP therapy. These findings are consistent with previous studies that reported substantial reductions in SALT scores and high rates of hair regrowth with PRP injections for alopecia areata.^{18,19}

The acne scar results were equally promising. Baseline grading revealed that a majority of patients (86%) had severe grade 3 or grade 4 atrophic scars as per the Goodman and Baron quantitative scoring system. However, after 6 monthly sessions of intralesional PRP injections, there was a significant decline in these higher scar grades. The percentage of patients with grade 1 (macular) scars, which are the mildest, increased remarkably from 0% to 74% ($p < 0.001$). Only 8% of patients had residual grade 3 scars post-treatment, compared to 52% pre-treatment. None of the patients had grade 4 (severe) scars remaining. These findings align with other studies that documented a favourable shift towards milder scar grades following PRP treatment for acne scars.^{20,21}

The therapeutic effects of PRP can be attributed to the abundant growth factors it contains, including PDGF, TGF- β , VEGF and others. These proteins stimulate angiogenesis, collagen production, matrix remodelling and wound healing processes that facilitate hair regrowth and scar remodelling.^{22,23} Being an autologous product, PRP also has an excellent safety profile, as reflected by the minor adverse events observed in this study like transient pain, erythema and rare hyperpigmentation.

A key strength of this research was the use of objective, validated grading scales (SALT score and Goodman's system) and standardized clinical photographs to assess treatment outcomes, minimizing bias. The statistically significant improvements demonstrated with p-values <0.001 further substantiate the results. However, the

lack of a placebo or control arm is a limitation.

In summary, this prospective study adds to the growing body of evidence supporting PRP as an effective and well-tolerated treatment option for chronic alopecia areata and atrophic acne scarring. The ease of preparation, minimal risk profile, and sustained therapeutic effects make PRP an attractive modality, especially in the younger population frequently affected by these conditions.

5. Conclusion

The present study adds to the growing body of evidence supporting PRP as an effective, well-tolerated, and cost-effective treatment modality for alopecia areata and distressing atrophic acne scarring. The ease of preparation, minimal risk profile, and sustained therapeutic effects make PRP an attractive option, especially for the younger population frequently affected by these conditions. While larger controlled trials are warranted to corroborate these findings, the present study highlights the promising role of PRP in managing these challenging dermatological disorders.

6. Ethical Approval

Approved.

7. Conflict of Interest

None.

8. Source of Funding

Multi-Disciplinary Research Unit, Shri M. P. Shah Government Medical College, Jamnagar.

9. Acknowledgement

We would like to extend our special thanks to Dean madam, Dr. Nandini Desai, and Dean Shri M. P. Shah Government Medical College for providing opportunity to research and opening new horizon in the field of research. We are heartily thankful to MDRU team and specially Dr. Naresh Makwana, Nodal Officer of Multi-Disciplinary Research Unit for providing necessary help and financial support to our study at every step.

References

1. Meznerics F, Illés K, Dembrovszky F, Fehérvári P, Kemény L, Kovacs K, et al. Platelet-rich plasma in alopecia areata—a steroid-free treatment modality: a systematic review and meta-analysis of randomized clinical trials. *Biomedicines*. 2022;10(8):1829. doi:10.3390/biomedicines10081829.
2. Seetharam K. Alopecia areata: an update. *Indian J Dermatol Venereol Leprol*. 2013;79(5):563–75.
3. Katakam B, Behera B, Ranugha P, Puri N, Rao T, Gulati R, et al. Iadvl sig pediatric dermatology (academy) recommendations on childhood alopecia areata. *Indian Dermatol Online J*. 2022;13(6):710–20.

4. Teng H, Chen H. Platelet-rich plasma in the treatment of alopecia areata after covid-19 vaccination. *Clin Case Rep.* 2023;11(5):e7342. doi:10.1002/ccr3.7342.
5. Simakou T, Butcher J, Reid S, Henriquez F. Alopecia areata: A multifactorial autoimmune condition. *J Autoimmun.* 2019;98:74–85. doi:10.1016/j.jaut.2018.12.001.
6. Mintoff D. Clinical Dermatology and COVID-19 Pandemic: Narrative Review. *Indian J Dermatol.* 2021;66(3):246–255.
7. Garg S. Regeneration Through Platelet Rich Plasma - A Cell Therapy with a Path Full of Milestones, Controversies and Cautions! *Indian Dermatol Online J.* 2024;12(1):S1–3. doi:10.4103/idoj.idoj_589_21.
8. Garg S, Bansal A. Platelet-rich plasma in interventional dermatology and trichology: How far have we come? *Cosmoderma.* 2021;1(12):1–22.
9. Tao J, Champlain A, Weddington C, Moy L, Tung R. Treatment of burn scars in Fitzpatrick phototype III patients with a combination of pulsed dye laser and non-ablative fractional resurfacing 1550 nm erbium:glass/1927 nm thulium laser devices. *Scars Burn Heal.* 2018;4:2059513118758510. doi:10.1177/2059513118758510.
10. Pavlović V, Čirić M, Jovanović V, Stojanović P. Platelet rich plasma: a short overview of certain bioactive components. *Open Med (Wars).* 2016;11(1):242–7.
11. Abdel-Meguid AM, Hafez HA, Sayed SK, and RRH. Efficacy of autologous platelet-rich plasma combined with microdermabrasion compared with platelet-rich plasma alone on postacne scars. *J Curr Med Res Pract.* 2020;5:284–9.
12. Shafik E, Nassar A. Treatment of Atrophic Acne Scars with Platelet Rich Plasma Gel and Micro-needling. *Egypt J Hosp Med.* 2021;85(2):4323–7.
13. Ereen DTR, Sadiq DBA, Choudhury DKN, Mohiuddin DA, Lewis DP, Anwar DR, et al. Platelet Rich Plasma in the treatment of Androgenic Alopecia: A Follow-up study. *Adv Res J Med Clin Sci.* 2020;6(2):86–91.
14. Alser OH, Goutos I. The evidence behind the use of platelet-rich plasma (PRP) in scar management: a literature review. *Scars Burn Heal.* 2018;4:2059513118808773. doi:10.1177/2059513118808773.
15. Porwal S, Chahar YS, Singh PK. A Comparative Study of Combined Dermaroller and Platelet-Rich Plasma Versus Dermaroller Alone in Acne Scars and Assessment of Quality of Life Before and After Treatment. *Indian J Dermatol.* 2018;63(5):403–8.
16. Kumar A, Sharma RP, Bali S, Arya P. Role of platelet rich plasma therapy in alopecia areata a prospective study. *Int J Contemp Med Res.* 2016;3(8):2499–502.
17. Wahab AJ, Anandan V, Kumar MMS, Shukla S. Efficacy and safety of platelet rich plasma (PRP) as monotherapy in the management of acne scars in a tertiary care centre. *Indian J Clin Exp Dermatol.* 2017;3(3):119–23.
18. Alser OH, Goutos I. The evidence behind the use of platelet-rich plasma (PRP) in scar management: a literature review. *Scars Burn Heal.* 2018;4:2059513118808773. doi:10.1177/2059513118808773.
19. Sharma A, Chouhan K, Bhatia S, Dashore S. Platelet-rich plasma in androgenetic alopecia. *Indian Dermatol Online J.* 2021;12(1):31–40.
20. Cruciani M, Masiello F, Pati I, Marano G, Pupella S, Angelis VD, et al. Platelet-rich plasma for the treatment of alopecia: a systematic review and meta-analysis. *Blood Transfus.* 2022;21(1):24–36.
21. Gupta AK, Bamimore MA. The effect of placebo in split-scalp and whole-head platelet-rich plasma trials for androgenetic alopecia differs: Findings from a systematic review with quantitative evidence syntheses. *J Cosmet Dermatol.* 2022;21(4):1454–63.
22. Nofal E, Helmy A, Nofal A, Alakad R, Nasr M. Platelet-rich plasma versus CROSS technique with 100% trichloroacetic acid versus combined skin needling and platelet rich plasma in the treatment of atrophic acne scars: a comparative study. *Dermatol Surg.* 2014;40(8):864–73.
23. Porwal S, Chahar YS, Singh PK. A Comparative Study of Combined Dermaroller and Platelet-Rich Plasma Versus Dermaroller Alone in Acne Scars and Assessment of Quality of Life Before and After Treatment. *Indian J Dermatol.* 2018;63(5):403–8.

Author biography

Sumana Manjunath, 3rd Year Resident

Jiya Vijaykumar Papat, 2nd-Year Student

Deval Nitinbhai Vora, Professor and HOD

Amisha Ravjibhai Gabani, 2nd Year Resident

Ravindrakumar Vishnubhai Patel, 3rd Year Resident

Cite this article: Manjunath S, Papat JV, Vora DN, Gabani AR, Patel RV. Role of platelet rich plasma therapy in the treatment of alopecia areata and atrophic acne scars. *IP Indian J Clin Exp Dermatol* 2024;10(2):165-170.