

Content available at: <https://www.ipinnovative.com/open-access-journals>

IP Indian Journal of Clinical and Experimental Dermatology

Journal homepage: www.ijced.org/

Original Research Article

Comprehensive wound healing approach for exposed achilles tendon without paratenon by utilizing matriderm with vacuum-assisted closure (VAC) and second-stage skin grafting

Sudhir Singh^{1*}¹Dept. of Plastic Surgery, Getwell Hospital, Varanasi, Uttar Pradesh, India

ARTICLE INFO

Article history:

Received 01-06-2024

Accepted 10-07-2024

Available online 04-09-2024

Keywords:

Achilles tendon

MatriDerm

Vacuum-Assisted Closure (VAC) therapy

Second-stage skin grafting

Exposed tendons

Wound healing

Longitudinal splitting of tendo achilles

Dermal substitute

ABSTRACT

Introduction: Achilles tendon lesions often necessitate flap surgery for wound closure, particularly when the paratenon is absent, as skin grafts fail without a vascular bed. While fasciocutaneous flaps offer functional benefits, they are complex and aesthetically unappealing. This study explores a simpler method combining Matriderm, Vacuum-Assisted Closure (VAC) therapy, and skin grafting to enhance healing, reduce scarring, and improve outcomes for exposed Achilles tendons.

Aim: The study aims to optimize wound healing, minimize complications, and facilitate functional recovery of exposed Achilles tendons through a multi-step intervention involving Matriderm, VAC therapy, and skin grafting.

Materials and Methods: An 87-year-old female with a gangrenous, infected wound over her left lower limb, including an exposed Achilles tendon, underwent debridement and antibiotic treatment. Due to her frail condition, a simpler method was chosen over traditional flap surgery.

Intervention Steps: 1. Longitudinal Splitting: The Achilles tendon was split longitudinally to promote granulation tissue formation; 2. Matriderm Application: Matriderm, a bovine collagen matrix, provided a scaffold for cell ingrowth and neovascularization; 3. VAC Therapy: Subatmospheric pressure (-125 mmHg) was applied to remove excess fluid, reduce edema, and enhance blood flow, aiding granulation tissue formation; 4. Monitoring: Continuous monitoring ensured optimal granulation tissue development for successful skin grafting; 5. Second-Stage Skin Grafting: A thin skin graft was applied to the vascularized bed and stabilized with skin staplers; 6. Wound Closure and Rehabilitation: Post-grafting, the wound was dressed and monitored until complete healing, with follow-up evaluations.

Results: Preliminary results indicated successful wound closure, minimal complications, and optimized healing. At a one-year follow-up, the skin was pliable, elastic, free from scarring or contracture, and aesthetically appealing.

Conclusion: We present a comprehensive very simple approach for wound cover healing of exposed bare Achilles tendon lacking paratenon by using MatriDerm with Vacuum-Assisted Closure (VAC) followed by a second-stage skin grafting procedure. The process involves sequential steps focusing on optimal wound healing, reduction of complications, and restoration of Achilles tendon functionality without the need of microsurgical skill or simple flap surgery with its own donor nonaesthetic morbidity.

This is an Open Access (OA) journal, and articles are distributed under the terms of the [Creative Commons Attribution-NonCommercial-ShareAlike 4.0 License](https://creativecommons.org/licenses/by-nc-sa/4.0/), which allows others to remix, tweak, and build upon the work non-commercially, as long as appropriate credit is given and the new creations are licensed under the identical terms.

For reprints contact: reprint@ipinnovative.com

1. Introduction

It is well known that lesions with exposed tendons, the use of flaps for wound closure is generally considered the best

* Corresponding author.

E-mail address: s.sulekha@gmail.com (S. Singh).

option. Fascio cutaneous flaps are the first choice for the repair of lesion with exposed tendon, since they provided the best functional repair with superior gliding properties for the underlying tendons. The Achilles tendon is a large tendon and it requires skin flap either microsurgical free flap or pedicled flap to cover specially when there is loss of paratenon, as skin graft will not be successful as there is no vascular bed. However the flap is not aesthetically appealing and requires greater skill specially regarding free flap involving microsurgery. However to address this above problem, the use of dermal substitute along with VAC to create good vascular bed followed by later skin graft was our simple novel idea. Such a big tendon needs to be split longitudinally randomly in small strips so that more surface area for promoting sprouting granulation tissue is created from base along with additional help of VAC application. This paper introduces a novel approach utilizing MatriDerm with VAC therapy followed by a second-stage skin grafting procedure to promote a robust and structured healing process giving less scarred more elastic pliable non adherent skin which can be moved over the tendon freely without developing contracture at one year follow up.

2. Aim

The primary objective is to optimize wound healing, minimize complications, and facilitate the wound cover healing with functional recovery of the bare exposed Achilles tendon through a multi-step intervention incorporating MatriDerm, VAC therapy, and skin grafting.

2.1. Case

87 years old very frail female patient suffered gangrenous infected foul smelling skin loss wound over left lower limb at near ankle region for the last one week. Thorough debridement with proper antibiotics given to save from amputation. After two weeks of post op dressing the exposed tendo achilles with surrounding extensive wound needed cover by flap but patient condition was moribund and so opted for simpler procedure trial. We planned for covering wound by dermal substitute MatriDerm followed by thin skin graft. For that we needed to develop vascular bed by VAC and longitudinally randomly splitting the tendon.

3. Materials and Methods

3.1. Longitudinal splitting of tendo achilles

The Achilles tendon is intentionally longitudinally split at multiple sites randomly to create a conducive environment for granulation tissue formation and efficient wound healing (Figure 1).

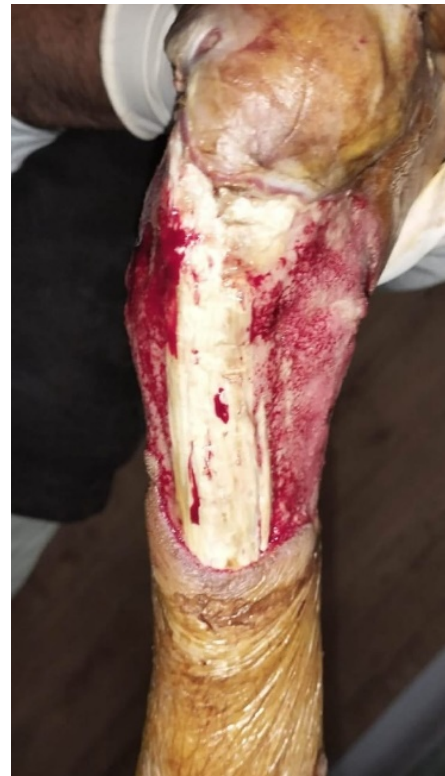

Figure 1: Exposed tendoachilles tendon with longitudinal slices given.

3.2. Matriderm application

Matriderm, a dermal bovine collagen matrix, is applied to the split Achilles tendon to provide a scaffold for cell ingrowth and neovascularization, fostering an environment conducive to tissue regeneration (Figure 2).

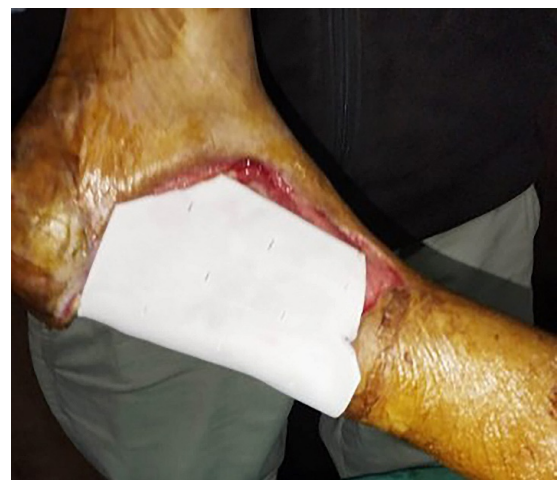

Figure 2: MatriDerm applied

3.3. Vacuum-assisted closure (VAC therapy)

Sub atmospheric negative pressure (at minus 125 mm of mercury) wound therapy (VAC) is employed to remove excess fluid, reduce oedema, and enhance blood flow, thereby promoting quicker formation of granulation tissue helping optimal wound healing (Figure 3).

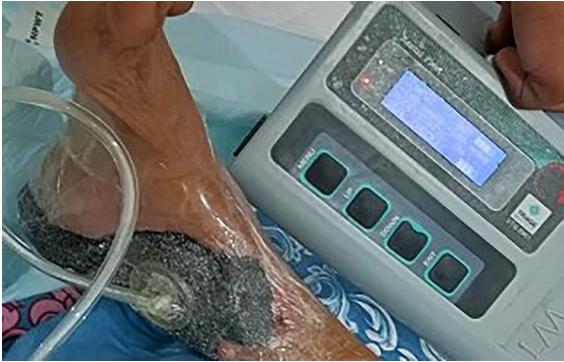

Figure 3: VAC applied

3.4. Monitoring and granulation tissue formation

Continuous monitoring ensures the formation of an ideal granulation tissue bed crucial for successful skin grafting in the final second stage (Figure 4).

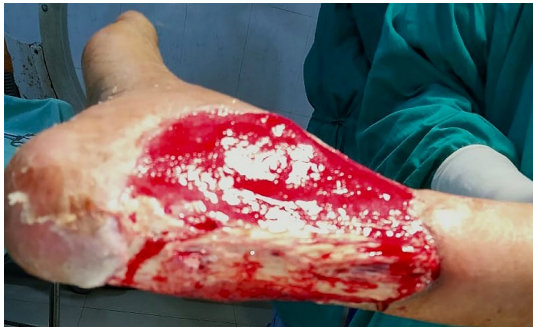

Figure 4: Post VAC and MatriDerm application.

3.5. Second-stage skin grafting

Upon achieving an adequate granulation tissue bed, a second-stage skin grafting procedure is performed, involving the transfer of thin skin graft from a donor site to the wound area. Skin stabilized over vascular bed by skin staplers (Figure 5).

3.6. Wound closure and rehabilitation

Following skin grafting, the wound is dressed with sofratulle and over it saline soaked moist cotton gauze pieces followed by bandaging. The patient undergoes first dressing after 7

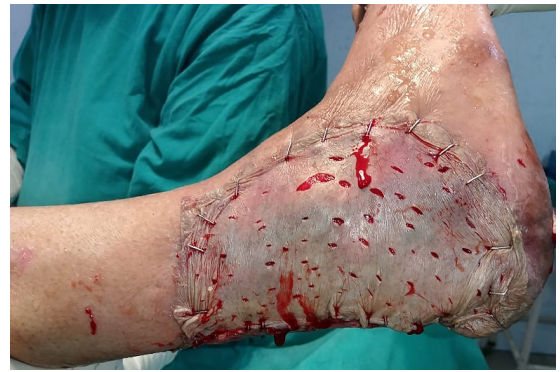

Figure 5: SSG

days and subsequently every 5 days and wound healed by three weeks' time.

4. Results

Preliminary results demonstrate successful wound closure, minimal complications, and an optimized healing trajectory. Follow up after one year was excellent. There is no scarring or contracture development. The skin is pliable and elastic and free of underlying tendon surface and easily mobile with wrinkles of elastic skin can be observed. The skin can be freely pinched with forceps and sensation subjectively is almost normal to the surrounding skin sensation. It is aesthetically more appealing (Figures 6 and 7 a & b).

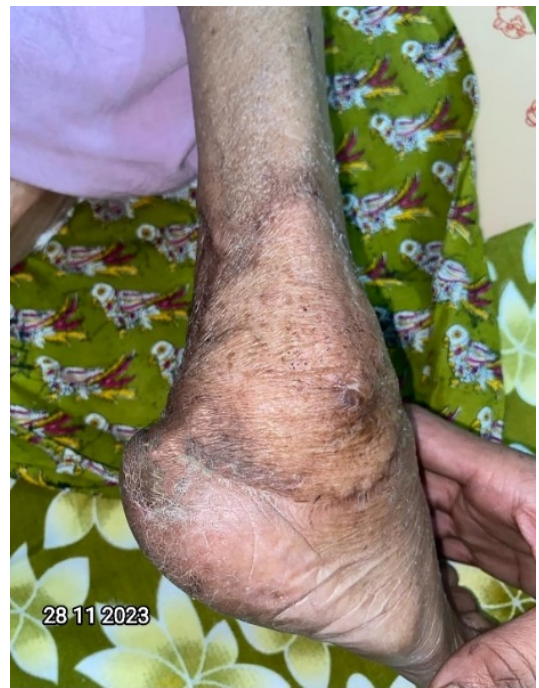

Figure 6: Follow-up 10 months

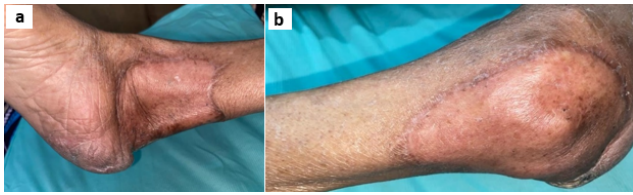


Figure 7: a: One year follow-up; b: One year follow-up

5. Discussion

Fixing wounds on exposed tendons is hard. Normally, surgeons use flap surgeries like local flaps, cross-leg flaps, and free flaps. But for extensive wounds with an exposed Achilles tendon, local flaps might not be feasible.^{1–7} Cross-leg flaps work if the other leg is fine, but patients can't move their legs for weeks. Free flaps are reliable but need intact vessels and microsurgical skill.

In our case, there was no tissue around for a local flap, and the patient condition was moribund. Making patients rest for a long time if we try cross leg flap, can lead to disuse syndrome, especially in older patients. So, we chose Negative Pressure Wound Therapy (NPWT) to close the wound early without making the patient rest for a long time.

Since large Achilles tendon exposure, vascularization with VAC will not be fast.⁸ This slow healing was likely because the outer layer of the Achilles tendon, called the paratenon, was completely lost. Tendons need the paratenon for nutrition, and blood flow to it comes from the surrounding tissue. We needed to promote the formation of granulation tissue by getting blood only from the bottom and sides of the tendon. Just using VAC wasn't enough, so we made cuts in the tendon to let blood flow from the bottom to the top.⁹ This method is like making holes in a bone to cover the exposed surface.^{10,11} By doing this and using VAC and application of dermal substitute MatriDerm of 3 mm thickness together, we could form tissue on the surface of the Achilles tendon and protect the tendon itself.

Conventional wound healing, driven by the natural body mechanism involving fibroblast collagen deposition with the assistance of immune cells, results in slow healing and minimized scarring. Negative wound pressure therapy, such as Vacuum-Assisted Closure (VAC), accelerates wound healing by promoting faster fibroblast repopulation and collagen deposition. However, VAC may lead to improper extracellular matrix (ECM) formation and scarring. Combining VAC with a dermal substitute scaffold enhances neodermis formation, accelerates collagen deposition, stimulates neovascularization, and results in proper ECM and dermis formation without scarring. This approach yields a better functional and aesthetically pleasing outcome, making the wound ready for skin grafting.

This manoeuvre deliberates on the significance of the combined approach, addressing the role of each intervention and its synergistic effects on promoting effective wound

healing and functional recovery. The concept of using NPWT to encourage granulation tissue to form over bare exposed tendon has been reported in several case series and studies. Greer et al first reported this concept in 1999,¹² and subsequent case series have supported its effectiveness.^{13,14} More recently, studies have explored the use of dermal substitutes combined with NPWT for covering complex defects with exposed deep structures, and successful outcomes have been reported.^{15–29} These studies have demonstrated that NPWT, when combined with dermal substitutes, can effectively promote granulation tissue formation and aid in the healing of wounds with exposed tendon and bone. It has been found that 4cm breadth irrespective of length exposed bone without periosteum can be successfully covered with dermal matrix promoting neodermis formation through vascularization from the adjoining raw wound area.³⁰ So we thought if exposed tendon area is more than 4cm breadth irrespective of length then by splitting tendon longitudinally we can try skin substitute for favourable result.

Ohata and colleagues recognized the imperative of establishing vascular supply to extensive, denuded tendon regions.⁸ Detailing a specific case involving a substantial expanse of exposed Achilles tendon, the authors undertook a strategic intervention. Employing two longitudinal splits on the ventral surface of the tendon, they introduced Negative Pressure Wound Therapy (NPWT) foam through these incisions. The objective was to stimulate the emergence of granulation tissue from the deeper layers.

In our approach, we employed sharp longitudinal slicing randomly to uncover discrete punctate areas of bleeding on the tendon surface and beneath, facilitating optimal adherence of the negative pressure dressing. By preventing desiccation, a critical factor in tissue healing, we observed the formation of islands of granulation tissue. Over time, these islands coalesced, engendering a continuum of granulation tissue coverage across the entire tendon surface. This technique not only addressed the challenge of large bare tendon areas but also facilitated an environment conducive to the proliferation of granulation tissue, promoting a favorable wound healing trajectory.

Some studies talk about using a special dressing called NPWT along with artificial skin substitutes to treat wounds that expose tendons or bones. The most commonly used artificial skin substitute is Integra®, and it usually takes 2–4 weeks to fully mature after application. Some studies suggest that using V.A.C. dressings on top of these substitutes can speed up the maturation process, with an average of 7.3 days reported in some cases.^{15,18–20,22–24} However, using Integra® has its challenges, with a failure rate of around 25%, the need for sterile dressing changes, and an additional surgery to replace the top layer with skin grafts. Therefore, to give good pliability thickness skin for gliding effect on tendon, we have used 3mm MatriDerm the

pure dermal substitute without any impervious top layer and that avoided Integra short comings. The use of MatriDerm in such a big tendon without paratenon successfully by this method is a novel idea.

6. Conclusion

The comprehensive approach involving Matriderm, VAC therapy, and second-stage skin grafting proves to be a promising strategy for promoting healing in cases of bare exposed Achilles tendons, particularly when paratenon is absent.

7. Message

The use of Matriderm with Vacuum-Assisted Closure (VAC) followed by a second-stage skin grafting procedure is a comprehensive approach to promote healing after the longitudinal splitting of the Achilles tendon, especially in cases where the paratenon is absent. The significance of this study lies in the development of a structured protocol that optimizes wound healing, minimizes complications, and supports functional recovery in bare without paratenon Achilles tendons, filling a crucial gap in the existing treatment modalities. This approach is very simple with less learning curve and avoids higher microsurgical skill for flap cover and it is aesthetically more appealing. The presented approach holds promise for improved patient outcomes in challenging cases of exposed Achilles tendon wounds.

8. Source of Funding

None.

9. Conflict of Interest

None.

References

- Inoue T, Tanaka I, Imai K, Hatoko M. Reconstruction of Achilles tendon using vascularized fascia lata with free lateral thigh flap. *Br J Plast Surg*. 1990;43(6):728–31.
- Lee HB, Lew DW, Oh SH, Tark KC, Kim SW, Chung YK, et al. Simultaneous reconstruction of the Achilles tendon and soft-tissue defect using only a latissimus dorsi muscle free flap. *Plast Reconstr Surg*. 1999;104(6):111–31.
- Deiler S, Pfadenhauer A, Widmann J, Stutzle H, Kanz KG, Stock W, et al. Tensor fasciae latae perforator flap for reconstruction of composite Achilles tendon defects with skin and vascularized fascia. *Plast Reconstr Surg*. 2000;106(2):342–9.
- Serel S, Kaya B, Demiralp O, Can Z. Cross-leg free anterolateral thigh perforator flap: a case report. *Microsurgery*. 2006;26(3):190–2.
- Kesiktas E, Yavuz M, Gencel E, Dalay C, Acartürk S. Use of cross-leg latissimus dorsi free flap for repair of extensive lower leg electrical injury in a child. *Burns*. 2006;32:507–10.
- Mozafari N, Moosavizadeh SM, Rasti M. The distally based neurocutaneous sural flap: a good choice for reconstruction of soft tissue defects of lower leg, foot and ankle due to fourth degree burn injury. *Burns*. 2008;34(3):406–11.
- Shakirov BM. Different surgical treatment of post-burn trophic ulcers of the plantar surface in foot burns. *Burns*. 2011;37(8):1439–43.
- Ohata E, Yuzuriha S, Mishima Y, Matsuo K. Longitudinal slit procedure in addition to negative pressure wound therapy for a refractory wound with exposed achilles tendon. *Eplasty*. 2015;15:e9.
- Carr AJ, Norris SH. The blood supply of the calcaneal tendon. *J Bone Joint Surg*. 1989;71(1):100–1.
- Terzioğlu A, Aslan G, Saydam M. Trephination in the treatment of scalp avulsion: successful application of a historical method. *J Oral Maxillofac Surg*. 1999;57(2):204–6.
- Gallagher JJ. Avoiding calvarial defects in a Harrison's class IV thermally injured skull. *Burns*. 2011;37(3):480–3.
- Greer SE, Longaker MT, Margiotta M, Mathews AJ, Kasabian A. The use of subatmospheric pressure dressing for the coverage of radial forearm free flap donor-site exposed tendon complications. *Ann Plast Surg*. 1999;43(5):551–4.
- Repta R, Ford R, Hoberman L, Rechner B. The use of negative pressure therapy and skin grafting in the treatment of soft tissue defects over the Achilles tendon. *Ann Plast Surg*. 2005;55(4):367–70.
- Heugel JR, Parks KS, Christie SS, Pulito JF, Zegzula DH, Kemalyan NA, et al. Treatment of the exposed Achilles tendon using negative pressure wound therapy: A case report. *J Burn Care Rehab*. 2002;23(3):167–71.
- Molnar JA, Defranzo AJ, Hadaegh A, Morykwas MJ, Shen P, Argenta LC, et al. Acceleration of Integra incorporation in complex tissue defects with subatmospheric pressure. *Plast Reconstr Surg*. 2004;113(5):1339–46.
- Brandi C, Grimaldi L, Nisi G, Silvestri A, Brafa A, Calabro M, et al. Treatment with vacuum-assisted closure and cryo-preserved homologous de-epidermalised dermis of complex traumas to the lower limbs with loss of substance, and bones and tendons exposure. *J Plast Reconstr Aesthet Surg*. 2008;61(12):1507–11.
- Moiemen NS, Yarrow J, Kamel D, Kearns D, Mendonca D. Topical negative pressure therapy: does it accelerate neovascularisation within the dermal regeneration template, Integra? A prospective histological in vivo study. *Burns*. 2010;36(6):764–8.
- Alaña, IG, López JT, Playá PM, Zubizarreta FG. Combined use of negative pressure wound therapy and Integra(R) to treat complex defects in lower extremities after burns. *Ann Burns Fire Disasters*. 2013;26(2):90–3.
- Hutchison RL, Craw JR. Use of acellular dermal regeneration template combined with NPWT to treat complicated extremity wounds in children. *J Wound Care*. 2013;22(12):708–12.
- Cunningham T, Marks M. Vacuum-assisted closure device and skin substitutes for complex Mohs defects. *Dermatol Surg*. 2014;40(9):120–6.
- Kang GC, Por YC, Tan BK. In vivo tissue engineering over wounds with exposed bone and tendon: autologous dermal grafting and vacuum-assisted closure. *Annals Plast Surg*. 2010;65(1):70–3.
- Weigert R, Choughri H, Casoli V. Management of severe hand wounds with Integra(R) dermal regeneration template. *J Hand Surg*. 2011;36(3):185–93.
- Hayn E. Successful treatment of complex traumatic and surgical wounds with a foetal bovine dermal matrix. *Int Wound J*. 2014;11(6):675–80.
- Milcheski DA, Chang AA, Lobato RC, Nakamoto HA, Tuma P, Ferreira M, et al. Coverage of deep cutaneous wounds using dermal template in combination with negative-pressure therapy and subsequent skin graft. *Plast Reconstr Surg*. 2014;2(6):170. doi:10.1097/GOX.000000000000108.
- Lee HJ, Kim JW, Oh CW, Min WK, Shon OJ, Oh JK, et al. Negative pressure wound therapy for soft tissue injuries around the foot and ankle. *J Orthopaed Surg Res*. 2009;4:14. doi:10.1186/1749-799X-4-14.
- Helgeson MD, Potter BK, Evans KN, Shawen SB. Bioartificial dermal substitute: a preliminary report on its use for the management of complex combat-related soft tissue wounds. *J Orthopaed Trauma*. 2007;21(6):394–9.
- Wollina U. One-stage reconstruction of soft tissue defects with the sandwich technique: collagen-elastin dermal template and skin grafts. *J Cutan Aesthet Surg*. 2011;4(3):176–82.

28. Violas P, Abid A, Darodes P, Galinier P, De Gauzy J, Cahuzac JP, et al. Integra artificial skin in the management of severe tissue defects, including bone exposure, in injured children. *J Ped Orthoped.* 2005;14(5):381–4.
29. Leitsch S, Koban KC, Pototschnig A, Titze V, Giunta RE. Multimodal therapy of ulcers on the dorsum of the hand with exposed tendons caused by Pyoderma gangrenosum. *Wounds.* 2016;28(3):10–3.
30. Singh S. Use of MatriDerm® (skin substitute) and split skin graft in one stage in wound healing of exposed tibia without periosteum in two patients. *IP Indian J Clin Exp Dermatol.* 2023;9(2):116–9.

Author biography

Sudhir Singh, Hon. IMA Professor & Senior Consultant

Cite this article: Singh S. Comprehensive wound healing approach for exposed achilles tendon without paratenon by utilizing matriderm with vacuum-assisted closure (VAC) and second-stage skin grafting. *IP Indian J Clin Exp Dermatol* 2024;10(3):281-286.