



Original Research Article

Nailfold capillaroscopic changes in diabetes mellitus patients using hand held dermatoscope - A comparative observational study

Abhirut Thakur^{1*}, Gurkim Kaur¹, Devraj Dogra¹¹Government Medical College, Jammu, Jammu and Kashmir, India

ARTICLE INFO

Article history:

Received 10-06-2024

Accepted 17-08-2024

Available online 04-09-2024

Keywords:

Nailfold capillaroscopy

Diabetes

Dermatoscope

ABSTRACT

Background: Diabetes mellitus is a state of chronic hyperglycemia responsible for significant mortality and morbidity rate due to its vascular complications. Nail fold capillaroscopy using dermatoscope is a quick, cost effective screening tool in identifying the patients having chronic diseases like diabetes mellitus. We aimed at observing the nailfold capillaries in diabetes patients using a hand held dermatoscope.

Aim/ Objectives: To study nailfold capillaroscopic changes in diabetes mellitus patients using a dermatoscope.

Materials and Methods: A comparative observational study was conducted involving 100 patients of diabetes mellitus and 100 healthy individuals for nail fold capillaroscopic changes using a dermatoscope over a period of 12 months.

Results: In our study, distribution of gender and age was comparable between patients with diabetes mellitus and healthy individuals. The capillaroscopic variables like tortuous capillary, receding capillary, capillary dilation, neoangiogenesis, avascular area, capillary dropouts and bizarre capillary were significantly higher in patients with diabetes mellitus as compared to healthy individuals. Other parameters like meandering capillary, bushy capillary, microhemorrhage, angulated capillary and subpapillary plexus visibility were not significant in diabetes mellitus patients.

Conclusion: Nailfold capillaroscopy is a simple, quick and effective screening tool for identifying early signs of diabetes mellitus.

This is an Open Access (OA) journal, and articles are distributed under the terms of the [Creative Commons Attribution-NonCommercial-ShareAlike 4.0 License](https://creativecommons.org/licenses/by-nc-sa/4.0/), which allows others to remix, tweak, and build upon the work non-commercially, as long as appropriate credit is given and the new creations are licensed under the identical terms.

For reprints contact: reprint@ipinnovative.com

1. Introduction

Diabetes mellitus refers to a group of metabolic disorders having chronic hyperglycemia which is either secondary to defective release of insulin from beta cells of pancreas, defect in insulin action on target receptors present in target tissues or both.¹ Insulin in pancreas is produced by the β -cells. The pathophysiology of Diabetes mellitus involves progressive loss or dysfunction of pancreatic β -cells resulting in pathological changes to the microvasculature. In Type 1 Diabetes mellitus, there is T-cell mediated autoimmune damage of β cells, while In Type 2 Diabetes

mellitus, there are two insulin-related anomalies: insulin resistance and β -cell dysfunction. In early stages, decreased insulin sensitivity triggers β -cells hyperfunction to achieve compensatory increase in insulin secretion to maintain normoglycemia. But overtime, β -cell function begins to decline resulting in insulin deficiency and hyperglycemia.²

As per the International Diabetes Federation Diabetes Atlas 10th edition, in 2021, approximately 537 million adults (20-79 years) in the world were living with diabetes with a estimated rise to 643 million by 2030 and 783 million by 2045 respectively. Diabetes related healthcare expenditure in 2021 was estimated to be \$ 966 billion, and projected to reach \$ 1054 billion by 2045.³

* Corresponding author.

E-mail address: abhirutthakur@gmail.com (A. Thakur).

The Sustainable Development Goals (SDGs), setup in 2015 by United Nations General Assembly (UNGA) include a target to reduce premature deaths due to non-communicable diseases (NCDs), including diabetes, by one third by 2030. The National Health Policy 2017 of India has set a goal to reduce premature deaths from diabetes by 25% by 2025.⁴

In order to prevent and control major non-communicable diseases including Diabetes, National Another Programme (National Prevention and Control of Cancer, Diabetes, Cardiovascular Diseases and Stroke) to prevent and control major non-communicable diseases including Diabetes was launched in 2010 by Government of India under National Health Mission (NHM). This programme aims to prevent and control common non-communicable diseases including diabetes by increasing community awareness, facilitating early detection of undiagnosed cases, and linking the identified cases with the health system for follow-up and continuity of care.⁵

Diabetes-related complications affect many organ systems including skin and are responsible for significant morbidity and mortality. Diabetes chronic complications can either be microvascular (retinopathy, neuropathy and nephropathy) as well as macrovascular (stroke, cardiovascular disease, peripheral arterial disease) with former having greater prevalence than latter.⁶

Diabetes mellitus is associated with skin involvement in 79.2 % individuals. Commonest skin manifestations in diabetes include cutaneous infections (47.5%), xerosis (26.4%), and inflammatory skin diseases like granuloma annulare, diabetic blisters etc. (20.7%). Cutaneous manifestations can appear as the first sign of diabetes or may develop at any time in the course of the disease.⁷ NailfoldCapillaroscopy is a rapid, highly specific and reproducible investigation which involves visualisation of nailfold capillaries. To be strictly accurate, the structures visualised in capillaroscopy are not the capillaries themselves, the thin walls of which are transparent, but instead column of red blood cells. The different techniques for doing capillaroscopy are Widefield stereomicroscopy, High magnification videocapillaroscopy and handheld devices like – ophthalmoscopes, USB microscopes, dermatoscope.⁸

Capillaroscopy using bimicroscope or operating microscope often necessitates referral to some specialised center. Ophthalmoscope too has been advocated for capillaroscopy but has limitation of field being too small for proper investigation. Dermatoscope has a relatively large field of view and offers a simple, quick and inexpensive method to do nail fold capillaroscopy.⁹ Moreover, the results of capillaroscopy using dermatoscope are equivalent if not better than standard capillary microscopy.¹⁰

Recently, it has been suggested that dermoscopy being simple, fast, non-invasive, portable and inexpensive

tool can replace capillaroscopy for detection of nailfold abnormalities in systemic diseases.¹¹

2. Materials and Methods

This was a comparative observational study conducted over a period of 12 months (1ST NOV 2020 TO 31ST OCT 2021) in Government Medical College Jammu and associated hospitals after taking Institutional ethical committee clearance and informed consent from each participant prior to the start of the study. 2 groups of 100 participants each: diabetics and normal healthy individuals were studied. All the patients who were diagnosed with Diabetes mellitus attending Dermatology/Endocrinology OPD of Government Medical College, Jammu were included regardless to age, sex, ethnic origin and occupation. Comparison group comprised healthy individuals without any comorbidities including diabetes mellitus. All the diabetic patients were of Type 2 diabetes mellitus. A predesigned proforma was used to record relevant history and clinical findings in the patients. The latest HbA1c of all diabetic patients was also noted. Patients with Connective tissue diseases, systemic diseases like hypertension which cause retinopathy and vasculopathy in nailfolds, pregnant women, patients with sepsis or organ dysfunction (liver/kidney/heart), smokers, patients having history or evidence of onychophagia, onychotillomania, trauma, nail infections and recent manicure were excluded from the study.

2.1. Nailfold capillaroscopy (NFC) examination

2.1.1. Dermoscopic examination

Dermoscopic examination was done using DermLite DL4 which is 4th generation handheld DermLitedermoscope with features of two brightness levels, a larger field of view using a 30 mm lens, 10x zoom and is 25% smaller than the previous generation. While doing direct skin contact, DL4's IceCap® is used. It can attach to glass faceplate and greatly reduces the risk of cross-contamination. The phone Redmi K20 Pro was used in the study to click the images and keep the photographic record. Ultrasound Jelly was used as Interface medium as it improved visualization of proximal nailfold capillaries and its greater viscosity than other interface media made it the ideal choice. [Figure 1]

2.2. Technique of Nailfoldcapillaroscopy (NFC)¹²

All patients selected for nailfoldcapillaroscopy examination were made to sit for 15-20 minutes in a room having normal ambient temperature (20-22°C). Both hands were placed over a dull non-refractile surface at the level of heart. Ultrasound Jelly was placed over proximal nailfold. Then the dermatoscope with IceCap attached, was placed over it at an appropriate angle but not pressed to avoid blanching of the blood vessels. Proximal Nailfold capillaries of 8 fingers (excluding thumbs) were examined first at 10x and them

image zoomed upto 100x for noting qualitative changes if any. At least 1 sharply focused image in JPEG format of each digit's nailfold capillaries was clicked for future analysis.

Quantitative parameter i.e. Mean Capillary Density was calculated by analysis of 4th and 5th fingers of both hands. These two fingers were chosen because of the high transparency and being less prone to day-to-day trauma. With the help of 1 mm markings seen in images clicked by DermLite DL4, quantitative analysis was done. All the qualitative findings noted were entered in the proforma both at the time of examination. [Figure 2]

2.3. NFC & COVID-19 pandemic:¹³

Surface of the table was kept clean using 70% isopropyl alcohol and patient was asked to wash hands or use hand sanitizer before performing NFC. IceCap used was frequently changed after few examinations and disinfected with 70% isopropyl alcohol in each examination. An effort was made to minimize the duration of procedure. That's why thumbs were not examined in the study. The following NFC parameters were recorded:

1. Quantitative parameters: Mean capillary density was calculated as the number of distal most capillary loops in 4th and 5th fingers of both the hands per millimeter.
2. Qualitative parameters: The various capillaroscopic abnormalities (mentioned in table below) were carefully visualized and recorded.

Subpapillary plexus visibility was also evaluated in proximal nail fold which lies just beneath the dermal papillae in skin. Bushy capillaries were counted under Neoangiogenesis. Also, definition of Neoangiogenesis is broad and indicates new vessel formation in the form of abnormal shapes seen in NFC (other shapes than hairpin, tortuous, or crossing).¹⁵

2.4. Statistical analysis

The Categorical variables were presented in the form of number and percentage (%) while the quantitative data was presented as the means ± SD and as median with 25th and 75th percentiles (interquartile range). The comparison of the variables which were quantitative in nature was analyzed using Independent t test (for two groups) and ANOVA test (for more than two groups) and variables which are qualitative in nature was analyzed using Chi-Square test. If any cell had an expected value of less than 5 then Fisher's exact test was used. For statistical significance, p value of less than 0.05 was considered statistically significant.

3. Results

Distribution of gender was comparable between patients with diabetes mellitus and healthy individuals in our present

Table 1: Definition of various qualitative abnormalities observed in NFC.¹⁴

Abnormality	Definition
Tortuous capillary	Capillary limb curled but not crossing over; tortuosity in <5% is considered normal
Meandering capillary	Limbs crossed upon themselves
Dilated capillary	Width more than two times surrounding normal capillaries
Giant capillary	Width of the capillary >10 times the normal
Neoangiogenesis/ Bushy capillary	Small, multiple buds originating from the distal loop
Focal microhemorrhages	Singularly placed micro-petechiae
Diffuse microhemorrhages	Multiple micro-petechiae present in groups
Capillary drop outs	Absence of individual capillary loop
Avascular area	Absence of two or more adjacent capillaries from the distal most row
Bizarre capillaries	Atypical morphology differing from the predefined morphologies
Receding Capillaries	Individual capillaries maintaining their position in distal-most row but which were slightly proximal to distal-most loops
Angulated Capillaries	Special type of tortuous capillary with one or both arms of distal capillary loop bent at an angle

study having p value=1. Mean ± SD of age (years) in patients with diabetes mellitus was 47.94 ± 9.52 and healthy individuals was 45.42 ± 9.91 with no significant difference between them. (p value=0.068). (Table 2)

Mean ± SD of mean capillary density(capillaries/mm) in patients with diabetes mellitus was 6.69 ± 0.37 which was significantly lower as compared to healthy individuals (7.23 ± 0.38).(p value <.0001). Proportion of patients with tortuous capillary was remarkably higher in patients of diabetes as compared to healthy controls (p value <0.0001). (Figure 3)

Proportion of patients having receding capillary (48% vs 11% respectively) was significantly higher in diabetic as compared to healthy individuals with p value <0.0001 (Figure 4). Proportion of patients with capillary dilation was also greater in diabetics as compared to healthy individuals (46% vs 19% respectively). (p value <0.0001). (Figure 5)

Distribution of variables like meandering capillary (Absent:- 62% vs 71% respectively, Present:- 38% vs 29% respectively) (p value=0.178) and bushy capillary was comparable between both the groups(Absent:- 94% vs 95% respectively, Present:- 6% vs 5% respectively) (p value=0.756). (Table 3, Figure 6)

Proportion of patients having neoangiogenesis (27% vs 7% respectively) (p value=0.0002) and avascular areas was

significantly higher in diabetics as compared to healthy individuals (21% vs 3% respectively). (p value=0.0001) (Table 4, Figure 7)

Proportion of patients with capillary dropout was higher in patients with diabetes as compared to healthy population (30% vs 17% respectively). (p value=0.03) (Table 5). Distribution of microhemorrhages (p value= 1) and angulated capillary (p value=0.171) was comparable between patients of diabetes mellitus and healthy individuals. (Table 6). Proportion of patients having bizarre capillary was comparatively higher in patients of diabetes as compared to healthy individuals (16% vs 3% respectively). (p value=0.003) (Table 7). Distribution of subpapillary plexus visibility was comparable between patients and healthy individuals. (Absent:- 75% vs 81% respectively, Present:- 25% vs 19% respectively) (p value=0.306). (Table 8, Figure 8)



Figure 1: Equipments: 1: Phone; 2: Dermoscope; 3: IceCap; 4: Universal Smartphone Adapter; 5: Ultrasound Jelly

4. Discussion

The microvascular changes associated with diabetes mellitus have also been shown to affect nailfold capillaries which are horizontally oriented capillaries parallel to the skin in proximal nailfold.¹⁶

With an increasing availability of high-quality dermatoscopes, it is possible to evaluate nailfold capillary microvascular changes in a faster and reliable way.¹⁴ Hand-held dermatoscopes is a device which offers low magnification (upto 10x in DermLite DL4) but excellent optical resolution and images. Also, they are easy to use and can be easily connected to smartphones. So, they are a better device from practical point of view making them a preferred choice over videodermatoscopes (used for research purposes) in real world scenario.¹²

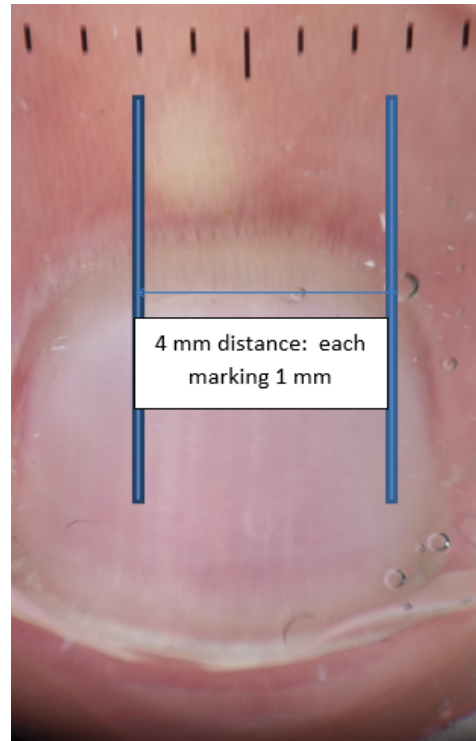


Figure 2: Nailfold capillaroscopy in a healthy individual, Showing 1 mm black markings and method of ascertaining 4 mm distance to calculate mean capillary density as explained in the methodology.

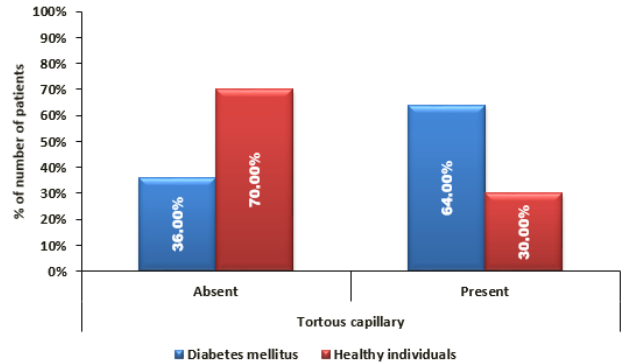


Figure 3: Comparison of tortuous capillary between diabetes mellitus and healthy individuals.

In this study, nailfold capillaroscopy was done using hand-held dermatoscope in 100 diabetics and 100 healthy normal individuals were evaluated in the comparison group. 50 diabetics also had microvascular complication in the form of diabetic retinopathy (DR) and 50 had no retinopathy. In study by Jakhar et al 96 diabetics (46 with microvascular complications and 50 without) and 40 healthy controls were studied.

In our present study, gender distribution was comparable between diabetics and healthy individuals. (Female: - 49%

Table 2: Comparison of demographic characteristics between diabetes mellitus and healthy individuals.

Demographic characteristics	Diabetes mellitus (n=100)	Healthy individuals(n=100)	Total	P value
Gender				
Female	49 (49%)	49 (49%)	98 (49%)	1 ^Ē
Male	51 (51%)	51 (51%)	102 (51%)	
Age (years)				
Mean ± SD	47.94 ± 9.52	45.42 ± 9.91	46.68 ± 9.77	0.068*
Median (25th-75 percentile)	47(40-54.25)	45(39-53)	46(40-54)	
Range	24-75	21-68	21-75	

* Independent t test, ^Ē Chi square test

Table 3: Comparison of meandering and bushy capillary between diabetes mellitus and healthy individuals.

Meandering capillary	Diabetes mellitus (n=100)	Healthy individuals (n=100)	Total	P value
Absent	62 (62%)	71 (71%)	133 (66.50%)	0.178‡
Present	38 (38%)	29 (29%)	67 (33.50%)	
Total	100 (100%)	100 (100%)	200 (100%)	
Bushy capillary	Diabetes mellitus (n=100)	Healthy individuals (n=100)	Total	P value
Absent	94 (94%)	95 (95%)	189 (94.50%)	0.756‡
Present	6 (6%)	5 (5%)	11 (5.50%)	
Total	100 (100%)	100 (100%)	200 (100%)	

^Ē Chi square test

Table 4: Comparison of neoangiogenesis and avascular areas between diabetes mellitus and healthy individuals.

Neoangiogenesis	Diabetes mellitus (n=100)	Healthy individuals (n=100)	Total	P value
Absent	73 (73%)	93 (93%)	166 (83%)	0.0002‡
Present	27 (27%)	7 (7%)	34 (17%)	
Total	100 (100%)	100 (100%)	200(100%)	
Avascular area	Diabetes mellitus (n=100)	Healthy individuals (n=100)	Total	P value
Absent	79 (79%)	97(97%)	176(88%)	0.0001†
Present	21 (21%)	3(3%)	24(12%)	
Total	100 (100%)	100(100%)	200(100%)	

[†] Fisher's exact test ^Ē Chi square test

Table 5: Comparison of capillary dropout between diabetes mellitus and healthy individuals.

Capillary dropout	Diabetes mellitus (n=100)	Healthy individuals (n=100)	Total	P value
Absent	70(70%)	83(83%)	153(76.50%)	0.03 ^Ē
Present	30(30%)	17(17%)	47(23.50%)	
Total	100(100%)	100(100%)	200(100%)	

^Ē Chi square test

vs 49% respectively, Male:- 51% vs 51% respectively) (p value=1). In contrast, study done by Mohanty et al.¹⁷ had male predominance with 64.8% males and 35.2% females respectively among 250 diabetic patients. Mean ± SD of age (years) in patients with diabetes mellitus was 47.94 ± 9.52 and healthy individuals was 45.42 ± 9.91 with statistically no significant difference between them. (p value=0.068). This is similar to study conducted by Lima et al¹⁸ with no remarkable difference (p value = 0.12) between the two

groups.

Mean ± SD of mean capillary density i.e. MCD (capillaries/mm) in patients with diabetes mellitus was 6.69 ± 0.37, which was significantly lower as compared to healthy individuals (7.23 ± 0.38).(p value <.0001). The results were similar to study conducted by Lima et al¹⁸ which showed significant reduction in MCD in diabetics 6.12 (5.5-7.0) vs 7.12 (7.0-7.4) in controls.(p value <0.0001). Barchetta et al¹⁹ in his study has reported that

Table 6: Comparison of microhemorrhages and angulated capillaries between diabetes mellitus and healthy individuals.

Microhemorrhages	Diabetes mellitus (n=100)	Healthy individuals(n=100)	Total	P value
Absent	73 (73%)	73 (73%)	146 (73%)	1‡
Present	27 (27%)	27 (27%)	54 (27%)	
Total	100 (100%)	100 (100%)	200 (100%)	
Angulated capillary	Diabetes mellitus (n=100)	Healthy individuals (n=100)	Total	P value
Absent	81 (81%)	88 (88%)	169(84.50%)	0.171‡
Present	19 (19%)	12 (12%)	31(15.50%)	
Total	100 (100%)	100 (100%)	200(100%)	

‡ Chi square test

Table 7: Comparison of bizarre capillary between diabetes mellitus and healthy individuals.

Bizarre capillary	Diabetes mellitus(n=100)	Healthy individuals(n=100)	Total	P value
Absent	84 (84%)	97 (97%)	181 (90.50%)	0.003 ^Đ
Present	16 (16%)	3 (3%)	19 (9.50%)	
Total	100 (100%)	100 (100%)	200 (100%)	

^Đ Fisher’s exact test

Table 8: Comparison of subpapillary plexus visibility between diabetes mellitus and healthy individuals.

Subpapillary plexus visibility	Diabetes mellitus(n=100)	Healthy individuals(n=100)	Total	P value
Absent	75(75%)	81(81%)	156(78%)	0.306 ^È
Present	25(25%)	19(19%)	44(22%)	
Total	100(100%)	100(100%)	200(100%)	

^È Chi square test

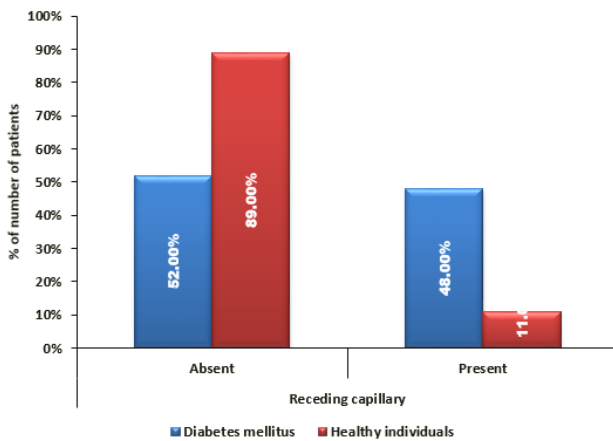


Figure 4: Comparison of receding capillary between diabetes mellitus and healthy individuals.

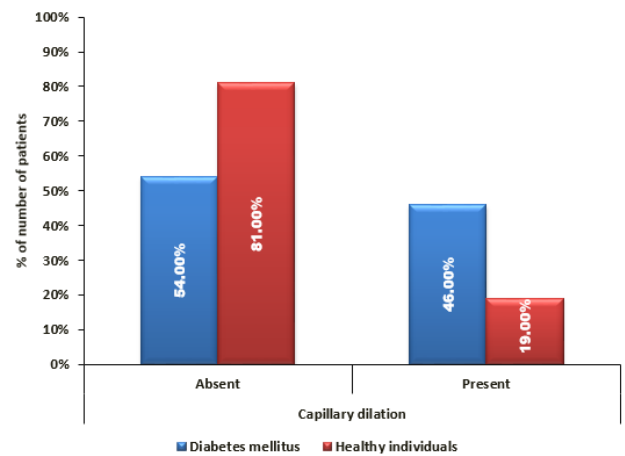


Figure 5: Comparison of capillary dilation between diabetes mellitus and healthy individuals.

10.7% of type 2 diabetics have a MCD <8 capillaries/mm.

The qualitative capillary changes observed in healthy controls were Tortuosity (30%), meandering capillary (29%), microhemorrhages (27%), sub papillary plexus visibility (19%), dilated capillary (19%) etc. Similar observations have been made in literature as well by Jakhar et al, Dolezalova, Martino et al.^{14,20,21}

In the present study, proportion of patients with tortuous capillary was notably higher in patients of diabetes as compared to healthy individuals (64% vs 30% respectively). Proportion of patients having receding capillary and capillary dilation was also noteworthy in diabetics as compared to healthy individuals.



Figure 6: Meandering capillary

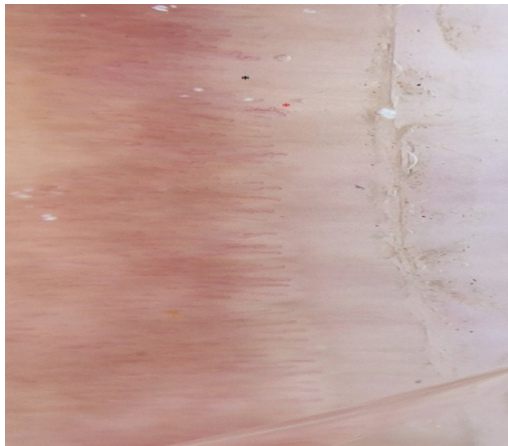


Figure 7: Black* showing avascular area and Red * showing budding capillary/neoangiogenesis

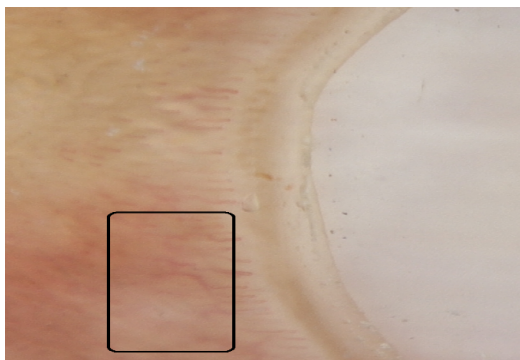


Figure 8: Sub papillary plexus

Proportion of patients with neoangiogenesis was remarkably higher in diabetics as compared to healthy individuals (27% vs 7% respectively). Proportion of patients having avascular area, capillary dropouts and bizarre capillary was also higher in patients of diabetes mellitus as compared to healthy controls. Capillaroscopic parameters like meandering capillary (p value=0.178), bushy capillary (p value=0.756), microhemorrhage (p value=1), angulated capillary (p value=0.171) and subpapillary plexus visibility (p=0.306) were not significant in diabetics in comparison to healthy individuals.

Thus, in nail fold capillaroscopic changes in our study, the statistically significant findings noted among diabetics were tortuous capillaries, receding capillaries, capillary dilation, capillary dropouts, neoangiogenesis, avascular areas and bizarre capillaries. Angulated capillaries as reported by Jakhar et al¹⁴ were found more commonly in diabetic patients than the healthy individuals .

The study by Uyar et al²² showed in diabetic patients tortuosity, bushy capillary, neoangiogenesis, bizarre capillaries, microhemorrhage, capillary ectasia and aneurysm were significantly increased than healthy controls. Our results are near comparable to this study however bushy capillaries were not significant in our study. In one study by, Lima et al¹⁸ he observed increased number of ectasias/dilations and increased presence of avascular areas. These observations are similar to our study.

5. Conclusion

Significant nail fold capillaroscopic changes were seen in patients of diabetes in comparison to healthy individuals. NFC using dermatoscope is a quick, easy to perform, safe and cost effective technique to detect early changes in the micro vascular bed which can be used to assess severity of disease. Our results suggest that it could possibly become a useful tool in diabetics to diagnose as well as monitor various micro vascular complications in the future.

6. Source of Funding

None.

7. Conflict of Interest

None.

References

1. Kharroubi AT. Diabetes mellitus: The epidemic of the century. *World J Diabetes*. 2015;6(6):850–67.
2. Moini J. Pathophysiology of Diabetes. In: *Epidemiology of Diabetes*. Elsevier; 2019. p. 25–43.
3. Sun H, Saeedi P, Karuranga S, Pinkepank M, Ogurtsova K, Duncan BB, et al. IDF Diabetes Atlas: Global, regional and country-level diabetes prevalence estimates for 2021 and projections for 2045. *Diabetes Res Clin Pract*. 2021;p. 109119. doi:10.1016/j.diabres.2021.109119.
4. Tandon N, Anjana RM, Mohan V, Kaur T, Afshin A, Ong K, et al. The increasing burden of diabetes and variations among the states of India: the Global Burden of Disease Study. *Lancet Glob Heal*. 1990;6(12):1352–62.
5. Abdel-All M, Abimbola S, Praveen D, Joshi R. What do Accredited Social Health Activists need to provide comprehensive care that incorporates non-communicable diseases? Findings from a qualitative study in Andhra Pradesh. *Hum Resour Health*. 2019;17(1):73. doi:10.1186/s12960-019-0418-9.
6. Papatheodorou K, Banach M, Bekiari E, Rizzo M, Edmonds M. Complications of Diabetes. *J Diabetes Res*. 2018;p. 3086167. doi:10.1155/2018/3086167.
7. Duff M, Demidova O, Blackburn S, Shubrook J. Cutaneous Manifestations of Diabetes Mellitus. *Clin Diabetes*. 2015;33(1):40–8.
8. Parker MJS, McGill NW. The Established and Evolving Role of Nailfold Capillaroscopy in Connective-Tissue Disease. In: *The Established and Evolving Role of Nailfold Capillaroscopy in Connective-Tissue Disease*. IntechOpen; 2020.
9. Bergman R, Sharony L, Schapira D, Nahir MA, Balbir-Gurman A. The Handheld Dermatoscope as a Nail-Fold Capillaroscopic Instrument. *Arch Dermatol*. 2003;139(8):1027–30.
10. Bauersachs RM, Lössner F. The poor man's capillary microscope. A novel technique for the assessment of capillary morphology. *Ann Rheum Dis*. 1997;56(7):435–7.
11. Barbach Y, Chaouche M, Cherif AD, Elloudi S, Baybay H, Mernissi FZ, et al. Dermoscopy of Nail Fold Capillaries in Connective Tissue Diseases. *Madridge J Case Rep Stud*. 2019;3(1):130–1.
12. Grover C, Jakhar D. Hand-held dermatoscope or videodermatoscope: Which one to buy? *Indian J Dermatol Venereol Leprol*. 2021;87(5):739–41.
13. Jakhar D, Grover C. Challenges in Performing Nail-Fold Capillaroscopy during COVID-19. *Ski Appendage Disord*. 2021;7(3):246–7.
14. Jakhar D, Grover C, Singal A, Das G, Madhu S. Nail fold capillaroscopic changes in patients with type 2 diabetes mellitus: An observational, comparative study. *Indian J Med Spec*. 2020;11(1):28.
15. Dima A, Berza I, Popescu DN, Parvu MI. Nailfold Capillaroscopy in Systemic Diseases: Short Overview for Internal Medicine. *Rom J Intern Med*. 2021;59(3):201–17.
16. Grover C, Jakhar D. Diagnostic Utility of Onychoscopy: Review of Literature. *Indian J Dermatopathol Diagnostic Dermatol*. 2017;4(2):31–40.
17. Mohanty G, Padhan P, Chilakamarthy S, Das MK, Bhuyan D. Can Nailfold Capillaroscopy Be a Screening Tool for Diabetic Retinopathy - A Hospital Based Cross-Sectional Study in Orissa, India. *J Evid Based Med Healthc*. 2021;8(20):1479–83.
18. Lima CF, Morais IH, Suckow K, Nisihara R, Skare T. Nailfold capillaroscopy and microvascular involvement in Diabetes Mellitus. *Sci Med*. 2021;31(1):39679. doi:10.15448/1980-6108.2021.1.39679.
19. Barchetta I, Riccieri V, Vasile M, Stefanantoni K, Comberiat P, Taverniti L, et al. High prevalence of capillary abnormalities in patients with diabetes and association with retinopathy. *Diabet Med*. 2011;28(9):1039–44.
20. Dolezalova P, Young SP, Bacon PA, Southwood TR. Nailfold capillary microscopy in healthy children and in childhood rheumatic diseases: a prospective single blind observational study. *Ann Rheum Dis*. 2003;62(5):444–9.
21. Martino F, Agolini D, Aprigliano D, Guido F, Placanica G, Giardini O, et al. Nailfold capillaroscopy in normal children between 0 and 16 years of age. *Minerva Pediatr*. 1997;49(5):197–201.
22. Uyar S, Balkarlı A, Erol MK, Yeşil B, Tokuç A, Durmaz D, et al. Assessment of the Relationship between Diabetic Retinopathy and Nailfold Capillaries in Type 2 Diabetics with a Noninvasive Method: Nailfold Videocapillaroscopy. *J Diabetes Res*. 2016;p. 7592402. doi:10.1155/2016/7592402.

Author biography

Abhirut Thakur, Senior Resident

Gurkim Kaur, Senior Resident

Devraj Dogra, Professor and Head

Cite this article: Thakur A, Kaur G, Dogra D. Nailfold capillaroscopic changes in diabetes mellitus patients using hand held dermatoscope - A comparative observational study. *IP Indian J Clin Exp Dermatol* 2024;10(3):310-317.