

## Nails- a window to internal organs: a cross sectional study of nail changes in systemic diseases in a tertiary care hospital

Dhanalakshmi Kathirvel<sup>1,\*</sup>, Baskaran R<sup>2</sup>, Vaishnavi Dhandapani<sup>3</sup>, Gladius Jennifer H<sup>4</sup>

<sup>1</sup>Assistant Professor, <sup>2</sup>Professor & HOD, <sup>3</sup>Senior Resident, Dept. of Dermatology, <sup>4</sup>Assistant Professor, Dept. of Community Medicine, Karpaga Vinayaga Institute of Medical Sciences & Research Centre, Tamil Nadu

**\*Corresponding Author:**

Email: drdhanuk@gmail.com

### Abstract

**Background:** Many systemic disorders leave their mark on the nails and, therefore, provide physicians with valuable clues to diagnosis. In spite of this knowledge, there has been relatively little attention paid to the nails. This study will enlighten the importance of the nail changes associated with systemic diseases.

### Objectives of the study:

- To evaluate the prevalence of the nail changes in systemic diseases.
- To assess the specificity of the nail changes with the disease status.
- To correlate nail changes with prognosis.

**Materials and Methods:** One hundred and fifty patients attending the outpatient and inpatients from the hospital were included. With informed consent, detailed history and clinical examination done including general physical examination and cutaneous examination. Nails were examined for their appearance, colour, contour, lunula, nail folds. Investigations were done according to the system involvement.

**Results:** Nail changes were common with inpatients (58.7%) compared to out-patients (41.3%) and in 5.4% patients it was incidental. Most commonly involved systems include respiratory system (23.4%) followed by haematopoietic (18%), GIT and liver (14%), renal (12%) and cardiovascular system (10%). Clubbing was the commonest nail change encountered (34.67%) followed by longitudinal ridging (29.33%), pallor of nail plate (28%), platyonychia (18.67%) and brittle nails (17.33%).

**Conclusions:** Clubbing in cardio respiratory system, half and half nail (HHN) in renal system and terry's nail in liver and GIT are the specific nail changes that can lead us to the diagnosis. Prognosis is not directly related to the nail changes, commonly to the severity of the underlying disorders.

**Keywords:** Nail changes, Clubbing, Platyonychia.

### Introduction

The human nail, the horny covering of the dorsal surface of the tips of each finger and toe is a set of complex structure that can be called as nail unit.<sup>(1)</sup> Nail is the part of dermatology which is not given much importance unless otherwise a gross abnormality is present. Nail abnormalities secondary to systemic diseases are important because they are readily examined and may be the initial sign that the systemic disease is present. In many situations nail changes may precede, co-exist or follow the diseased state. Some nail findings may represent a part of symptom complex that may be useful for the physical diagnosis. The knowledge of the correct onychopathological cause may give the patient the correct nail prognosis and may assist in proper institution of the therapy.

Daniel (1997) highlighted a few important points relating to the examination of abnormal nails. If these tests are performed, they provide a more accurate examination. Always examine all 10 fingernails and all 10 toenails. For the most part, fingernails provide more subtle information than toenails because trauma is more likely to change or hide certain clinical manifestations in toenails<sup>2</sup>.

- Study the nails with the fingers completely relaxed and not pressed against any surface. Blanch the

fingertip to see if the pigmented abnormality is grossly altered. This test may aid in differentiating the discoloration of the vascular bed of the nail from the discoloration of the nail plate.

- Illumination of the nail can be achieved with a penlight placed against the finger pulp shining up through the nail. If the discoloration is in the matrix or soft tissue, its exact position can be more easily identified. If upon illumination, the discoloration disappears, it is more likely to be in the vascular bed.
- Try scraping the surface of the nail plate, or try cleansing locally or cleansing with a solvent (e.g., acetone).
- Nail changes associated with systemic disease often occur in the matrix so that the leading edge of the abnormality is usually shaped like the distal portion of the matrix. To estimate the time at which the initial insult occurred, one can measure the distance from the proximal nail fold (cuticle) to the leading edge of the pigmentation change.

General diseases-associated nail disorders may be classified into 5 types according to their clinical impact.<sup>(3)</sup>

- Type I refers to nail disorders considered as peculiar features among the various symptoms of

general disease such as peri-ungual vascular dilatation, onycholysis, Beau lines, opaque nails or melanonychia.

- Type II refers to nail disorders with a strong clinical value such as Terry's nails, Muerhrcke's lines or koilonychia.
- Type III refers to nail disorders presenting as significant syndromes of several diseases such as yellow-nail syndrome or subungueal splinter haemorrhages,
- Type IV to specific disorders considered as true keys for diagnosis such as digital Koenen's tumor, or nail hypoplasia.
- In type V are included drug-induced nails disorders especially after chemotherapy or antiretroviral therapy.

### Materials and Methods

150 patients were selected from patients attending the out-patient and in-patient departments. Males and females of all age groups with nail changes with underlying systemic diseases were included. Nail changes associated with dermatological disease like psoriasis, drug induced nail changes and connective tissue diseases like SLE, nail changes associated with isolated diabetes or hypertension, infection of the nails are excluded from the study.

With informed consent, patients were enrolled with a questionnaire for the demographic details. A thorough clinical history about their symptoms (either nail or systemic), duration, age of onset and course of the disease and also the previous medical record. Family, personal history and menstrual history were noted.

Detailed general physical examination and systemic examination was done to note the involvement of the systems accordingly. Nails were examined for their appearance, colour and contour, appearance of the lunula, surface changes, nail folds appearance and other findings like Terry's nail, half and half nail.

According to the system involvement, patients were subjected to complete hemogram, blood sugar levels both fasting and postprandial levels, blood urea and serum creatinine, complete urine examination, liver function test, ECG/ECHO, USG abdomen, Nail clipping and scrapings for KOH examination. Other investigations like ELISA testing for HIV, serum electrolytes, ascitic fluid analysis, CT scan were also included according to the patient need.

Patients enrolled in the study were counselled professionally regarding their condition. The patients with treatable nail changes (platyonychia, koilonychia) were given treatment accordingly. Some non-specific nail changes like Beau's lines were reassured regarding the condition. Nail changes like half and half nail were advised regarding the underlying illness and the treatment options.

### Results

In this study most common age group was found to be 31-40 years, 42 patients (28%) had nail changes, followed by 21-30 years, 38 patients (25.3%) with youngest being 7 years old male and the oldest was 67 year old female with the mean age of 35 years. 82 (54.7%) were males and 68 (45.3%) were females with the sex ratio of 1.2: 1. Nail changes in inpatients 88 (58.7%) outnumbered out patients 62 (41.3%).

Although in 8 (5.4%), nail changes were incidental finding, but 126 (84%) presented with systemic symptoms, 16 (10.6%) presented with nail symptoms.

In 8 patients where the nail changes were incidental finding, 3 had HHN and diagnosed as CRF, 1 had triangular lunula & diagnosed as nail patella syndrome, 1 had clubbing and found to have chronic bronchitis.

Out of 16 patients who presented with nail changes as symptoms, 10 had platyonychia/koilonychia and led to the diagnosis of nutritional anaemia and anaemia due to other causes, 2 had onycholysis which led to the diagnosis of hyperthyroidism and one had yellow nail syndrome.

In this study nail changes were most commonly seen in patients who were symptomatic for more than 1 year 77 (51.3%) than shorter duration (days- 1 month), only 8(5.4%). Diabetes was associated with 16(10.6%), diabetes & hypertension in 16 (10.6%), HIV in 9 (6%) and hypertension alone in 6 (10.6%).

In our study, most commonly involved systems include respiratory system 35(23.4%) followed by hematopoietic 27 (18%), GIT and liver 21 (14%), renal 18 (12%) and cardiovascular system 15 (10%). Involvement of multiple systems was seen in 21(14%). CNS and endocrine involvement was seen in two cases each (1.3%).9(6%) was associated with recurrent fever, protein energy malnutrition. (Fig. 1)

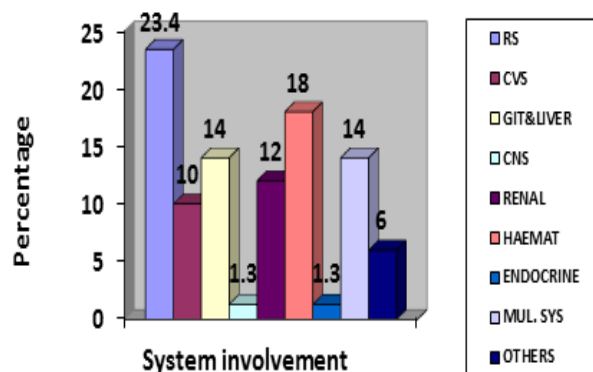


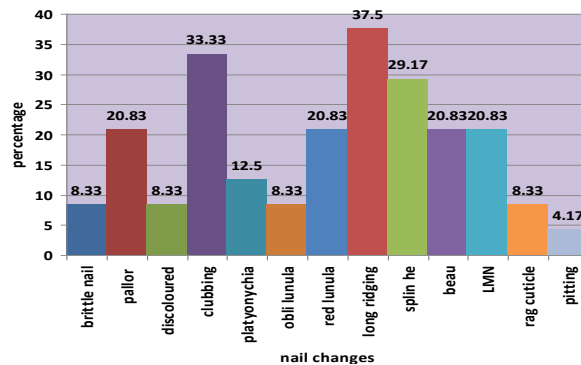
Fig. 1: Distribution of system involvement

Clubbing was the commonest nail change encountered 52 (34.67%) followed by longitudinal ridging 44 (29.33%), pallor of nail plate 42 (28%), platyonychia 28 (18.67%) and brittle nails 26 (17.33%). Other changes include longitudinal melanonychia

23(15.33%), Beau’s lines 19 (12.67%), obliterated lunula 16 (10.67%), splinter haemorrhages 12 (8%), ragged cuticle 11 (7.33%), half and half nail, terry’s nail and discoloration of the nail plate 10 (each 6.67%). Two cases of Muerchke’s lines (1.33%), one case of each triangular lunula and yellow nail syndrome (0.67%) were also noted. (Table 1)

In our study clubbing was the commonest nail change encountered and it was commonly associated with respiratory system followed by liver and GIT, renal and cardiovascular system. In respiratory system (35 patients) chronic bronchitis was the commonest followed by pulmonary tuberculosis, COPD and interstitial lung diseases. In liver and GIT, cirrhosis with portal hypertension and alcoholic liver disease were associated with clubbing commonly followed by hepatitis and Crohn’s disease. In renal system clubbing was associated with CRF (both on and not on haemodialysis).

In our study, involvement of cardiovascular system with nail changes accounted for 24 cases. Of this, longitudinal ridging was the commonest nail change 9 (37.5%) followed by clubbing 8 (33.33%), splinter haemorrhages 7(29.17%), Beau’s lines, red lunula, pallor of nail bed and longitudinal melanonychia 5 (20.83% each) and platyonychia in 3(12.5%). (Fig. 2)



**Fig. 2: Nail changes associated with cardiovascular disease**

In this study, out of 49 cases with involvement of respiratory system, commonest nail change was clubbing in 35 (71.42%) followed by longitudinal ridging in 14 (28.57%), Beau’s lines and longitudinal melanonychia each 9(18.36%), brittle nails in 6(12.24%) and ragged cuticle and discoloured nail plate each in 4(8.16%). Yellow nail syndrome was seen in 1 case constituting 2.04 (Table 1).

Of 31 cases who had GIT and liver involvement, common nail changes include pallor of nail plate in 17(54.8%), clubbing and longitudinal melanonychia each accounting for 12(38.7%), terry’s nail in 10(32.35%), obliterated lunula in 8(25.8%), brittle nail in 6(19.3%), platyonychia in 5(16.12%) and Beau’s lines in 4(12.9%).(Table 1)

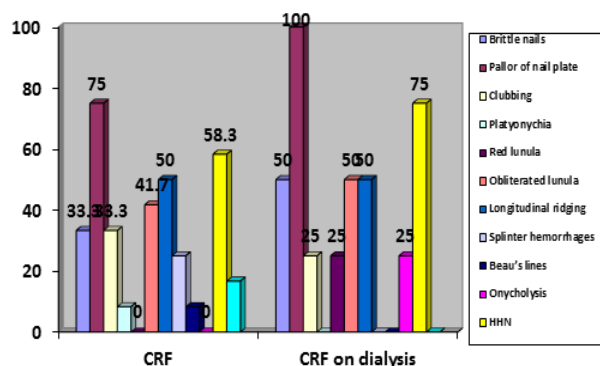
**Table 1: Nail changes associated with systemic diseases**

Nail change		Systemic diseases	CVS	RS	GIT & Liver	Renal	Haemato Poietic
		N (%)	N (%)	N (%)	N (%)	N (%)	N (%)
Appearance	Brittle	26 (17.33)	2(8.33)	6(12.24)	6(19.35)	6(25)	13(32.5)
	Hard	2(1.33)		2(4.08)			
Colour	Pale	42(28)	5(20.83)	6(12.24)	17(54.83)	16(66.67)	34(85)
	Yellow	1(0.67)		1(4.08)		3(12.5)	
	Discoloration	10(0.67)	2(8.33)	4(8.16)	1(3.22)		
Contour	Clubbing	52(34.67)	8(33.33)	35(71.42)	12(38.70)	5(20.83)	5(12.5)
	Platyonychia	28(18.67)	3(12.5)	3(6.12)	5(16.12)	2(8.33)	22(55)
	Koilonychia	11(7.33)			1(3.22)		9(22.5)
Lunula	Obliterated	16(10.67)	2(8.33)	1(4.08)	8(25.8)	7(29.17)	4(10)
	Red	5(3.33)	5(20.83)	1(4.08)		1(4.17)	2(5)
	Triangular	1(0.67)				1(4.17)	
Longitudinal ridging		44(29.33)	9(39.5)	14(28.7)	12(38.7)	12(50)	11(27.5)
Splinter hemorrhages		12(8)	7(29.17)	3(6.12)	2(6.45)	4(16.67)	2(5)
Beau’s lines		19(12.67)	5(20.83)	9(18.36)	4(12.90)	2(8.33)	
Onycholysis		4(2.67)		2(4.08)			
HHN		10(6.67)				10(41.67)	
Terry’s nail		10(6.67)			10(32.25)		
Muerchke’s line		2(1.33)				2(8.33)	
Longitudinal melanonychia		23(15.33)	5(20.83)	9(18.36)	3(9.67)	4(16.67)	4(10)
Ragged cuticle		11(7.33)	2(8.33)	4(8.16)	2(6.45)	2(8.33)	6(15)

Out of 24 cases with renal involvement, commonest nail change was found to be pallor of the nail plate 16(66.7%) followed by longitudinal ridging in 12(50%), half and half nail in 10(41.67%), obliterated lunula in 7(29.2%), brittle nail in 6(25%), clubbing in 5(20.8%) and splinter hemorrhage and longitudinal melanonychia each in 4(16.67%). 1 case of each triangular lunula and red lunula were present. (Table 1)

Out of 12 patients with CRF, most common nail change was pallor of nail plate 9 (75%) followed by HHN 7 (58.3%), longitudinal ridging 6(50%) and obliterated lunula 5(41.7%). Other changes include clubbing 4(33.3%), splinter hemorrhages 3(25%) and Beau's lines and platyonychia in 1 (8.3%).

Out of 4 patients with CRF on hemodialysis, pallor of the nail plate was seen in all patients. Other signs include HHN 3(75%), longitudinal ridging, brittle nails and obliterated lunula in 2(50%). (Fig. 3)



**Fig. 3: Nail changes in patients with CRF with or without dialysis**

In our study, out of 40 cases with hematopoietic involvement, 34 (85%) was due to leukonychia. Other nail changes include platyonychia in 22 (55%), brittle nails in 13 (32.5%), longitudinal melanonychia in 11 (27.5%), koilonychia in 9(22.5%), ragged cuticle in 6 (15%) and clubbing in 5(12.5%). (Table 1)

**Discussion**

Middle age patients were more commonly seen with nail changes rather than younger or elderly patients. As the age increases, chances of nail changes are more. Males were commonly affected probably due to their habits and environmental exposure. Nail changes are common with inpatients rather than outpatients because of the chronicity of the illness.

16% of the patients who presented with nail changes as symptoms and who were diagnosed incidentally made a challenge to look for the underlying diseases. And these patients treated accordingly.

In 5% of patients, nail changes led to the diagnosis of the underlying systemic disease. This indicates the importance of nail changes in underlying systemic diseases.

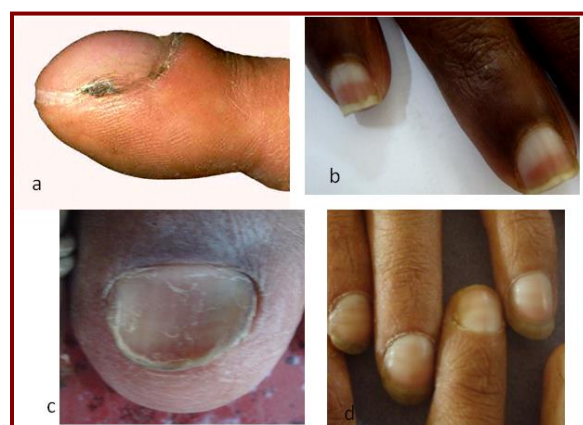Nail changes were common in patients who were symptomatic for more than 1 year than symptoms of shorter duration (days- 1 month). As the chronicity of the illness increases, the chances of the nail changes are commoner.

Association with underlying diabetes or hypertension increases the chance of nail changes.

In our study, most commonly involved systems include respiratory system followed by hematopoietic, GIT and liver, renal and cardiovascular system. Cardiopulmonary system was the common system involved along with nail changes. Because of increasing cases of nutritional anemia, there is increase in nail changes with hematological diseases, which in most cases resolved after correction of anemia.

**Nail changes associated with systemic diseases:** In our study, clubbing was the commonest nail change encountered (34.67%) followed by longitudinal ridging (29.33%), pallor of nail plate (28%), platyonychia (18.67%) and brittle nails (17.33%). In contrast to our study, Abraham Kamath et al noticed clubbing in 21.3% followed by melanonychia (17.2%) and platyonychia (14.2%).<sup>(4)</sup> As this study was conducted in patients with systemic disease in hospital basis, nail changes were less commonly noted.

**Causes of the clubbing:** Clubbing (Fig. 4a) was commonly encountered with respiratory system followed by liver and GIT, renal and cardiovascular system. In respiratory system (35 patients) chronic bronchitis was the commonest followed by pulmonary tuberculosis, COPD and interstitial lung diseases. In liver and GIT, cirrhosis with portal hypertension and alcoholic liver disease were associated with clubbing commonly followed by hepatitis and Crohn's disease. In renal system clubbing was associated with chronic renal failure (both on and not on haemodialysis).



**Fig. 4: a) clubbing of nail, b) Half and Half nail, c) Koilonychia, d) Muehrcke's lines**

**Nail changes associated with cardiovascular system:** Splinter hemorrhages and red lunula were consistently associated with cardiovascular system; this may give a clue to underlying disorder. But mostly all the nail

changes are attributed to the associated other system involvement rather than direct association.

**Nail changes associated with respiratory disease:**

Clubbing was the most common change associated with respiratory system and may give a clue to underlying disease. When there is clubbing, search for the underlying disorder should be sought if familial clubbing is excluded.

**Nail changes associated with gastrointestinal and liver disease:** Terry's nail was commonly associated with cirrhosis of liver and it is specific for the underlying liver diseases. There is no regression noted in our study after medical treatment.

**Nail changes associated with renal disease:** Out of 24 cases with renal involvement, commonest nail change was found to be pallor of the nail plate (66.7%) followed by longitudinal ridging in 50%, half and half nail in 41.67%, obliterated lunula in 29.2%, brittle nail in 25%, clubbing in 20.8% and splinter hemorrhage and longitudinal melanonychia each in 16.67%. One case of each triangular lunula and red lunula were present.

As with our study, Beni Amatya et al, found that white nail was most common followed by brown and half-and-half nail.<sup>(5)</sup>

Udaya kumar et al reported half and half nail (21%), koilonychia (18%), onychomycosis (19%), subungual hyperkeratosis (12%), onycholysis (10%), splinter hemorrhages (5%), Mees' lines (7%), Muehrcke's lines (5%) and Beau's lines (2%)<sup>(6)</sup> in contrast to our study in which pallor of the nail plate (75%) was commonest followed by HHN (58.3%).

According to P Dyachenko et al, the most common nail alterations found in patients with CRF and those undergoing HD were absence of lunula (AL) and half-and-half nails (HHN), respectively.<sup>(7)</sup> Paucer et al noted onycholysis (25%), HHN (16%) and longitudinal grooves (15%) in patients undergoing HD.<sup>(8)</sup> But our study found pallor of the nail plate was the commonest followed by HHN (75%). This might be due to the smaller sample size in our study.

Half and half nail (Fig. 4b) is the specific nail change found along with the renal system. There was no difference between the nail changes in patients who were on dialysis and not on dialysis. There was no regression noted after haemodialysis in our study.

**Nail changes associated with hematopoietic system:**

In our study, out of 40 cases with haematological involvement, 85% was due to leukonychia. Platyonychia is the commonly missed finding which is the early change of koilonychia (Fig. 4c) always should be looked for. In hematopoietic system nutritional anaemia (62.5%) is found to be the commonest followed by anaemia of chronic diseases. So the supplementation should be given to the patients with nutritional anaemia.

In our study 2 cases of idiopathic onycholysis were associated with hyperthyroidism. This correlates with the finding of Nakatsui and Lin<sup>(9)</sup> who insisted that

idiopathic onycholysis should be screened for thyroid disorders.

There was no consistent correlation with CNS involvement and the nail changes. In our study only two cases were associated with nail changes which were nonspecific (Beau's lines and longitudinal ridging).

Muehrcke's lines (Fig. 4d) were seen in two cases which were associated with hypoalbuminemia (less than 2.5 g). This correlates with Conn and Smith findings<sup>(10)</sup> that hypoalbuminemia of less than 2.2 g was associated with Muehrcke lines.

There was no regression of nail changes noted during the course of the treatment except for Beau's lines, platyonychia, koilonychia and pallor of nail plate due to anaemia.

**Conclusion**

Middle aged male patients with chronic diseases are prone for nail changes. As the chronicity of the illness increases, chances of nail changes are more. In some patients it may be incidental finding giving a clue to the underlying disorders, always look for nails for concrete evidence. Nail changes are commonly associated with respiratory system followed by haematological system. Clubbing in cardio respiratory system, half and half nail in renal system and terry's nail in liver and GIT are the specific nail changes that can lead us to the diagnosis. Prognosis is not directly related to the nail changes, commonly to the severity of the underlying disorders. Nails can serve as a window for the underlying systemic illness if properly analysed.

**Source of support:** Nil

**Conflicting Interest:** Nil

**Acknowledgement:** Nil

**References**

1. Fleckman P. Anatomy and Physiology of the nail. *Dermatol clin* 1984;3:373-381.
2. Daniel CR, Sams WM, Scher RK. Nails in systemic disease. In: *Nails: Therapy, Diagnosis, and Surgery*. 2<sup>nd</sup> ed. Amsterdam: Elsevier Health Sciences;1997:219-50.
3. Dupond AS, Magy N, Humbert P, Dupond JL. Nail manifestation of systemic diseases. *Rev Prat* 2000 Dec 15;50(20):2236-40.
4. Abraham S, Kamath N.P. Nail changes in systemic diseases: A clinical study of 435 cases. *Indian J Dermatol Venereol Leprol* 1998;64:144-145.
5. Beni Amatya, Sudha Agarwal, Tapan Dhali, Sanjib Sharma, Shyam Sunder: Pattern of skin and nail changes in chronic renal failure in Nepal: A hospital-based study. *Eur Acad Dermatol Nov* 2007;21:340-344.
6. Udayakumar P et al. cutaneous manifestations in patients with chronic renal failure on hemodialysis. *Indian J Dermatol Venereol Leprol* 2006;72(2):119-25.
7. Dyachenko P, Monselle A, Shustak A, et al. Nail disorders in patients with chronic renal failure and undergoing hemodialysis treatment: a case control study. *J Eur Acad Dermatol Venereol* 2007;21:340-344.

8. Paucer, Karen et al. Cutaneous manifestations of patients who are in intermittent chronic hemodialysis in 3 centres of metropolitan Lima. *Folia dermatol peru* 2011;22(3):141-146.
9. Nakatsui T, Lin AN. Onycholysis and thyroid disease: Report of 3 cases. *J Cutan Med Surg* 1998;3:40-42.
10. Conn RD, Smith RH. Malnutrition, myxoedema, and Muehrcke's lines. *Arch Intern Med* Dec 1965;116(6):875-8.